

Arthroscopic and Endoscopic Spinal Surgery

Arthroscopic and Endoscopic Spinal Surgery

Text and Atlas, Second Edition

Edited by

Parviz Kambin, MD

*Professor of Orthopedic Surgery
and Endowed Chair of Spinal Surgery,
Drexel University College of Medicine,
Philadelphia, PA*

HUMANA PRESS  TOTOWA, NEW JERSEY

© 2005 Humana Press Inc.
999 Riverview Drive, Suite 208
Totowa, NJ 07512

www.humanapress.com

All rights reserved. No part of this book may be reproduced, stored in a retrieval system, or transmitted in any form or by any means, electronic, mechanical, photocopying, microfilming, recording, or otherwise without written permission from the Publisher.

The content and opinions expressed in this book are the sole work of the authors and editors, who have warranted due diligence in the creation and issuance of their work. The publisher, editors, and authors are not responsible for errors or omissions or for any consequences arising from the information or opinions presented in this book and make no warranty, express or implied, with respect to its contents.

Production Editor: Tracy Catanese

Cover design by Patricia F. Cleary

Cover Illustrations: Figures 38A and 35B from Chapter 4, "Herniated Lumbar Disc and Lumbar Radiculopathy," and Figures 7A and 12B from Chapter 5, "Management of Discogenic Pain and Spinal Instability Using Minimally Invasive Surgical Techniques," by Parviz Kambin.

For additional copies, pricing for bulk purchases, and/or information about other Humana titles, contact Humana at the above address or at any of the following numbers: Tel.: 973-256-1699; Fax: 973-256-8341; E-mail: orders@humanapr.com or visit our website: <http://humanapress.com>

This publication is printed on acid-free paper. ∞
ANSI Z39.48-1984 (American National Standards Institute) Permanence of Paper for Printed Library Materials.

Photocopy Authorization Policy:

Authorization to photocopy items for internal or personal use, or the internal or personal use of specific clients, is granted by Humana Press Inc., provided that the base fee of US \$30.00 per copy is paid directly to the Copyright Clearance Center at 222 Rosewood Drive, Danvers, MA 01923. For those organizations that have been granted a photocopy license from the CCC, a separate system of payment has been arranged and is acceptable to Humana Press Inc. The fee code for users of the Transactional Reporting Service is: [1-58829-522-2/05 \$30.00].

Printed in the United States of America. 10 9 8 7 6 5 4 3 2 1

e-ISBN: 1-59259-904-4

Library of Congress Cataloging-in-Publication Data

Arthroscopic and endoscopic spinal surgery : text and atlas / edited by Parviz Kambin.
p. ; cm.

Includes bibliographical references and index.

ISBN 1-58829-522-2 (alk. paper)

1. Spine--Endoscopic surgery. 2. Spine--Endoscopic surgery--Atlases.

[DNLM: 1. Spine--surgery--Atlases. 2. Arthroscopy--methods--Atlases. 3. Endoscopy--methods--Atlases. 4. Surgical Procedures, Minimally Invasive--methods--Atlases. WE 17 A7875 2005] I. Kambin, Parviz.

RD533.A785 2005

617.5'60597--dc22

2004026633

Dedication

The authors wish to dedicate this text and atlas to their families, colleagues, and students of minimally invasive spinal surgery.

Preface

The term “minimally invasive spinal surgery” was coined in early 1990 following publication of the first edition of this text entitled *Arthroscopic Microdiscectomy: Minimal Intervention in Spinal Surgery*, and subsequent establishment of the International Society for Minimal Intervention in Spinal Surgery (ISMISS) under the auspices of the International Society of Orthopaedic Surgery and Traumatology (SICOT) in April 1990.

The orthopedic and neurological surgeons who participated in lectures and hands-on workshops both in Philadelphia and abroad have witnessed the evolution of minimally invasive spinal surgery from blind nucleotomy to endoscopic fragmentectomy, decompression of lateral recess stenosis, foraminoplasty, and spinal stabilization.

In *Arthroscopic and Endoscopic Spinal Surgery: Text and Atlas, Second Edition*, experts describe and illustrate various techniques and approaches that are currently used in this field. In addition, the ongoing research for the betterment of spine care via minimally invasive approaches is briefly reviewed.

I would like to express my sincere appreciation to so many of my colleagues who supported my efforts in the field of minimally invasive spinal surgery throughout the years. Many of them participated in our teaching symposiums and have provided valuable contributions to this text.

Parviz Kambin, MD

Contents

DEDICATION	V
PREFACE	VII
CONTRIBUTORS	XI
COLOR PLATES	XIII
COMPANION DVD	XV
1 History of Surgical Management of Herniated Lumbar Discs From Cauterization to Arthroscopic and Endoscopic Spine Surgery <i>Parviz Kambin</i>	1
2 Arthroscopic and Endoscopic Anatomy of the Lumbar Spine <i>Parviz Kambin</i>	29
3 Instruments and Surgical Approaches for Minimally Invasive Spinal Surgery Via Posterolateral Access <i>Parviz Kambin</i>	49
4 Herniated Lumbar Disc and Lumbar Radiculopathy <i>Parviz Kambin</i>	61
5 Management of Discogenic Pain and Spinal Instability Using Minimally Invasive Surgical Techniques <i>Parviz Kambin</i>	119
6 Lateral Recess Stenosis of Lumbar Spine Foraminoplasty <i>Parviz Kambin</i>	145
7 Role of Epidural and Radicular Veins in Chronic Back Pain and Radiculopathy <i>Wesley W. Parke</i>	151
8 Diagnostic and Therapeutic Percutaneous Transpedicular Approaches to the Spine <i>Alexander G. Hadjipavlou, George M. Kontakis, Ioannis Gaitanis and Michael Tzermiadianos</i>	167
9 Selective Endoscopic Discectomy™: <i>Twelve Years of Experience</i> <i>Anthony T. Yeung</i>	205
10 Minimally Invasive Posterior Fusion and Internal Fixation With the Atavi® System <i>Richard D. Guyer and Terry P. Corbin</i>	227
11 Vertebral Augmentation for Osteoporotic Compression Fractures <i>Daisuke Togawa and Isador H. Lieberman</i>	239

12	Principles of Transthoracic, Transperitoneal, and Retroperitoneal Endoscopic Techniques in the Thoracic and Lumbar Spine <i>Geoffrey M. McCullen and Hansen A. Yuan</i>	251
13	Use of Laser in Minimally Invasive Spinal Surgery and Pain Management <i>John C. Chiu and Martin H. Savitz</i>	259
14	Minimally Invasive Techniques in Pain Management <i>James Reynolds and Garrett Kine</i>	271
15	Experience With Minimally Invasive Nucleus Replacement <i>Michele Marcolongo, Parviz Kambin, Anthony Lowman and Andrew Karduna</i>	295
16	Interspinous Process Implant for Treatment of Lateral and Central Spinal Stenosis: <i>Operative Technique and Results</i> <i>Douglas Wardlaw</i>	315
17	Frameless Stereotactic Imaging Techniques in Minimally Invasive Spine Surgery <i>Kern Singh, Laurence N. Fitzhenry, and Alexander R. Vaccaro</i>	335
18	The Rise and Fall of Chemonucleolysis <i>James W. Simmons, Jr. and Robert D. Fraser</i>	351
19	Lumbar Microendoscopic Discectomy <i>Trent L. Tredway and Richard G. Fessler</i>	359
	INDEX	377

Contributors

JOHN C. CHIU, DSc, MD • *Director, Neurospine Surgery Department, California Spine Institute Medical Center Inc., Park, CA*

TERRY P. CORBIN, BS • *Clinical Outcomes Research Center, University of Minnesota, Maple Grove, MN*

RICHARD G. FESSLER, MD, PhD • *Professor and Chief, Section of Neurosurgery, University of Chicago, Chicago, IL*

LAURENCE N. FITZHENRY, MD • *Department of Orthopedic Surgery, Thomas Jefferson University and the Rothman Institute, Philadelphia, PA*

ROBERT D. FRASER, MD • *Alamo Bone and Joint Clinic, San Antonio, TX*

IOANNIS GAITANIS • *Orthopaedic Surgeon, University of Crete, Crete, Greece*

RICHARD D. GUYER, MD • *Associate Clinical Professor, Department of Orthopaedic Surgery, UT Southwestern Medical School, Dallas, and Research Founder and Chairman of the Board, Texas Back Institute, Plano, TX*

ALEXANDER G. HADJIPAVLOU, MD • *Professor of Orthopaedics-Traumatology, University of Crete, Crete, Greece*

PARVIZ KAMBIN, MD • *Professor of Orthopaedic Surgery, Drexel University College of Medicine, Philadelphia, PA*

ANDREW KARDUNA, PhD • *Department of Physical Therapy, University of Oregon, Eugene, OR*

GARRETT KINE, MD • *Anesthesiologist, SpineCare Medical Group, Daly City, CA*

GEORGE M. KONTAKIS, MD • *Assistant Professor of Orthopaedics-Traumatology, University of Crete, Crete, Greece*

ISADOR H. LIEBERMAN, MD, MBA, FRCS (C) • *Center Director and Director of Minimally Invasive Surgery, Center for Advanced Skills Training; Department of Orthopaedic Surgery and Spine Institute, The Cleveland Clinic Foundation, Cleveland, OH*

ANTHONY LOWMAN, PhD • *Assistant Professor, Department of Chemical Engineering, Drexel University, Philadelphia, PA*

MICHELE MARCOLONGO, PhD • *Assistant Professor, Department of Materials Science and Engineering, College of Engineering, Drexel University, Philadelphia, PA*

GEOFFREY M. McCULLEN, MD • *Orthopedic Surgeon, Neurological and Spinal Surgery, LLC, Lincoln, NE*

WESLEY W. PARKE, PhD • *Professor and Chair Emeritus, Department of Anatomy, University of South Dakota School of Medicine, Vermillion, SD*

JAMES REYNOLDS, MD • *Orthopedic Surgeon, SpineCare Medical Group, Daly City, CA*

MARTIN H. SAVITZ, MD, FACS, FICS • *Executive Director, American Academy of Minimally Invasive Spinal Medicine and Surgery, and Adjunct Professor of Bioethics, MCP-Hahnemann School of Medicine, Philadelphia, PA*

- JAMES W. SIMMONS, JR., MD • *Alamo Bone and Joint Clinic, San Antonio, TX*
- KERN SINGH, MD • *Department of Orthopedic Surgery, Rush-Presbyterian-St. Luke's Medical Center, Chicago, IL*
- DAISUKE TOGAWA, MD, PhD • *Department of Orthopaedic Surgery and Spine Institute, The Cleveland Clinic Foundation, Cleveland, OH*
- TRENT L. TREDWAY, MD • *Assistant Professor, Department of Neurosurgery, University of Washington, Seattle, WA*
- MICHAEL TZERMIADIANOS • *Orthopedic Surgeon, University of Crete, Crete, Greece*
- ALEXANDER R. VACCARO, MD • *Professor of Orthopedic Surgery, Thomas Jefferson University and the Rothman Institute, Philadelphia, PA*
- DOUGLAS WARDLAW, ChM, FRCS(Ed) • *Consultant, and Orthopaedic and Spinal Surgeon, Grampion University Hospitals Trust—Woodend Hospital, Aberdeen, Scotland*
- ANTHONY T. YEUNG, MD • *Voluntary Associate Clinical Professor, Department of Orthopaedics, University of California San Diego School of Medicine, San Diego, CA, and Arizona Institute for Minimally Invasive Spine Care, Phoenix, AZ*
- HANSEN A. YUAN, MD • *Professor of Orthopedic and Neurological Surgery, State University of New York Upstate Medical University, Syracuse, NY*

Color plates 1–39 appear in an insert following p. 144.

Plate 1	Fig. 7 from Chapter 1; for full caption <i>see</i> p. 10.
Plate 2	Fig. 16B from Chapter 1; for full caption <i>see</i> p. 17.
Plate 3	Fig. 4A from Chapter 2; for full caption <i>see</i> p. 32.
Plate 4	Fig. 5A from Chapter 2; for full caption <i>see</i> p. 33.
Plate 5	Fig. 6A,B from Chapter 2; for full caption <i>see</i> p. 34.
Plate 6	Fig. 7 from Chapter 2; for full caption <i>see</i> p. 35.
Plate 7	Fig. 8 from Chapter 2; for full caption <i>see</i> p. 35.
Plate 8	Fig. 9C from Chapter 2; for full caption <i>see</i> p. 37.
Plate 9	Fig. 10 from Chapter 2; for full caption <i>see</i> p. 38.
Plate 10	Fig. 12A from Chapter 2; for full caption <i>see</i> p. 39.
Plate 11	Fig. 13A from Chapter 2; for full caption <i>see</i> p. 40.
Plate 12	Fig. 14A from Chapter 2; for full caption <i>see</i> p. 41.
Plate 13	Fig. 15A from Chapter 2; for full caption <i>see</i> p. 42.
Plate 14	Fig. 16 from Chapter 2; for full caption <i>see</i> p. 43.
Plate 15	Fig. 18A,B from Chapter 2; for full caption <i>see</i> p. 44.
Plate 16	Fig. 12A,B from Chapter 3; for full caption <i>see</i> p. 57.
Plate 17	Fig. 5A,B from Chapter 4; for full caption <i>see</i> p. 67.
Plate 18	Fig. 22 from Chapter 4; for full caption <i>see</i> p. 91.
Plate 19	Fig. 23A from Chapter 4; for full caption <i>see</i> p. 92.
Plate 20	Fig. 27B,C from Chapter 4; for full caption <i>see</i> p. 97.
Plate 21	Fig. 28E,F from Chapter 4; for full caption <i>see</i> p. 99.
Plate 22	Fig. 29A,B from Chapter 4; for full caption <i>see</i> p. 102.
Plate 23	Fig. 30 from Chapter 4; for full caption <i>see</i> p. 103.
Plate 24	Fig. 31A from Chapter 4; for full caption <i>see</i> p. 104.
Plate 25	Fig. 33A from Chapter 4; for full caption <i>see</i> p. 106.
Plate 26	Fig. 35A from Chapter 4; for full caption <i>see</i> p. 110.
Plate 27	Fig. 36 from Chapter 4; for full caption <i>see</i> p. 111.
Plate 28	Fig. 37A–C from Chapter 4; for full caption <i>see</i> p. 112.
Plate 29	Fig. 38A from Chapter 4; for full caption <i>see</i> p. 114.
Plate 30	Fig. 39A from Chapter 4; for full caption <i>see</i> p. 115.
Plate 31	Fig. 1B from Chapter 5; for full caption <i>see</i> p. 120.
Plate 32	Fig. 7C,D from Chapter 5; for full caption <i>see</i> p. 129.
Plate 33	Fig. 3A from Chapter 6; for full caption <i>see</i> p. 148.
Plate 34	Fig. 7B from Chapter 9; for full caption <i>see</i> p. 211.
Plate 35	Fig. 8 from Chapter 9; for full caption <i>see</i> p. 212.
Plate 36	Fig. 12 from Chapter 9; for full caption <i>see</i> p. 215.
Plate 37	Fig. 13 from Chapter 9; for full caption <i>see</i> p. 215.
Plate 38	Fig. 17 from Chapter 9; for full caption <i>see</i> p. 219.
Plate 39	Fig. 5 from Chapter 13; for full caption <i>see</i> p. 264.

Companion DVD

The companion DVD to this volume contains three video segments from the editor. The DVD can be played in any "set-top" DVD player attached to an NTSC standard definition television set. The DVD may also be viewed using any computer with a DVD drive and DVD compatible playback software such as Apple DVD Player, Windows Media Player 8 or higher (Win XP), PowerDVD, or WinDVD.

History of Surgical Management of Herniated Lumbar Discs From Cauterization to Arthroscopic and Endoscopic Spinal Surgery

Parviz Kambin, M D

INTRODUCTION

A review of the history of the surgical management of herniated lumbar discs as a common cause of sciatica is not complete without acknowledging the efforts of many investigators and researchers who have contributed to the understanding of the anatomy and origin of the sciatic nerve and lumbar intervertebral discs. In addition, the efforts of scientists and clinicians who have participated in developing the surgical management of disc herniation in the last seven decades should be recognized.

MANAGEMENT OF BACK AND LEG PAIN IN ANCIENT MEDICINE

Low back and sciatic pain has been one of the most common and disabling spinal disorders recorded in medical history. The role of the spinal canal's contents in extremity function is well demonstrated in the Dying Lioness (Fig. 1), a ca. 650 BC. Assyrian artwork.

In the writings of Hippocrates (460–370 BC) one can find references to the anatomy of the brain, brachial plexus, and sciatic nerve. In animal dissections it appears that he had difficulty in differentiating tendons from peripheral nerves. However, he attributed the development of paresthesia, weakness of the limbs, and fecal and urinary retention to spinal cord compression (1).

On the basis of his animal and human dissections, Aristotle (384–322 BC) described vertebrate anatomy (2). Erasistratus (250 BC) distinguished between the role of motor and sensory nerve fibers in his findings from cadaver dissections (3).

Avicenna (980–1037 AD), a Persian physician and philosopher who was born in Bokhara, also wrote extensively on human anatomy and the peripheral nerves. However, his writings make no clear reference to sciatic pain. His text *Canon of Medicine* formed the cornerstone of medical practice for ensuing centuries. Avicenna condemned the reliance on mysticism and astrology in medicine (4). His writings were translated into Latin and included in the medical curriculum of European universities. Avicenna's principal method of treating spinal disorders by traction and manipulation remains an accepted practice in many centers at present (Fig. 2), (5,6). A calligraphy (Fig.3), dating




Fig. 1. The dying lioness, ca 650 BC. (Reprinted with permission from refs. 1 and 42.)

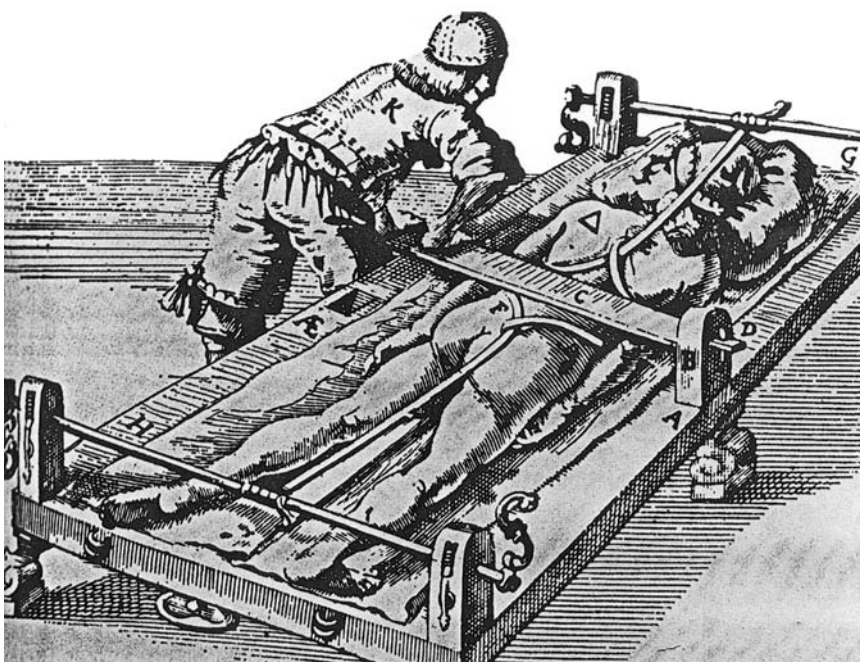


Fig. 2. Avicenna's a "Method of Treating Spinal Disorders by Traction and Manipulation." (Reprinted with permission from ref. 5.)

to 1400 AD demonstrates the depth of curiosity of the times, and the information that was gathered from cadaver dissections. Their illustrations show the presence of 6 cervical, 12 thoracic, and 5 lumbar segments. The origins of the brachial plexus from the cervical segments, the intercostal nerves from the thoracic nerves, and the sciatic nerve

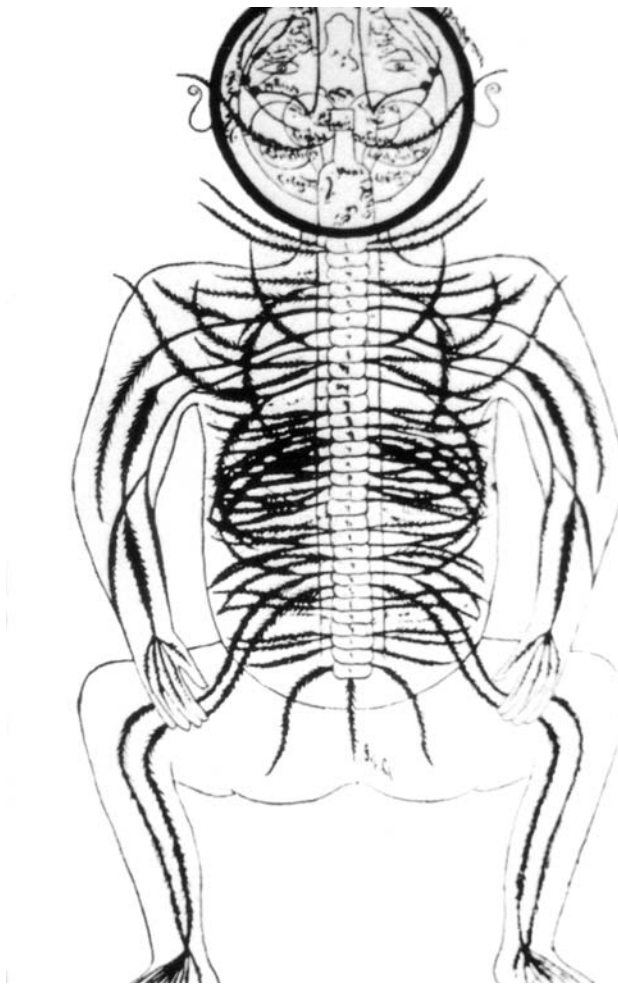


Fig. 3. Persian miniature from about 1400 AD. (Reprinted with permission refs. 1 and 42.)

from the lumbar segments are described. In addition, the two divisions of the sciatic nerve as it extends into the lower extremities are shown.

In the ancient literature there is no reference to surgical management of sciatic pain. However, the use of traction, local cauterization (Fig. 4), cupping, bloodletting, and opioids was common in Arabic, Persian, and Islamic medicine and subsequently in European medicine. Acupuncture has been practiced in Chinese medicine for centuries.

RECOGNITION OF SCIATICA AND ITS ASSOCIATED SYMPTOMATOLOGY

Domenico Cotugno (Fig. 5), an eighteenth century Italian physician (7), introduced the term sciatica into the medical vocabulary. Without having knowledge of the common etiology of this disabling spinal disorder, he described some of the signs and symptoms commonly seen in association with sciatic pain. Subsequently, Cotugno's disease as an entity gained acceptance in European medicine. Associated clinical findings of sciatica

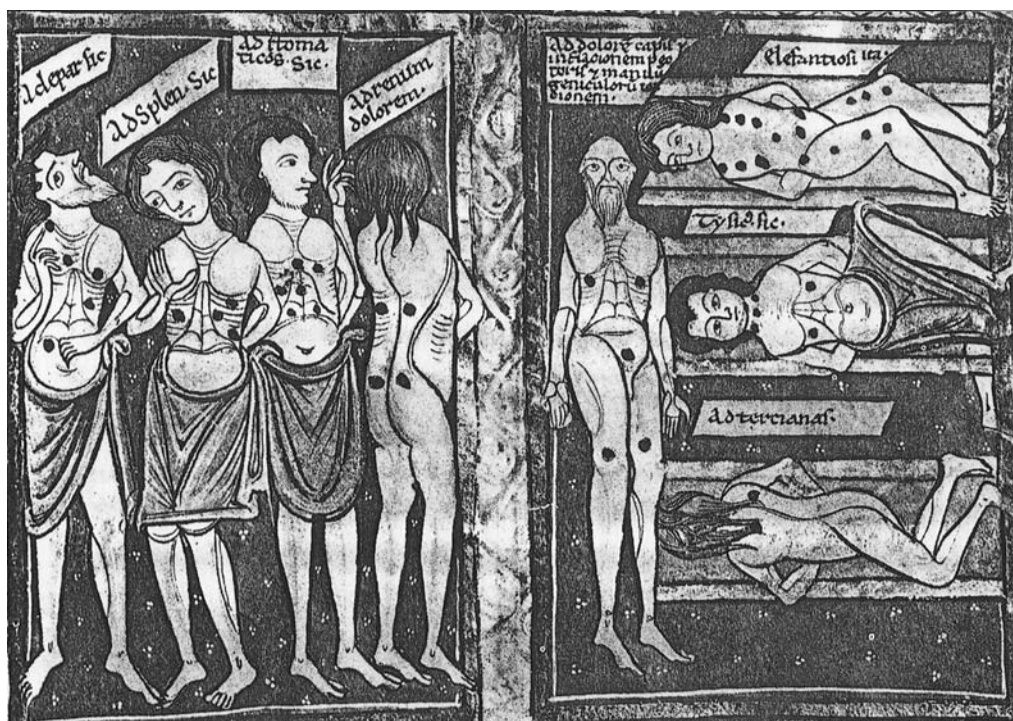


Fig. 4. Cauterization points for spine and other disorders. (Reprinted with permission from ref. 5.)

were further detailed and documented by the writings of Putti (8), Valleix (9), Lasègue (10), and Brissard (11) in later years.

IDENTIFICATION OF ANATOMICAL AND PATHOLOGICAL CONDITIONS OF THE INTERVERTEBRAL DISC

In the late nineteenth and early twentieth centuries, many investigators contributed to the understanding of intervertebral disc anatomy. In 1857, Virchow (12) published autopsy findings on the intervertebral disc in a patient who was injured and later expired. In 1868, von Luschka (13) described posterior disc protrusion in cadavers found in the course of routine autopsy procedures. Kocher (14) referred to his findings on intervertebral discs at L1-L2 in a patient who had a traumatic injury. Schmorl's (15) contribution to anatomical structures of the intervertebral disc also deserves recognition. In 1926, he reported on autopsy findings on 5000 intervertebral discs, 15 of which showed evidence of disc protrusion into the spinal canal. However, despite this significant anatomical finding, he had not yet established the causal connection between disc herniation and sciatic pain.

HISTORY OF SURGICAL MANAGEMENT OF SCIATICA

In the early twentieth century, laminectomy was being performed for the treatment of a variety of spinal disorders. In 1911, Goldthwait (16) described the management of a 39-yr-old male who underwent spinal manipulation, and then he developed paralysis in



Fig. 5. Potrait of Domenico Cotugno.

the lower extremities. His conservative management included plaster immobilization and rest. The patient failed to show improvement, and 6 wk later he underwent extensive decompressive laminectomy, extending from L1 to S2. The patient responded to the operative procedure and showed improvement. Goldthwait (16) attributed the patient's neurological deficit to detachment and protrusion of the fibrotic annulus into the spinal canal, slippage of the articular processes, and abnormality of the transverse process of the lumbar segment.

In 1913, Dr. Elsberg of the New York Neurological Institute and Mt. Sinai Hospital, reported on his findings on 60 consecutive laminectomies. However, he did not believe disc pathology was responsible for the presenting symptomatology in any of the patients described (17). In 1928, in a paper entitled a "Extradural Spinal Tumors, Primary, Seconary, Metastasis," Dr. Elsberg attributed compression of the cauda equina to the presence of cartilaginous tumors (chondromas) (18).

In 1927, Putti (8) reported on one of his patients who underwent laminectomy and facetectomy to decompress the L5 and S1 nerve roots and relieve sciatic pain. He further elaborated on the contribution of Sicard, who performed laminectomy from L3 to the sacrum to provide relief from sciatic pain.

Other investigators, including Stookey in 1928 (19) and Bucy in 1930 (20), also reported on the removal of chondroma-type tumors from the intervertebral discs that were causing pressure on the neural structures. Alajouanine, a neurologist residing in Paris, reported on two patients who underwent laminectomy and discectomy in 1928 (21,22). A brief translation of his article is as follows:

It is a very specific type of radiculomedullary compression that we call "a fibrocartilaginous nodule of the posterior aspect of the intervertebral discs." This compression is manifested by radicular signs, more rarely medullary, most often unilateral. Surgical ablation, although sometimes laborious, like all premedullary tumors, usually results in the rapid regression of compressive disorders. Their first presentation was made in 1928 to the Surgical Society of a unilateral cauda equina syndrome due to a curious formation related to an intervertebral disc (ref. 2: Bull et Mem de la Soc nat de chir 12 Oct 1928, 54: 1452). Now we have seen a second case, absolutely identical to the first.

Case 1. Male, 37 years old, complained of left lumbosacral pain with root, sensory and sphincter problems for 4 years. The flow of Lipiodol was blocked below L5-S1. Ablation of fibrocartilaginous nodule from L5-S1 intervertebral disc. Rapid and complete cure.

Case 2. Female, 20 years old, had a 3-year history of pain in the left leg and while walking. There was foot drop, absence of achilles and medial plantar reflexes. Anesthesia of L4-L5 and all sacral roots. Positive Lipiodol test at L3-L4. On July 18, 1929, disc protrusion, transdural approach, removal of fibrocartilaginous nodule in comparison to the first case. Partial recovery of the foot drop but not the ankle reflex. Notes probable compression of nerve roots by rongeurs in the course of laminectomy.

These nodules are neither tumors, chondromas nor fibrochondromas and are distinctly different from chordomas. Basically, they are always related to the intervertebral disc. We have shown that these curious formations should be considered to result from herniation of the central pulp of the disc across the latter, the hernia produced either by trauma or by pathological changes in the disc; in addition, the effects of these two causes can be combined.

The use of Lipiodol is indispensable, not only with radiography but also with fluoroscopy. The prognosis depends upon surgical treatment which is midline through the dura. If the protrusion is very lateral, the dura mater should be incised laterally. There is a problem with retraction of the spinal cord in the neck and thorax, particularly evident when the nodule is calcified and embedded in the cord. Such nodules should be suspected in refractory lumbalgia and sciatica.

In 1931, Crouzon et al. (23) gave credit to the contribution of Alajouanine and further detailed and described the clinical outcome of patients who underwent laminectomy and discectomy. A translation of their publication is as follows.

This is a new example of a fibrocartilaginous nodule on the posterior aspect of the intervertebral disc, producing a very specific type of root compression that one of us, with Alajouanine, has called attention to in a recent report. [Alajouanine T, Petit-Dutaillis D. Le nodule fibrocartilagineux de la face posterieure des disques intervertebraux. Presse Medicale nos. 98 and 102 of 6 and 20 September 1930]. The favorable results obtained by surgical intervention make it possible to emphasize once more its clinical and therapeutic value in such a disorder.

[There follows a case history, summarized here.]

A brickmaker, 44 years old, was hospitalized by Dr. Crouzon for refractory sciatica that had kept him out of all work for 6 months. There was no special precipitating factor, but there was a history of an acute injury to the lumbar region 7 years earlier when he fell 4 meters onto his back and kidneys. After severe pain immobilized him for some days, he

was able to go back to work, but with intermittent episodes of "lumbago" making him rest for 3 to 4 days. Only after 7 years did he begin to have (In June 1930) pains in the left leg that became increasingly severe and frequent. Examination on 20 February 1931 showed areas of pain in the lumbar region, calf and left heel. These were aggravated by the slightest movement, cough or strain. When he stood, his weight was placed on the intact right extremity. There was an antalgic spasm of the lumbar muscles, but hypotonia of the quadriceps and calf on the left side. His body was held forward when he walked with obvious pain. The spine was held flexed forward and to one side. There was some atrophy of the left thigh and calf, the latter measuring 3 cm less than the healthy calf. There was a slight decrease in strength of flexion and extension of the foot on the left side. Knee reflexes were equal, but the achilles and medial plantar reflexes were absent on the left. Sensory exam showed sharp pain on pressure all along the left sciatic nerve and sharp pain on Lasègue's maneuver.

There was pain on pressure and percussion over the spinous processes of L4 and L5. The sensory exam of the plantar aspect of the foot was consistent with anesthesia for all modalities on the plantar aspect of the foot and posterior aspect of the left calf, extending 5 cm onto the posterior of the thigh. There was also a band of sensory loss on the lateral aspect of the foot and adjacent leg, ascribed to L5, S1 and S2. There was some sphincter dysfunction with pain on defecation and difficulty in urination. Lumbar puncture on February 25, 1931 showed normal fluid and normal pressure, slight dissociation between albumin and cells (40 g albumin and 2 cells). Wasserman tests of blood and CSF were negative. X-rays showed some narrowing at L4-L5. A Lipiodol study showed temporary blockage at L4-L5 under the fluoroscope, but by the time the patient reached the radiography room, the oil had all fallen to the bottom. The temporary blockage was pronounced enough to induce Dr. Alajouanine to operate on the patient on 7 March 1931. Laminectomy of L3-L5 showed ossification of the ligamentum flavum at L4-L5; the dura was indented, and the ligament was removed. The dura was opened to show displacement of the nerve roots by a whitish nodule compressing the left L5 root. The root was compressed to a thread at the level of the intervertebral foramen, as if it had been partially destroyed by stretching. In order to free it without further damage, the dura was cut transversely. This made it possible to displace the root of L5 to the left and the rest of the roots to the right. The dura was incised anteriorly over the nodule, and a specially designed spatula was used to hold the root while the fibrocartilaginous nodule was removed. Because of the transverse cut in the dura, no attempt was made to suture it, and the wound was closed in layers with catgut and without drainage.

The postoperative course was uneventful; sutures were removed on Day 9. The outcome of surgery was very good and recovery was rapid. The day after surgery the patient said the left leg no longer hurt, and re-examination showed a return of sensation in the areas of L5, S1 and S2. He could now feel the bedsheets on his foot. Fifteen days after surgery he had no complaints and could get out of bed; 25 days after surgery he stood straight and walked normally without pain or fatigue.

Examination on April 25, 7 weeks after surgery, showed normal posture, with weight equally distributed on the two legs. Flexion and extension of the left foot were normal. Mild hypotonia persisted in the left thigh as did slight atrophy of the calf and thigh on the left. The achilles and medial plantar reflexes were still absent. There was no pain on pressure over the course of the left sciatic nerve. There was no pain on straight-leg raising. Objective examination of sensation showed a slight decrease in tactile sensation on the lateral border of the left foot. The sphincter problems had resolved, and the patient's general health was excellent.

Histological study of the specimen by Dr. I. Bertrand showed fibrocartilaginous tissue with abundant interstitial stroma containing amorphous tissue with some collagen bundles. There were only a few cells, but those seen resembled cartilage cells. An examination for Virchow's physaliferous cells was negative. There were few vessels, and in some places the absence of staining indicated some necrosis.

This case should be added to similar cases published in France by Alajouanine and Petit-Dutaillis, by Robineau and, in the foreign press, by Adson, Stookey, then Bucy and P. Bailey, and, very recently, by Katzenborn, making a total of 23 operated cases. The new case reported appears to prove that this is not a very rare condition and that the numbers will soon increase now that attention has been directed to these facts.

In view of this new case, it seems appropriate to emphasize certain points: the role of trauma is beyond doubt, even though in this case it may be dismissed, for in this case the injury occurred 7 years previously. Emphasis is placed on the occasionally long latent period before symptoms become manifest. Some temporary lumbar symptoms of an apparently common type may occur in this period, as if the lesion, only produced by the initial trauma, gradually becomes more pronounced, undoubtedly affected by repeated strains in those whose occupations are strenuous. There is a notable incidence of unilateral symptoms. The lumbar region is not the only site of pathological disc changes; the first cases dealt with those in the neck. Although Stookey initially thought these fibrocartilaginous lesions were exclusively cervical, it is clear that they may occur elsewhere, although they do appear to be rare in the thoracic region.

In addition to clinical signs and symptoms, compression is also manifested by a dissociation between albumin and cells and by a blockage of Lipiodol. The blockage of the oil may be quite temporary and be seen only on fluoroscopy. For this reason the authors emphasize the need for this diagnostic procedure as well as radiography. The absence of the disc in radiograms was similar to that in long-standing Pott's disease. However, it should be noted that there is no sign of herniation into the vertebral bodies. It seems likely that in compression phenomena of traumatic origin the compression, or even absence, of the disc might promote the development of fibrocartilaginous nodule formation.

The histological study also shows that these nodules should not be considered to be tumors (neoplasms) as has been thought to be the case by those authors who called them fibrochondromas, ecchondromas or even chondromas of the disc. These structures are an integral part of the intervertebral disc with no neoplastic characteristics, but should be considered protrusions of the disc or of the nucleus pulposus across a break in the posterior part of the intervertebral disc into the spinal canal. This interpretation (Schmorl, Andrae) seems the only logical one.

It is more painstaking to surgically remove these pathological structures than other intraspinal tumors. In the region of the cauda equina the compressed roots must be freed very gently and very slowly. Even if the size of the nodule is small, its consistency is very hard and it exerts a very firm compression. In our case the left root at L5 had already been heavily compressed and stretched. Sometimes the root may be in contact with the lamina, and care must be taken in removing the lamina to avoid injuring the root.

Dandy (24) independently reported on the removal of a detached fragment of cartilaginous tissue from the intervertebral disc for treatment of sciatic pain.

Mixter and Barr are credited for establishing a clear causal connection between the herniated disc and sciatica. They provided a detailed description of disc herniation and popularized laminectomy and discectomy for surgical management of herniated lumbar discs (25).

Between the 1930s and 1950s, orthopedic and neurological surgeons followed the traditional teaching of Mixter and Barr that consisted of wide exposure, bilateral dissection of the paraspinal muscles, laminectomy, and extensive epidural hemostasis and coagulation in the course of extraction of herniated disc fragments.

The traditional surgery described by Mixter and Barr was later modified and became less invasive with the introduction of the microscope to the surgical field by Yasargil, a Turkish surgeon, in 1972 (26,27). This concept was further advanced by other investigators (28).

EMERGENCE OF THE MINIMALISTS' CONCEPT

Annular Fenestration and Reduction of Hydrostatic Pressure
in the Intervertebral Disc

The earliest recorded departure from the concept of traditional laminectomy and discectomy in the treatment of a herniated lumbar disc is found in an article published by Hult (29) in 1950, in which he advocated an anterior retroperitoneal annular fenestration for decompression of herniated lumbar discs. The relationship between hydrostatic pressure of the intervertebral disc and the size of the annular bulge and protrusion has been a subject of interest to many investigators. Virgen (30) demonstrated that the height of the intervertebral disc is decreased and the annulus bulged outward when intervertebral discs were subjected to axial loading. Brown et al. (31) showed that the annular bulge was increased on the side on which the spine was flexed and the annulus was flattened on the opposite side. Nachemson (32,33) also demonstrated bulging of the annulus associated with increased intradiscal pressure under load, particularly in the sitting position and with forward bending and lifting. Kambin and colleagues reported on their *in vivo* evaluation of hydrostatic pressure in the intervertebral disc prior to and following annular fenestration via a 4.9-mm-outer diameter (od) trephine and partial nuclear resection. A considerable reduction of intradiscal pressure was observed when patients were instructed to extend and rotate the trunk following annular venting (34,35). However, long-term patency of the annular fenestration remains highly questionable. Although Sakamoto et al. (36) showed that the reduction of intradiscal hydrostatic pressure may be maintained up to 21 mo postoperatively, Hampton et al. (37) reported healing and closure of the surgically created defect in the annulus between 3 and 12 wk after surgery. This phenomenon was also confirmed in the my own experience when a repeated surgery was required a few months following the original percutaneous arthroscopic discectomy. It was found that the original site of annular fenestration was closed with scar tissue.

Concept of Nuclear Mass Reduction

Lyman Smith should be recognized as a champion of the minimally invasive movement (38). Learning from the experience of Lewis Thomas in rabbits (39), he introduced the concept of dissolving the nucleus pulposus by intradiscal injection of chymopapain. The simplicity of the procedure and the fact that the operative technique did not violate the content of the spinal canal attracted the attention of many orthopaedic and neurological surgeons, both in the United States and abroad. This was followed by many presentations, hands-on seminars, and publications in the ensuing years.

Encouraged by previously reported satisfactory outcomes of chemonucleolysis, in the early 1970s, following institutional approval, Kambin (Fig. 6) initiated a feasibility study on the efficacy of mechanical nuclear debulking for the treatment of herniated lumbar discs via a Craig cannula inserted into the intervertebral disc dorsolaterally (40,41).

Clinical research conducted by my colleagues and I in the ensuing years was directed toward establishing the effect of central nucleotomy on the size of the bulge or herniation. In 1973, at The Graduate Hospital of Philadelphia, we combined the central nucleotomy via a Craig biopsy cannula with laminectomy in patients who demonstrated signs, symptoms, and imaging evidence of disc herniation (Fig. 7) (35). In 1973, a 60-year-old male with myelographic and clinical evidence of disc herniation at L3-L4 and

DOCTORS HOSPITAL
1700 VINE STREET, PHILADELPHIA, PA. 19103

OFFICERS
William T. Lemmon, M. D.
President
Marcel S. Sussman, M. D.
Vice-President
Thomas B. Mervine, M. D.
Secretary
J. G. Manley, M. D.
Treasurer

MEMBERS OF BOARD OF GOVERNORS
John W. Bransfield, M. D.
B. H. K. Miller, M. D.
J. Wallace Davis, M. D.
William DeCherney, M. D.
William A. Tomasco, M. D.
Armando Goracci, M. D.
Marvin Krane, M. D.
Cyril L. Velkoff, M. D.
Lula Vera, M. D.

ADMINISTRATOR
Estelle F. Hoag

April 15, 1969

Parviz Kambin, M.D.
1930 Chestnut Street
Philadelphia, Pennsylvania 19103

Dear Dr. Kambin:

Per your request, please be advised that you may use standard Craig instrumentation for decompression of intervertebral disc on patients who give proper consent for this procedure.

Sincerely,

Wm T. Lemmon

William T. Lemmon, M.D.
President
Board of Governors

WTL:mpw

Fig. 6. Authorization by Board of Governors of Doctors Hospital permitting use of Craig cannula for nucleotomy in management of disc herniation.

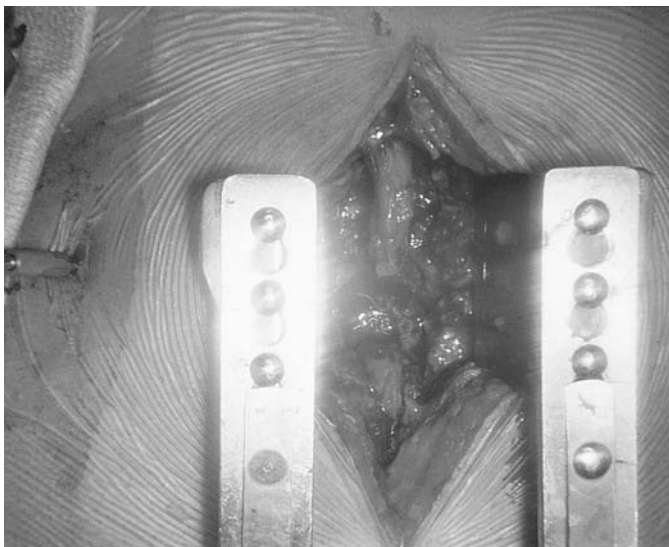


Fig. 7. Intraoperative photo demonstrating effect of nucleotomy via a Craig cannula on contour and geometry of herniated disc, which was visualized through open laminotomy.




Fig. 8. Kambin cannulated spinal obturators. Blunt-end cannulated obturators for precise positioning of the instruments as shown.

L4-L5 underwent open laminectomy at both levels. The larger disc herniation at L3-L4 was removed through the laminectomy exposure. However, the smaller protrusion at L4-L5 was decompressed through the posterolaterally introduced Craig cannula. The patient had a satisfactory outcome with no complications.

In February 1974, a 52-yr-old male presented with right sciatica and was diagnosed with herniated discs at L3-L4 and L4-L5. This patient underwent a combined operative procedure. The herniated disc at L4-L5 was removed through the laminectomy site; however, the L3-L4 intervertebral disc was decompressed through the cannula that had been inserted dorsolaterally.

In April 1974, a 43-yr-old female with unremitting sciatic pain and myographic evidence of disc herniation at L4-L5 underwent percutaneous nucleotomy via a Craig cannula. This patient failed to respond to the nucleotomy procedure and subsequently required a laminectomy when a large disc herniation at the index level was identified and excised.

In June 1974, a similar combined operation was performed on a 52-yr-old male with clinical and myographic evidence of a large disc herniation at L5-S1 and a smaller protrusion at L4-L5. The L5-S1 herniation was excised through the laminectomy site, and the L4-L5 intervertebral disc was decompressed via a mechanical nucleotomy technique through the inserted cannula. Although in the ensuing years a number of patients underwent a simple mechanical nucleotomy via the inserted cannula and the combined procedure, we were unable to demonstrate an appreciable reduction in the size or shape of the herniation following a simple central nucleotomy. Therefore, our efforts were then directed toward the development of instruments and surgical techniques that would provide better access to posterolaterally dislodged disc fragments via a posterolateral approach. Newly designed instruments were developed that included a cannulated obturator (Fig. 8) for precise positioning of instruments and a 6.5-mm-od cannula that accommodated an upbiting forceps. This was followed by development of a flexible-tip forceps and a deflecting tube that permitted dorsal angulation of the inserted forceps and aided in evacuation of posterior nuclear tissue. In 1981, under the auspices of the Human Subjects Committee of The Graduate Hospital (Fig. 9), I initiated a series of preliminary



THE GRADUATE HOSPITAL
One Graduate Plaza, Philadelphia, Pa 19146 • (215) 893-2000

July 13, 1981

Dr. Parviz Kambin
Orthopaedic Surgery
2027 Pine Street
Philadelphia, Pa. 19103

Dear Doctor Kambin:

The Human Subjects Committee of the Graduate Hospital met on May 21, 1981 and approved your project/protocol entitled, "Per Cutaneous Lateral Diskectomy". The Committee also approved the consent form as drafted.

You are hereby authorized to initiate the aforementioned study in accordance with the terms and conditions as outlined in the protocol.

Sincerely yours,

(Miss) Marta Lee Bussard
Coordinator, Human Subjects Committee
Office of Research Administration

MLB

Fig. 9. Permission from Human Subjects Committee of The Graduate Hospital for experimental use of 6.4-mm-od cannula, using upbiting and flexible-tip forceps in percutaneous disc surgery.

investigations on the feasibility of the use of a 6.4-mm-od cannula using upbiting and flexible-tip forceps (Figs. 10 and 11) (34,35,40-43).

In 1975, Hijikata (Fig. 12) from the Toden Hospital in Japan independently experimented with mechanical nucleotomy via a 2.6-mm-od cannula that was inserted into the center of the intervertebral disc via a posterolateral access. He reported a satisfactory postoperative outcome in 64% of patients (44). Following Hijikata's experience, Schreiber and Suezawa developed a series of cannulas that were telescoped one over the other and placed in the center of the intervertebral disc via a posterolateral access. The larger cannulas with a 7 to 8-mm internal diameter (id) permitted the insertion of larger forceps and more rapid evacuation of nuclear tissue (45). In 1981, in the United States, Blum et al. (46) experimented with Hijikata's nucleotomy technique and reported their findings before the International Society of the Lumbar Spine. In 1983, Hoppenfield (47) also used a posterolateral approach and manual instruments for nucleotomy. Friedman and Jacobson experimented with a far lateral approach to access the lumbar intervertebral disc. These investigators passed a no. 40 French chest tube through an incision over the iliac crest and directed it toward the intervertebral disc at the index level. After annulotomy the disc fragments were evacuated with manual forceps (48). In 1985, Onick promoted the concept of central nucleotomy via a mechanical tool called a nucleotomy (49). The small caliber of the instruments and the simplicity of the operative procedure contributed to the popularity of the operative technique in the ensuing years (Fig. 13).




Fig. 10. Original instruments developed in early 1980s for percutaneous discectomy under X-ray control.

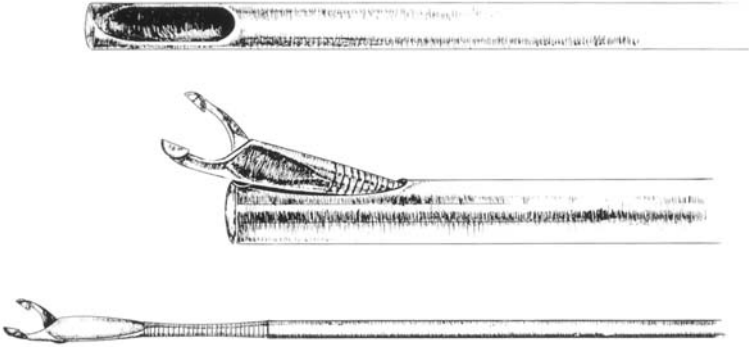


Fig. 11. Deflecting tube and flexible-tip forceps for access and removal of posteriorly lodged disc herniation and entry to L5-S1 intervertebral disc.

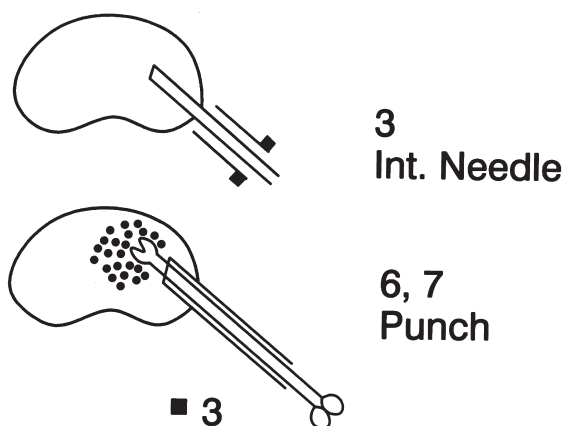


Fig. 12. Illustration from article by Hijikata showing the principle of central nucleotomy in 1975.

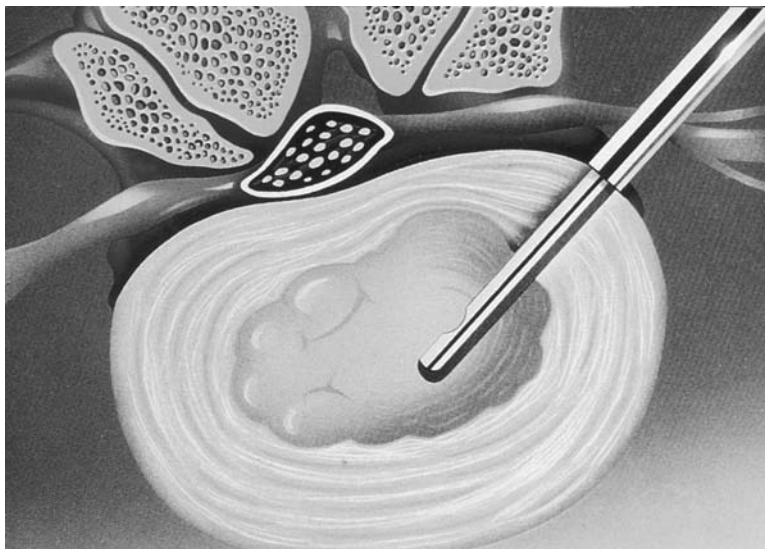


Fig. 13. Illustration demonstrating the use of nucleotome in the treatment of disc herniation.

The introduction of laser light into the surgical armamentarium opened another front in the management of lumbar disc herniation (35–50). The small caliber and relative flexibility of the laser fibers was a source of encouragement and appeared to be suitable for nuclear vaporization. A variety of laser lights were introduced into the marketplace and then used by many investigators. In January 1990, with the permission of the Federal Drug Administration and Internal Review Board of The Graduate Hospital, I initiated a clinical study of the feasibility of vaporizing disc fragments with laser light under arthroscopic illumination and magnification (51). It was found that the wide arc of deflection of the laser fibers and concern about injury to neural structures prevented adequate decompression and lysis of posterior herniated disc fragments.




Fig. 14. Articulating suction forceps used for intradiscal access to non-migrated sequestered disc herniation.

Striving Toward Access and Retrieval of Posterior Herniated Disc Fragments Via an Intradiscal Approach

While the advantages and safety of a small-caliber nucleotome and laser fibers for nuclear decompression were being promoted and debated in the late 1980s, my colleagues and I continued to utilize the standard 6.4-mm-od cannula for discectomy. Although our deflecting tube and flexible-tip forceps (Fig. 11) permitted posterior nucleotomy, we were unable to adequately access and retrieve subligamentous or nondisplaced extraligamentous herniations.

After a series of cadaver studies, it was determined that a high negative atmospheric pressure could be introduced into a contained intervertebral disc without any inadvertent complications. Subsequently, we introduced this technique into our clinical practice in an attempt to dislodge the herniated disc fragments and move them into the path of the inserted cannula (34,40,41). However, this technique was not always successful and was therefore later abandoned. An articulating forceps (Fig. 14) was introduced whose tip deflected far enough to access posterior and posterolateral herniated disc fragments intradiscally and to decompress directly the nerve roots (42,43,52).

IDENTIFICATION OF A SAFE ZONE ADJACENT TO NERVE ROOTS FOR ANCHORING OF INSTRUMENTS

Although posterolateral access to the intervertebral disc was used for biopsy of vertebral bodies (53–55), discography, chemonucleolysis (38), and automated nucleotomy (49), the site of lodging of instruments and annular window on the annulus had not been clearly defined. The close proximity of major neurovascular structures to the posterolaterally inserted instruments necessitated the identification of a safe zone on the posterolateral surface of the annulus fibrosus for anchoring cannulas with larger diameters. After a series of cadaver dissections at The Graduate Hospital and the Anatomy Laboratory of the Hospital of the University of Pennsylvania, a triangular safe zone on the posterolateral annulus, between the traversing and exiting nerve roots, was identified. Subsequently, we positioned needles in and around the safe zone and

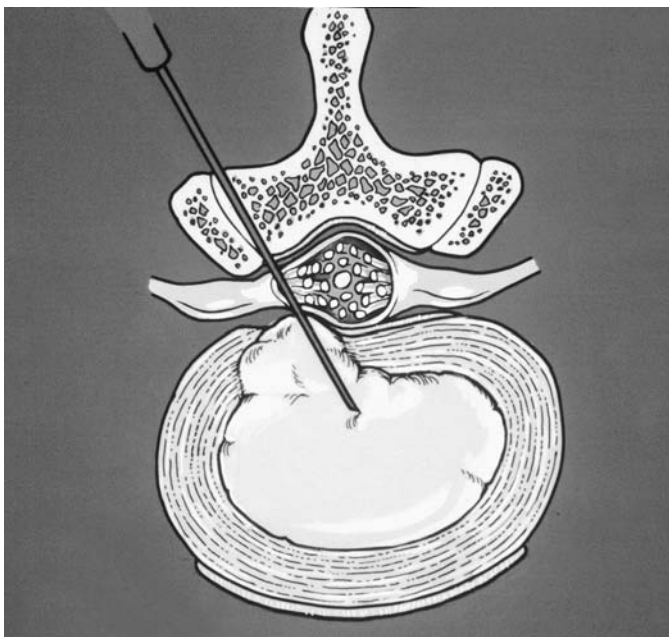


Fig. 15. Illustration demonstrating complications that may become associated with localization of needle in the center of the disc at the onset of percutaneous spine surgery. Note that the needle may pass through the ligamentum flavum and enter the intervertebral disc with a final satisfactory radiographic appearance in the anteroposterior and lateral projection.

radiographic studies were conducted. These allowed us to identify the radiographic landmarks of the safe zone in both the anteroposterior and lateral projections. Therefore, we began to emphasize the importance of localization of the tip of the inserted needle on the annulus at the onset of the operative procedure rather than in the center of the intervertebral disc (Fig. 15).

The triangular working zone is bordered anteriorly by the exiting root, inferiorly by the proximal plate of the lower lumbar segment, and medially by the traversing root and the dural sac. The floor of the triangular working zone is occupied by the intervertebral disc, the vertebral plate, and the posterior boundary of the adjacent vertebra (Fig. 16 A,B) (42,43,56,57). This region is covered by loosely woven adipose tissue and, at times, superficial veins, which are readily observed by arthroscopic or endoscopic examination. Mirkovik and Schwartz (58) independently measured the dimensions of the triangular working zone and have confirmed that cannulas with larger diameters can be safely inserted between the traversing and exiting roots in the course of arthroscopic or endoscopic spinal surgery.

The description of the radiographic landmarks of the triangular working zone made it possible to lodge the instruments precisely and to monitor them fluoroscopically both anteroposteriorly and laterally. It was stipulated that a midpedicular positioning of the instruments in the anteroposterior projection is suitable for intradiscal subligamentous or intracanalicular access to the contents of the spinal canal. Lateral pedicular line

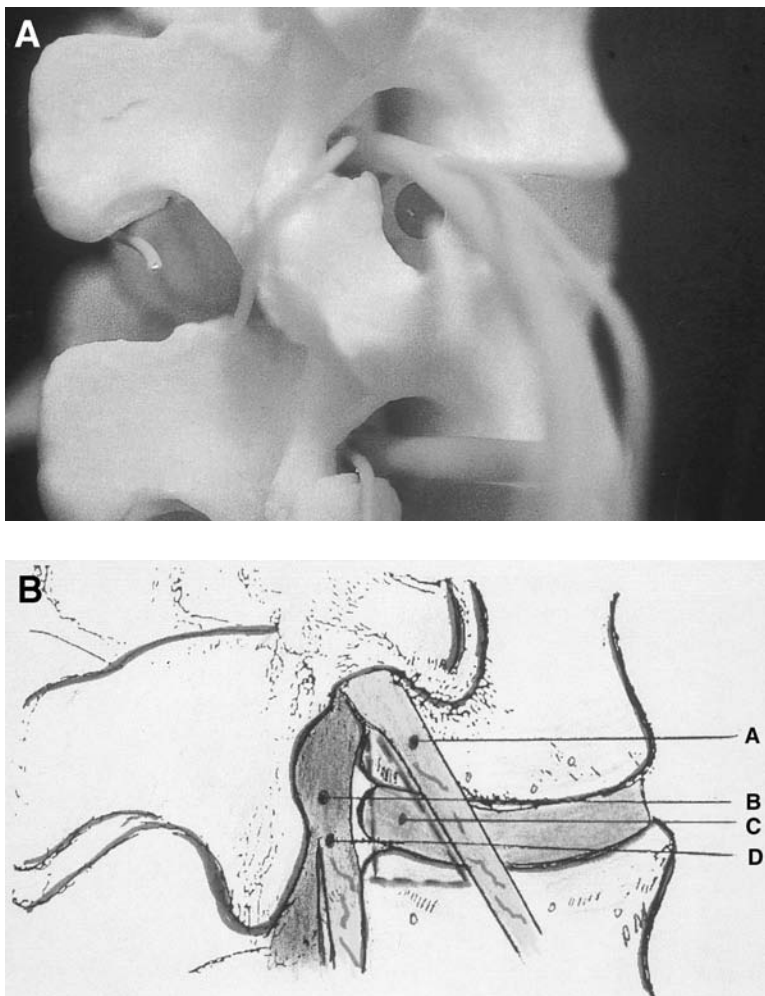


Fig. 16. (A) Copy of photo of triangular working zone which was published in 1988. (B) Illustration showing the boundaries of the triangular working zone: A, the exiting root; B, dural sac; C, intervertebral disc; D, traversing root.

positioning in the anteroposterior projection may be used for evacuation of an extraforaminal herniation (42,43).

History of Development of Larger-Diameter Cannulas

The oldest and most commonly used cannulas are the ones described by Ottolenghi (54) and Craig (53) that were commonly used for vertebral body biopsy. Hijikata originally suggested the use of a 2.6-mm-od cannula (44). However, he later modified his technique and used larger-diameter cannulas.

Onik developed an automated nucleotome (Fig. 13) for mechanical resection of nuclear tissue (49). The instrument was designed along the lines of Hijikata's instruments. At this stage of development, emphasis was placed on access and retrieval of nuclear tissue, rather than removal of herniated disc fragments and direct decompression of the nerve roots. Introduction of a large-diameter cannula in the clinical setting

lead to further investigation and description of the triangular working zone on the posterolateral annulus.

My colleagues and I originally used a Craig cannula for mechanical nucleotomy. However, in the early 1980s, we began to use cannulas with a larger diameter (6.4-mm od) (40). These provided a 5-mm inner working space. In addition, we introduced the concept of using a blunt-tipped cannulated obturator for precise positioning of the instruments on the annulus (Fig. 8).

We later introduced the concept of the unilateral biportal approach and oval cannulas (5 × 8 and 5 × 10 mm id) (59–64), (Fig. 17 A,B) that were designed to fit within the triangular working zone. The height of the intervertebral disc in the triangular working zone prevents the insertion of larger cylindrical-shaped cannulas into the intravertebral disc without the need for undue resection of the vertebral plates and part of the vertebral bodies of the adjacent segments. Schreiber et al. (45) and Shepperd (65) have continued to use gradually dilating, telescopic cannulas up to 10 mm in diameter to enter the intervertebral disc via a posterolateral access. In our experience, overstretching of the nerve roots by the larger cannulas was associated with postoperative dysesthesia, which led to the development of oval-shaped cannulas that proved safe in our clinical practice.

As early as 1991, we used 10- to 23-mm-id cannulas for the endoscopic interlaminar approach and intracanalicular surgery (62,63,66) (Fig. 18A,B) and arthroscopic foraminal decompression (60,79) (Fig. 18C). A modified version of this technology recently has been marketed (67).

Arthroscopic and Endoscopic Visualization and Birth of the Term Minimally Invasive Spinal Surgery

Bozzini, an obstetrician from Frankfurt, is credited with introducing the concept of visualizing internal organs in 1807 (Fig. 19), (68). His work was originally introduced to a faculty in Vienna and was rejected. He was criticized and censored for having unreasonable curiosity. However, Bozzini's noble idea continued to flourish, and many investigators further developed, enhanced, and successfully utilized endoscopes for the diagnosis and treatment of a variety of medical disorders (69).

Use of the scope for diagnosis of spinal abnormalities dates back to 1931, when Burman from the Hospital for Joint Diseases in New York City described his experience with the use of an endoscope for visualization of intracanalicular pathologies of the cauda equina in cadaver specimens. However, owing to the size of the instruments, he was unable to inspect the intrathecal structures (70).

In 1938, Pool from Columbia-Presbyterian Hospital in New York developed a myeloscope for intra thecal inspection of normal and abnormal structures (71,72). In recent years, other investigators have utilized rigid and flexible fiberoptics for visualization of the epidural and subarachnoid spaces (73,74). However, in our experience, it is difficult to advance flexible fiberoptics, particularly on the ventral surface of the dura. Invariably, close contact with and adhesions between the ventral dura and the posterior longitudinal ligament prevent clear visualization and advancement of the fibers and may result in a dural tear.

Hausmann and Forst (75) used an arthroscope to inspect the contents of the intervertebral disc following open laminectomy and discectomy. Schreiber et al. (45) used an arthroscope via a second portal that was inserted into the intervertebral disc dorsolater-

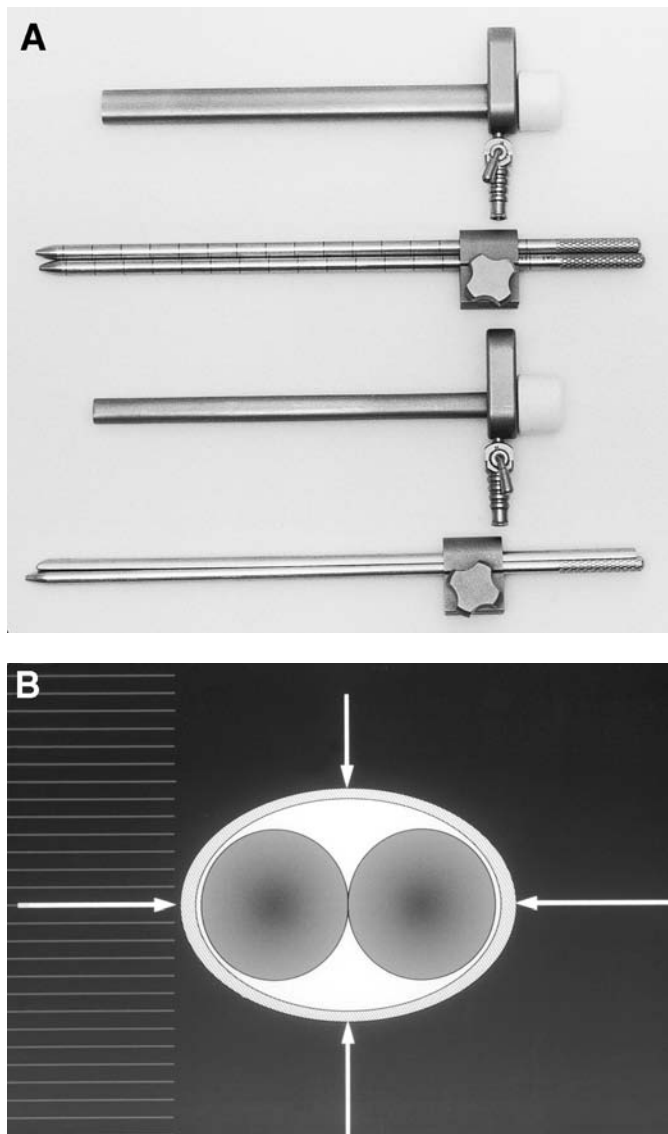


Fig. 17. (A) From top: 5 × 10 mm id oval cannula; two cannulated obturators are passed through the appropriate jig in preparation of insertion of a 5 × 10 mm oval cannula; and a 5 × 8 mm oval cannula, a cannulated obturator, and a half-moon cannula are passed through the lumen of the appropriate jig in preparation of insertion of a 5 × 8 mm oval cannula. (B) Illustration demonstrating cross section of two cannulated obturators, which permits their use together prior to insertion of an oval cannula.

ally from the opposite side in order to inspect and resect nuclear tissue under direct visualization.

A meaningful use of arthroscopes and endoscopes in the field of spinal surgery was not realized until 1988, when the anatomical and radiographic appearance of the posterolateral annulus was described for safe positioning of instruments adjacent to the spinal canal (42,56). Subsequently, the arthroscopic appearance of intradiscal, perian-