Reoperative Pediatric Surgery

Reoperative Pediatric Surgery

Edited by

Steven Teich, MD

Clinical Assistant Professor of Surgery
Ohio State University College of Medicine
Surgical Director, Neonatal Intensive Care Unit
Nationwide Children's Hospital
Columbus, Ohio

Donna A. Caniano, MD

Professor of Surgery and Pediatrics
Ohio State University College of Medicine
Surgeon-in-Chief
Nationwide Children's Hospital
Columbus, Ohio

Humana Press

Editors
Steven Teich
Department of Pediatric Surgery
Nationwide Children's Hospital
700 Children's Drive – ED323
Columbus, Ohio 43205
steven.teich@nationwidechildrens.org

Donna A. Caniano
Department of Pediatric Surgery
Nationwide Children's Hospital
700 Children's Drive – ED379
Columbus, Ohio 43205
donna.caniano@nationwidechildrens.org

ISBN: 978-1-58829-761-7 e-ISBN: 978-1-60327-071-7

Library of Congress Control Number: 2007936724

Cover illustration: The picture on the front cover depicts the two authors performing surgery together. We wish to thank Dr. Jon Groner for his photographic expertise.

Printed on acid-free paper

9 8 7 6 5 4 3 2 1

springer.com

We are inspired by our patients and their families, who place their trust in our surgical expertise and wisdom. During our training in pediatric surgery we were fortunate to have witnessed commitment to long term patient care by our esteemed teachers, Drs. H. William Clatworthy, Jr., E. Thomas Boles, Jr., and Marc I. Rowe.

We dedicate this book to our respective parents, Pauline and Abraham Teich and Mary and James Caniano, who taught us that we could accomplish anything through hard work and perseverance.

We also dedicate this book to our respective spouses, Esther Chipps and Richard Flores, who are our closest friends, wisest advisors, and sources of daily strength.

Steven Teich, MD
Donna A. Caniano, MD

Preface

"Good judgment comes from experience, and often experience comes from poor judgment."

Rita Mae Brown

Reoperative surgery is a challenge that is confronted by every surgeon. Although a particular operation may be initially performed with technical skill and followed by appropriate postoperative care, functional and/or anatomic problems may require further surgical attention.

The unique circumstances of pediatric patients may predispose them to a greater likelihood of requiring reoperation after a major procedure.

- A bowel resection in a neonate may develop a stricture if the anastamosis does not grow at the same rate as the adjacent bowel. The reoperative anastamotic technique is critical, as is the decision whether to resect or taper dilated bowel.
- The cancer survival rate has increased dramatically for many pediatric tumors. These patients often require reoperation for treatment of recurrences, as well as for treatment of complications of chemotherapy, such as second malignancies.
- Pediatric surgical patients often require lifelong follow-up that is obviously much longer than for adults. This increases the chances of requiring reoperation for many conditions, including gastroesophageal reflux disease and inguinal hernia.
- Even a "simple" gastrostomy may develop complications related to growth. With linear growth, the skin of the abdominal wall often migrates towards the chest wall. Therefore, the gastrostomy becomes angulated with leakage of gastric contents onto the abdominal wall, necessitating repositioning of the gastrostomy away from the costal margin.
- Pediatric patients with congenital diseases, such as cystic fibrosis, often require multiple reoperations for complications related to their underlying condition.

It is important to mention that not every pediatric surgery reoperative problem has a wealth of contemporary literature. Often reoperative surgery requires seldom used and more complex operative techniques. Frequently, these techniques are too new or too specialized to be found in current pediatric surgery textbooks. For this reason, we have enlisted a group of authors who are recognized experts for their respective topics to provide the most up-to-date information on reoperations for their pediatric surgical colleagues.

The pediatric surgery literature on reoperations is fragmented and sketchy. The need for a pediatric surgery textbook that critically analyzes and consolidates all the available literature on reoperations is obvious. For this reason, we have compiled a detailed source of information on reoperations for all areas of the body, all parts of the gastrointestinal tract, all types of pediatric solid tumors, and many common but perplexing problems that we co-manage with other pediatric specialists.

This book has been a labor of love. Now, we hope that it will become a valuable reference for pediatric surgeons, pediatric anesthesiologists, general surgeons performing pediatric surgery, and all pediatric physicians.

We wish to thank our secretaries, Cathy Rings and Teresa Rodich, for their invaluable assistance in the preparation of this book.

Steven Teich, *MD*
Donna A. Caniano, *MD*

Contents

SECTION V: GASTROINTESTINAL TRACT

SECTION VI: SOLID ORGANS

SECTION VII: REOPERATIVE ONCOLOGY

Contributors

Shahab Abdessalam, md • *Assistant Professor of Surgery, University of Nebraska School of Medicine, Attending Pediatric Surgeon, Children's Hospital of Omaha, Omaha, Nebraska*

Seth A. Alpert, md • *Clinical Assistant Professor, Department of Urology, Ohio State University College of Medicine, Attending Pediatric Urologist, Nationwide Children's Hospital, Columbus, Ohio*

Richard J. Andrassy, md • *Professor of Surgical Oncology, University of Texas Houston Medical School, Houston, Texas*

Marjorie J. Arca, md • *Assistant Professor of Surgery, Medical College of Wisconsin, Attending Pediatric Surgeon, Children's Hospital of Wisconsin, Milwaukee, Wisconsin*

D. Gregory Bates, md • *Clinical Assistant Professor of Radiology, Ohio State University College of Medicine, Section Chief, Fluoroscopy, Gastrointestinal & Genitourinary Radiology, Department of Radiology, Nationwide Children's Hospital, Columbus, Ohio*

Lesley L. Breech, md • *Associate Professor of Obstetrics and Gynecology, University of Cincinnati College of Medicine, Attending Pediatric Gynecologist, Cincinnati Children's Hospital Medical Center, Cincinnati, Ohio*

Mary Brindle, md • *Assistant Professor of Surgery, University of Alberta, Staff Surgeon, Alberta Children's Hospital, Calgary, Alberta, Canada*

Donna A. Caniano, md • *H. William Clatworthy Professorship in Pediatric Surgery, Professor of Surgery and Pediatrics, Ohio State University College of Medicine, Surgeon-in-Chief, Nationwide Children's Hospital, Columbus, Ohio*

Robert G. Castile, md, ms • *Professor of Pediatrics, Ohio State University College of Medicine, Center for Perinatal Research, Nationwide Children's Hospital, Columbus, Ohio*

Robert E. Cilley, md • *Professor of Surgery and Pediatrics, Penn State College of Medicine, Chief, Division of Pediatric Surgery, Penn State Children's Hospital, Milton S. Hershey Medical Center, Hershey, Pennsylvania*

Arnold G. Coran, md • *Professor of Surgery, University of Michigan School of Medicine, Attending Pediatric Surgeon, C.S. Mott Children's Hospital, Ann Arbor, Michigan*

Andrew M. Davidoff, md • *Associate Professor of Surgery and Pediatrics, University of Tennessee Health Science Center, Chief, Division of General Pediatric Surgery, St. Jude Children's Research Hospital, Memphis, Tennessee*

J. Terrance Davis, md • *Professor Emeritus of Clinical Surgery, Ohio State University College of Medicine, Interim Medical Director, Nationwide Children's Hospital, Columbus, Ohio*

Antoine DeBacker, MD, PhD • *Professor of Pediatric Surgery, Free University of Brussels, Head of Department of Pediatric Surgery, Academic Hospital of the Free University of Brussels, Brussels, Belgium*

Scott W. Elton, MD • *Clinical Auxiliary Faculty, Department of Neurosurgery, Ohio State University College of Medicine, Attending Pediatric Neurosurgeon, Nationwide Children's Hospital, Columbus, Ohio*

Moharned El-Sawaf, B.S., *University of Michigan, Department of Pediatric Surgery, C.S. Mott Children's Hospital, Ann Arbor, Michigan*

Brett W. Engbrecht, MD • *Assistant Professor of Surgery, Penn State College of Medicine, Attending Pediatric Surgeon, Penn State Children's Hospital, Milton S. Hershey Medical Center, Hershey, Pennsylvania.*

Renata B. Fabia, MD • *Clinical Assistant Professor of Surgery, Ohio State University College of Medicine, Attending Surgeon, Nationwide Children's Hospital, Columbus, Ohio*

Timothy C. Fabian, MD • *Harwell Wilson Alumni Professor and Chairman, Department of Surgery, University of Tennessee Health Science Center, Attending Surgeon, Regional Medical Center at Memphis, Memphis, Tennessee*

Dario O. Fauza, MD • *Assistant Professor of Surgery, Harvard Medical School, Associate in Surgery, Children's Hospital Boston, Boston, Massachusetts*

Jonathan I. Groner, MD • *Professor of Clinical Surgery and Pediatrics, Ohio State University College of Medicine, Trauma Medical Director, Nationwide Children's Hospital*

John B. Hamner, MD • *General Surgery Resident, St. Jude Children's Research Hospital, University of Tennessee Health Science Center, Memphis, Tennessee*

Matthew T. Harting, MD • *General Surgery Resident, University of Texas Medical School at Houston, Houston, Texas*

Melissa Hawyard, MD • *Surgical Research Fellow, Children's Hospital Boston, Boston, Massachusetts*

Andrea Hayes-Jordan, MD • *Assistant Professor of Surgery and Pediatrics, University of Texas Medical School at Houston, Attending Pediatric Surgeon, Texas Health Science Center at Houston and MD Anderson Cancer Center, Houston, Texas*

Frans W. J. Hazebroek, MD, PhD • *Professor Emeritus of Surgery, Erasmus MC-Sophia Children's Hospital, Rotterdam, the Netherlands*

Mark J. Hogan, MD • *Clinical Associate Professor of Radiology, Ohio State University College of Medicine, Section Chief of Vascular and Interventional Radiology, Department of Radiology, Nationwide Children's Hospital, Columbus, Ohio*

Eunice Y. Huang, MD • *Assistant Professor of Surgery, University of Tennessee Health Science Center, Attending Pediatric Surgeon, Le Bonheur Children's Medical Center, Memphis, Tennessee*

V. Rama Jayanthi, MD • *Clinical Assistant Professor, Department of Urology, Ohio State University College of Medicine, Attending Pediatric Urologist, Nationwide Children's Hospital, Columbus, Ohio*

Robert E. Kelly, Jr., MD • *Associate Professor of Clinical Surgery and Pediatrics, Eastern Virginia Medical School, Chief of Department of Surgery, Children's Hospital of The King's Daughters, Norfolk, Virginia*

Brian D. Kenney, md • *Assistant Professor of Clinical Surgery, Ohio State University College of Medicine, Attending Pediatric Surgeon, Nationwide Children's Hospital, Columbus, Ohio*

Denise B. Klinkner, md • *Surgical Research Fellow, Department of Surgery, Division of Pediatric Surgery, Children's Hospital of Wisconsin, Milwaukee, Wisconsin*

Stephen A. Koff, md • *Professor, Department of Urology, Ohio State University College of Medicine, Chief, Section of Pediatric Urology, Nationwide Children's Hospital, Columbus, Ohio*

Jacob C. Langer, md • *Professor of Surgery, University of Toronto, Robert M. Filler Chair and Chief, Division of General Surgery, Hospital for Sick Children, Toronto, Ontario, Canada*

Max R. Langham, Jr., md • *Professor of Surgery and Pediatrics, University of Tennessee Health Science Center, Chief, Division of Pediatric Surgery, Le Bonheur Children's Medical Center, Memphis, Tennessee*

Michael P. LaQuaglia, md • *Professor of Surgery, Weill Cornell University Medical School, Chief, Pediatric Surgical Service, Memorial Sloan-Kettering Cancer Center, New York, New York*

Marc A. Levitt, md • *Associate Professor of Surgery, University of Cincinnati College of Medicine, Associate Director, Colorectal Center for Children, Cincinnati Children's Hospital Medical Center, Cincinnati, Ohio*

Frederick R. Long, md • *Clinical Professor of Radiology, Ohio State University College of Medicine, Section Chief, Body CT and MRI Imaging, Department of Radiology, Nationwide Children's Hospital, Columbus, Ohio*

Andreas H. Meier, md • *Assistant Professor of Surgery, Penn State College of Medicine, Attending Pediatric Surgeon, Penn State Children's Hospital, Milton S. Hershey Medical Center, Hershey, Pennsylvania*

Rebecka L. Meyers, md • *Professor of Surgery, University of Utah, Chief, Division of Pediatric Surgery, Primary Children's Medical Center, Salt Lake, Utah*

Marc P. Michalsky, md • *Assistant Professor of Clinical Surgery, Ohio State University College of Medicine, Surgical Director, Center for Healthy Weight and Nutrition, Nationwide Children's Hospital, Columbus, Ohio*

Christopher R. Moir, md • *Associate Professor of Surgery, Mayo Clinic College of Medicine, Consultant, Division of Pediatric Surgery, Mayo Clinic, Rochester, Minnesota*

Jaimie Nathan, md • *Senior Clinical Fellow, Division of Pediatric and Thoracic Surgery, Cincinnati Children's Hospital Medical Center, Cincinnati, Ohio*

Bradley J. Needleman, md • *Assistant Professor of Surgery, Ohio State University College of Medicine, Director of Bariatric Surgery, Center for Minimally Invasive Surgery, Ohio State University Medical Center, Columbus, Ohio*

Jed G. Nuchtern, md • *Professor of Surgery and Pediatrics, Baylor College of Medicine, Attending Surgeon, Texas Children's Hospital, Houston, Texas*

Benedict C. Nwomeh, md • *Assistant Professor of Clinical Surgery, Ohio State University College of Medicine, Attending Pediatric Surgeon, Nationwide Children's Hospital, Columbus, Ohio*

Alberto Pena, md • *Professor of Surgery, University of Cincinnati College of Medicine, Director, Colorectal Center for Children, Cincinnati Children's Hospital Medical Center, Cincinnati, Ohio*

Alistair B. M. Phillips, md • *Assistant Professor of Surgery, Ohio State University College of Medicine, Attending Pediatric Cardiothoracic Surgeon, Nationwide Children's Hospital, Columbus, Ohio*

John M. Racadio, md • *Associate Professor of Clinical Radiology and Pediatrics, University of Cincinnati, Division Chief, Interventional Radiology, Cincinnati Children's Hospital Medical Center, Cincinnati, Ohio*

Ravi S. Radhakrishnan, md • *General Surgery Resident, University of Texas-Houston Medical School, Memorial Hermann Children's Hospital, Houston, Texas*

David A. Rodeberg, md • *Assistant Professor of Surgery, University of Pittsburgh School of Medicine, Attending Pediatric Surgeon, Children's Hospital of Pittsburgh, Pittsburgh, Pennsylvania*

Bradley M. Rodgers, md • *Maurice L. LeBauer Professor of Surgery, University of Virginia Health System, Division Head, Division of Pediatric Surgery, Children's Medical Center, Charlottesville, Virginia*

Frederick C. Ryckman, md • *Professor of Surgery, University of Cincinnati College of Medicine, Director, Liver Transplant, Surgical Director, Intestinal Transplant Surgery, Cincinnati Children's Hospital Medical Center, Cincinnati, Ohio*

William E. Shiels, II, do • *Clinical Professor of Radiology, Pediatrics, and Biomedical Engineering, Ohio State University College of Medicine, Chairman, Department of Radiology, Nationwide Children's Hospital, Columbus, Ohio*

Stephen J. Shochat, md • *Professor of Surgery and Pediatrics, University of Tennessee Health Science Center, Surgeon-in-Chief and Chair of Department of Surgery, St. Jude Children's Research Hospital, Memphis, Tennessee*

Michael A. Skinner, md • *Edwin Ide Smith, MD, Professor of Pediatric Surgery, The University of Texas Medical School, Vice Chairman, Department of Pediatric Surgery, Children's Medical Center, Dallas, Texas*

Elisabeth Tracy, md • *Senior Assistant Resident, Duke University, Department of Surgery, Durham, North Carolina*

Daniel H. Teitelbaum, md • *Professor of Surgery, The University of Michigan School of Medicine, Attending Pediatric Surgeon, C.S. Mott Children's Hospital, Ann Arbor, Michigan*

Steven Teich, md • *Clinical Assistant Professor of Surgery, Ohio State University College of Medicine, Attending Pediatric Surgeon, Nationwide Children's Hospital, Columbus, Ohio*

Sanjeev A. Vasudevan, md • *General Surgery Resident, Michael E. DeBakey Department of Surgery, Baylor College of Medicine, Houston, Texas*

Brad W. Warner, md • *Apolline Blair Professor, Washington University School of Medicine, Chief Division of Pediatric Surgery, Surgeon-in-Chief, St. Louis Children's Hospital, St. Louis, Missouri*

Eugene S. Wiener, md • *Deceased, Medical Director, Children's Hospital of Pittsburgh, Pittsburgh, Pennsylvania*

Jay M. Wilson, md • *Associate Professor of Surgery, Harvard Medical School, Director of Surgical Critical Care, Children's Hospital, Boston, Massachusetts*

Moritz M. Ziegler, md • *Professor of Surgery, University of Colorado School of Medicine, Surgeon-in-Chief, The Children's Hospital, Denver, Colorado*

1 Radiology of the Postoperative Patient

Diagnosis and Intervention

William E. Shiels, II, DO, D. Gregory Bates, MD, and Mark J. Hogan, MD

Contents

INTRODUCTION

The integrated and effective use of radiological diagnostic modalities and interventional techniques and therapies provides the surgeon with the opportunity to make accurate diagnoses of reoperative issues and complications and to provide timely intervention. A close functional relationship between surgeons and radiologists allows the surgeon the full advantage of surgical therapies or radiological interventional techniques and therapies, as best suits the individual patient needs. Interventional radiology offers a multimodality image-guided and minimally invasive management approach to a multitude of reoperative issues and complications. Consultation between

From: *Reoperative Pediatric Surgery*
Edited by: S. Teich and D. A. Caniano © Humana Press, Totowa, NJ

the primary surgeon and the radiology team provides discussion of techniques, interventional therapeutic options, expected outcomes, and contingency plans. The surgeon must have a clear understanding of the contrast media used, anatomic approaches of interventional procedures, and associated potential complications, should operative intervention be required following radiological diagnosis and/or intervention.

ABSCESS OF THE CHEST AND ABDOMEN

Abdominal abscesses are the most common indication for image-guided drainage, and appendicitis is the most common etiology *(1–5)*. Appendicitis is more common in children than adults, and children are more likely to have perforated appendicitis and abscesses *(1–3,5–7)*. Percutaneous drainage combined with antibiotics may allow for delayed less-invasive surgery (laparoscopic or small right lower quadrant [RLQ] incision) in children who present with rupture and abscess *(7–14)*. Alternatively, the drainage of postoperative abscesses can eliminate a second surgery *(2–7)*. Other causes of intraabdominal abscesses are less common, but include infected cerebrospinal fluid (CSF) and pancreatic pseudocysts, necrotizing enterocolitis (NEC), Crohn's disease, and postoperative abscesses of any cause.

The imaging techniques are dependent on the suspected site of abscess. Although CT scanning is most commonly used for abdominal sepsis (Fig. 1), magnetic resonance imaging (MRI) or ultrasound may be more useful in the musculoskeletal system or with superficial lesions (Fig. 2).

After obtaining appropriate history, physical examination, laboratory tests, and abdominal plain radiographs, abdominal computed tomography (CT) scan has become the gold standard for the diagnosis of abdominal abscess *(1,3,4)*. If the patient's

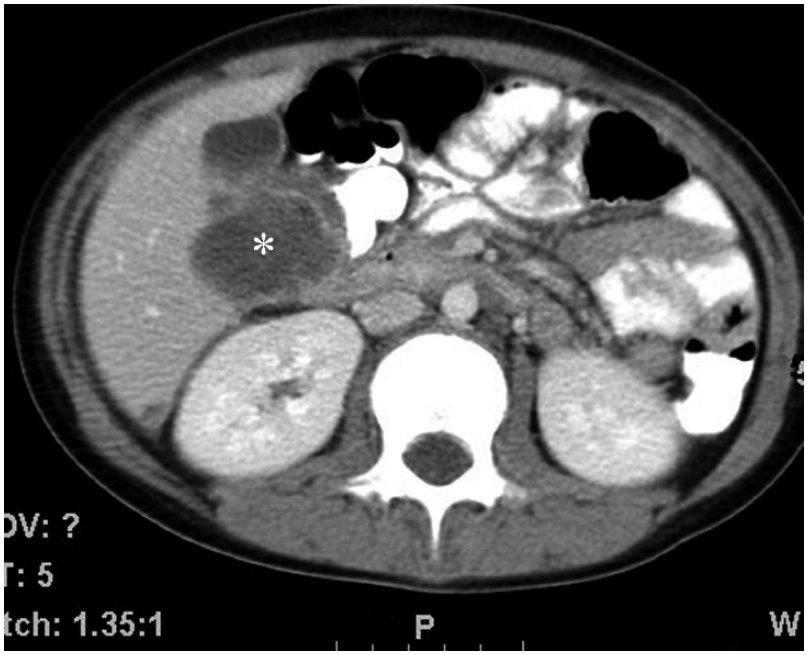

Fig. 1. CT scan of a febrile patient after surgery for ruptured appendicitis shows an abscess (*) near the gallbladder fossa.

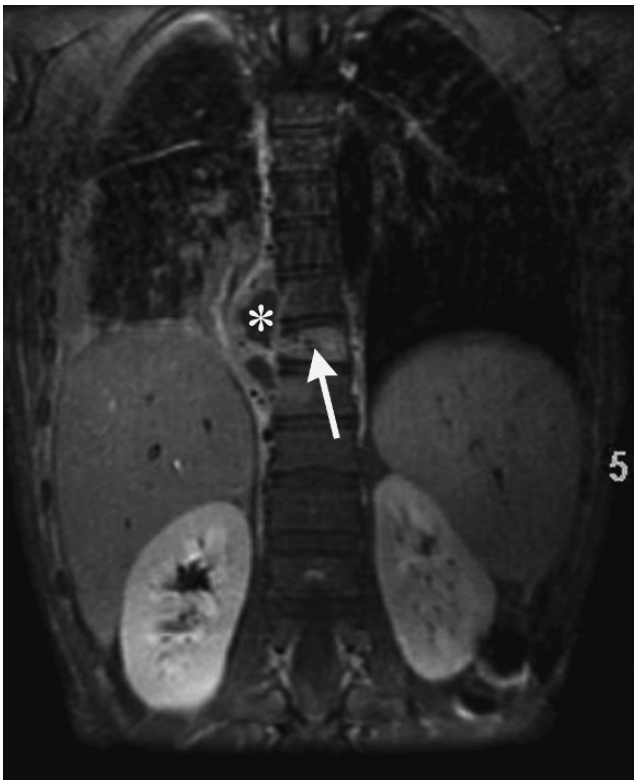

Fig. 2. Coronal image from an MRI shows osteomyelitis of a thoracic vertebral body (arrow), and an adjacent paraspinal abscess (*), drained with ultrasound guidance.

symptoms last longer than 48 hours or if the surgeon has a high clinical suspicion of abdominal abscess, a CT scan with both oral and IV contrast should be performed. The oral contrast improves the recognition of abscesses, as children have less intraabdominal fat than adults and oral contrast differentiates intestinal loops from abscess (Fig. 3). Although CT scanning for abdominal pain has proliferated rapidly, this increased utilization coincides with new information regarding radiation risks in children. Standardized CT dosing techniques are available to decrease exposure as much as possible. Ultrasound can sometimes substitute for CT. This is particularly true in infants with NEC.

Musculoskeletal abscesses are usually diagnosed either with MRI or ultrasound (Fig. 2). MRI is the best imaging tool to evaluate for abscesses related to osteomyelitis. Ultrasound can identify fluid collections within areas of cellulitis.

Neck infections are typically first imaged with CT (Fig. 4A,B). However, after an area of necrosis is identified, ultrasound is more reliable in determining if the lesion is fluid-filled and drainable (*15*). Chest abscesses are best imaged with CT, and will be discussed in the section on pulmonary infections (*16,17*).

Ultrasound guidance is ideal in children *(1)*. Children are usually smaller, which may allow sonographic visualization of abscesses. Ultrasound is portable, multiplanar, and provides real-time imaging without the deleterious effects of ionizing radiation. Freehand techniques allow the maximum flexibility during the procedure and increase

Fig. 3. Patient is postappendectomy for perforated appendix. Oral contrast on the CT allows for differentiation between the bowel loops and the abscess (*).

the access site choices. High-quality ultrasound equipment is required with multiple transducers ranging from high-frequency probes for excellent near-field visualization to larger lower frequency probes for deeper abscesses. Endocavitary probes are also needed for selective drainage procedures. CT and CT fluoroscopy are often the preferred guidance modalities in adults. These techniques are also useful in children when ultrasound cannot visualize the abscess because of overlying gas or bone; however, the radiation exposure must be minimized *(18)*.

Most abdominal abscesses are accessible from a transabdominal approach with ultrasonographic guidance (Fig. 5A,B), although deep pelvic abscesses may require transrectal or transgluteal techniques *(8,9,12–14,19,20)*. Transrectal drainage is guided with ultrasound, using either a transabdominal transducer and imaging through the bladder, or an endocavitary probe in the rectum (Figs. 6 and 7). Transgluteal drainage is usually performed with CT guidance *(14,20)*, although transgluteal ultrasound guidance has been described *(13)*. Transgluteal drainage has a reported higher complication rate because of vascular injury and is considered more painful; however, even with the smaller sciatic notch in children, some have excellent success with this technique *(14, 20)*. Abscesses in other sites are accessed through the most direct approach, avoiding vascular and other important structures.

Needles, wires, and catheters are similar to those used in adults. Because of sedation concerns and the lack of cooperation in most children, we choose equipment that provides the greatest procedural efficiency. Ultrasound guidance allows the use of larger needles in smaller patients as the advancement is performed in real time, and the best access window is chosen. This decreases the number of steps and simplifies the procedure. If the access window is small, or if CT guidance is necessary, smaller access sets are available. Standard drainage catheters are available from multiple manufacturers, with most patients receiving 8–12 Fr drains, although that is dependent on the thickness of the fluid. Smaller catheters (5 or 6 Fr) are often helpful in neck or

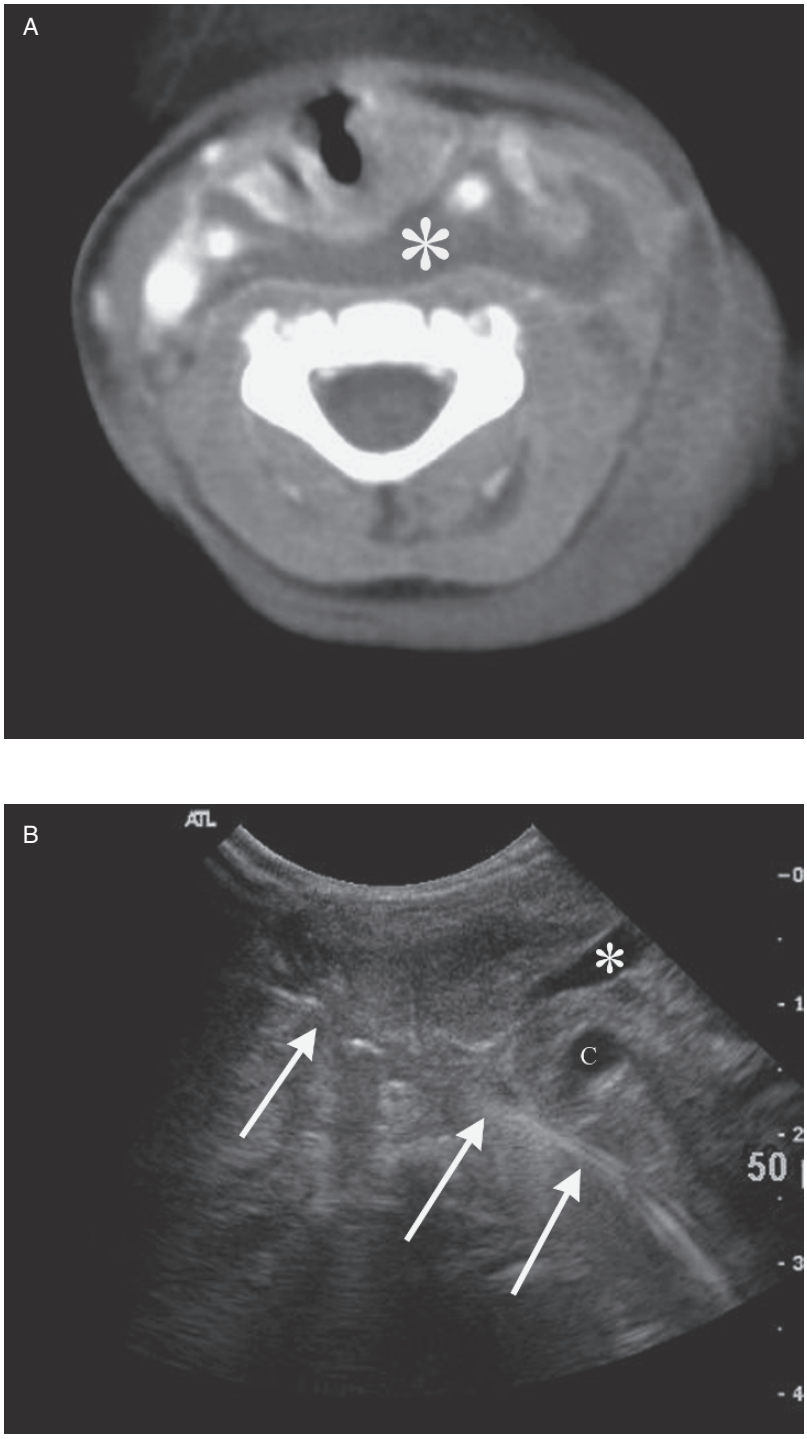

Fig. 4. Patient with fever after tonsillectomy. **(A)** There is a retropharyngeal abscess (*). **(B)** Demonstates ultrasound guidance to place a drainage tube (arrows) into the abscess avoiding the carotid artery **(C)** and the jugular vein (*).

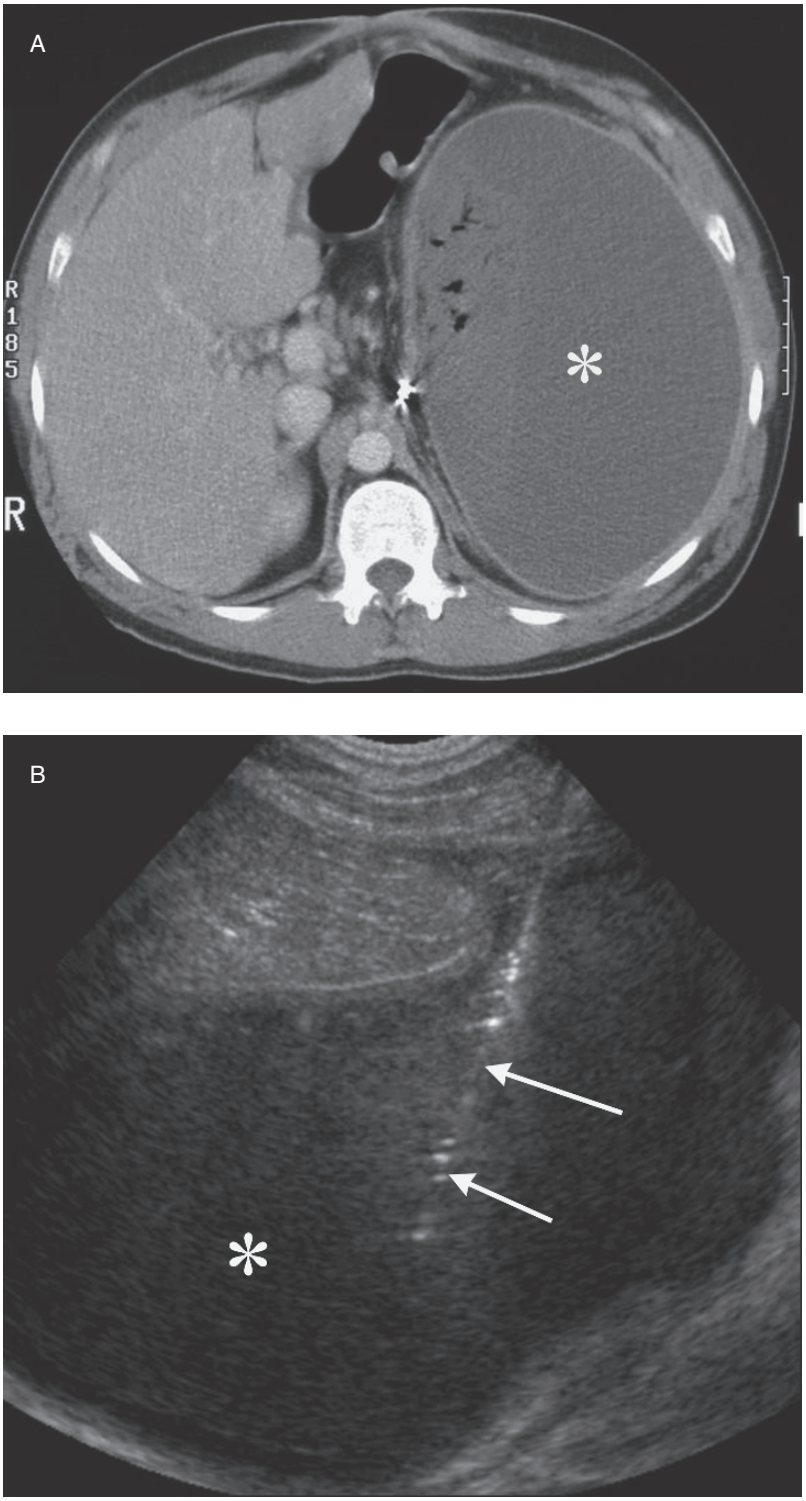

Fig. 5. Splenic abscess. **(A)** CT shows a large abscess (*) in the splenic bed after splenectomy. **(B)** Needle (arrows) placement into the abscess (*) with ultrasound guidance.

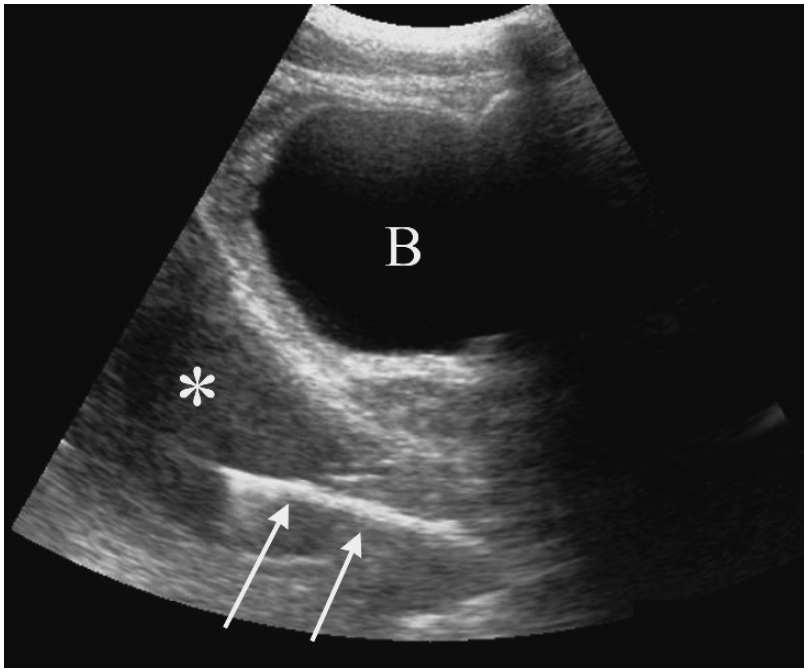

Fig. 6. Pelvic abscess (*) is seen behind the bladder (**B**). The drain (arrows) is advanced with ultrasound guidance into the abscess.

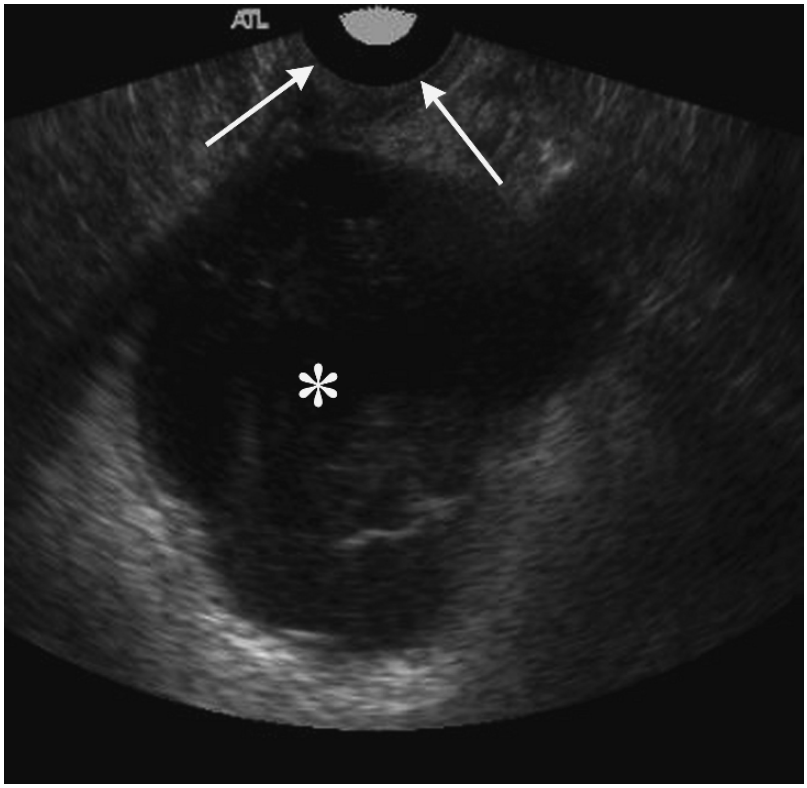

Fig. 7. Transrectal abscess drainage. The ultrasound probe (arrows) will guide placement of a drain into the pelvic abscess (*).

superficial abscesses; however, most abdominal abscesses require larger tubes because of increased fluid viscosity. For abscesses from NEC, 18–20 G intravenous catheters can be used for aspiration with ultrasound guidance (Fig. 8). This is often done portably with the premature infant remaining in an incubator.

The abscess is evacuated as much as possible immediately, and lab samples are sent. Currently, all catheters are placed to bulb suction, as the patients are not compliant with keeping the bag dependent for gravity drainage. The catheter is secured with an adhesive device unless the patient is too small to allow adequate fixation, in which case the catheter should be sutured to the skin. Saline flush with 10 cc is performed every shift. This amount should be subtracted from the tube output, although this is a common charting error.

Assessment is performed at least daily. The patient usually becomes afebrile with drainage less than 10 mL/day within 2 days, and almost always within 4 days; after which time the drain is removed. If tube output continues after 48 hours, we perform a tube injection to evaluate for a fistula.

Image-guided drainage procedures in both pre- and postoperative appendiceal abscesses are successful in 81–100% of patients *(7,8,10–13,20)*. Complications from abscess drainage are uncommon, occurring in up to 11% *(9–11)*, with catheter migration the most common *(8,11)*. Bloody pus is almost universal, but significant hemorrhage

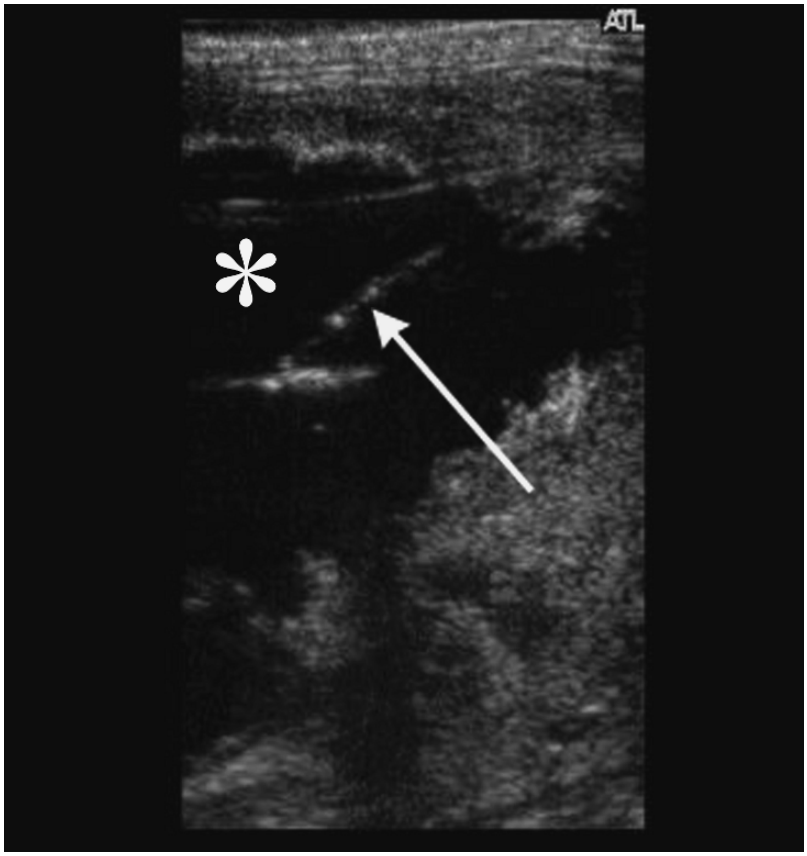

Fig. 8. An IV cannula (arrow) is advanced into abscess (*) after surgery for NEC.

is rare. Vascular injury can occur from any approach, but is probably more common with the transgluteal technique owing to the proximity of the gluteal vessels *(9,13,14)*. The inferior epigastric artery can be injured during transabdominal drainage, but can usually be identified and avoided with ultrasound during guidance for the procedure. Bowel perforation is another risk, but some authors traverse bowel when necessary without significant consequences *(7)*. Inadvertent injury to other organs and the female reproductive tract are possible but rare.

INTESTINAL FISTULA

Intestinal fistulae can originate from both normal and abnormal bowel. Postoperative fistulae may result from anastomotic leak or disruption of bowel, as well as from inadvertent injury during surgery. Spontaneous fistulae tend to originate from diseased bowel (i.e., Crohn's disease, radiation injury, malignancy, and ischemia *(21,22)*). There is approximately 30% incidence of fistula formation in patients with Crohn's disease *(23)*. Enterocutaneous, enteroenteric or enterocolic, entero- or colovaginal, and entero- or colovesical fistulous communications may be seen, depending on the location and etiology of the underlying disorder. Fistulae from intrinsically normal bowel tend to spontaneously close with conservative management. Those arising from diseased bowel often require surgical intervention *(23)*. The radiologic evaluation in patients with fistulizing disease continues to evolve with advances in imaging technology.

Plain film radiographs are commonly utilized as an initial screening evaluation in the patient with an acute abdomen, but are of limited utility for evaluation of fistulizing disease. On occasion, extraluminal gas may be seen in fistula or abscess cavity, but is often difficult to recognize *(24)*. Positive contrast (barium or water-soluble contrast) examinations utilizing the small bowel follow-through (SBFT), small bowel enteroclysis (SBE), or double-contrast barium enema remain valuable tools for evaluating internal fistulas between loops of bowel or between bowel and other organs. Fistulous tracts may be outlined by contrast or air, and demonstrate direct intercommunication between structures or end blindly in the soft tissues *(24)* (Fig. 9). Cutaneous fistulas may be studied by direct contrast injection following canalization of the cutaneous opening with an angiocatheter, feeding tube or Foley catheter (fistulogram).

Abdominal and pelvic CT combined with oral and intravenous contrast, or CT enteroclysis, are effective in demonstrating some forms of fistulae, predominately enteroenteric, enterocolic, enterocutaneous, and enterovesical forms *(25)*. Enhancing extraluminal tracts, when associated with inflammatory disease, may be identified containing air or fluid. Enterovesical and colovesical fistulas may demonstrate air within the bladder and focal bladder wall thickening at the site of fistulous communication. Scanning of the pelvis should be obtained prior to intravenous contrast administration so as not to obscure contrast with in the bladder lumen originating from the fistulous tract *(24)*. Complications related to fistula formation (i.e., abscess formation), are also readily recognized.

Recent advances in MRI techniques, shortened scan times, and improved tissue contrast have led to increased utility in imaging of the gastrointestinal tract. Contrasted enhanced MRI is highly sensitive for depicting active bowel inflammation, distinguishing acutely inflamed bowel with luminal narrowing from fibrotic strictures, defining extraintestinal complications, and in colorectal disease. MRI is now the imaging study of choice for evaluating complex perianal fistulae as are commonly present in Crohn's disease. MRI can accurately determine a fistulous tract's relationship

Fig. 9. Enterocolonic fistulae. Anterior radiograph of the abdomen during SBFT. Multiple inflamed segments of bowel are demonstrated consistent with Crohn's disease. Contrast containing enterocolic fistulae (arrowheads) are demonstrated with contrast extending into the rectum. Blind-ending sinus tracts are noted centrally.

to the sphincters and levator ani, which is crucial for therapy. Fistulae and sinus tracts are hypointense (dark) on T1-weighted sequences and hyperintense (bright) on T2-weighted sequences, depending on the amount of fluid, edema, and inflammation *(24)*.

The interventional radiological management of enteric fistulae centers on percutaneous drainage of associated abscesses (e.g., intraabdominal or psoas abscesses). In this setting, the catheter may drain longer than in more common abscess settings; however, when combined with medical therapy and bowel rest, will most often support fistula closure.

SMALL BOWEL OBSTRUCTION (SBO) AND ILEUS

Mechanical bowel obstruction results from an anatomic obstruction to flow of intestinal contests. In adynamic or paralytic ileus, there is reduced or absent peristalsis in all or a portion of the intestinal tract without actual mechanical obstruction. Differentiation between obstruction and ileus in the postoperative patient is difficult because the clinical presentation is clouded by incisional pain, narcotics, abdominal distention, and normal adynamic ileus *(26)*. The radiologic evaluation relies on direct communication between the radiologist and surgeon to avoid unnecessary delays in treatment. Prompt and precise imaging diagnosis allows triage of patients into a surgical or non-surgical management category.

Plain film radiography remains an important and frequently requested initial examination in patients with suspected obstruction. Supine and erect plain films of the abdomen should be obtained. In patients who are too sick to stand or in the young child, lateral decubitus views should be obtained *(27,28)*. Additional views include the horizontal beam decubitus films as well as the prone and crossfire prone views. These views assist in redistributing air (negative contrast) within the gastrointestinal tract, allowing more accurate

assessment of the presence or absence of air in the more distal part of the bowel *(29)*. On the supine and prone radiograph, gas is normally present in the stomach, colon, and rectum. The normal small bowel gas pattern includes absence of small bowel gas or presence of small amounts of gas within up to four nondistended loops (<2.5 cm in diameter). On the normal upright or decubitus film, air–fluid levels are almost always seen in the stomach and occasionally in the cecum, ascending colon, and terminal ileum. There is normal distribution of gas and stool within a non-distended colon. A nonspecific bowel gas results when at least one loop of borderline or mildly distended small bowel (2.5–3 cm in diameter) with three or more air–fluid levels is present on upright or decubitus radiographs. The colonic and fecal distributions are normal or with mild distention. A pattern of probable SBO occurs when multiple gas- or fluid–fluid loops of dilated small bowel loops are seen with a relatively small or moderate amount of colonic gas. An unequivocal SBO pattern is defined as dilated gas or fluid-filled small bowel loops in the setting of a gasless colon *(26)* (Fig. 10). There should be no difficulty in distinguishing between unequivocal SBO

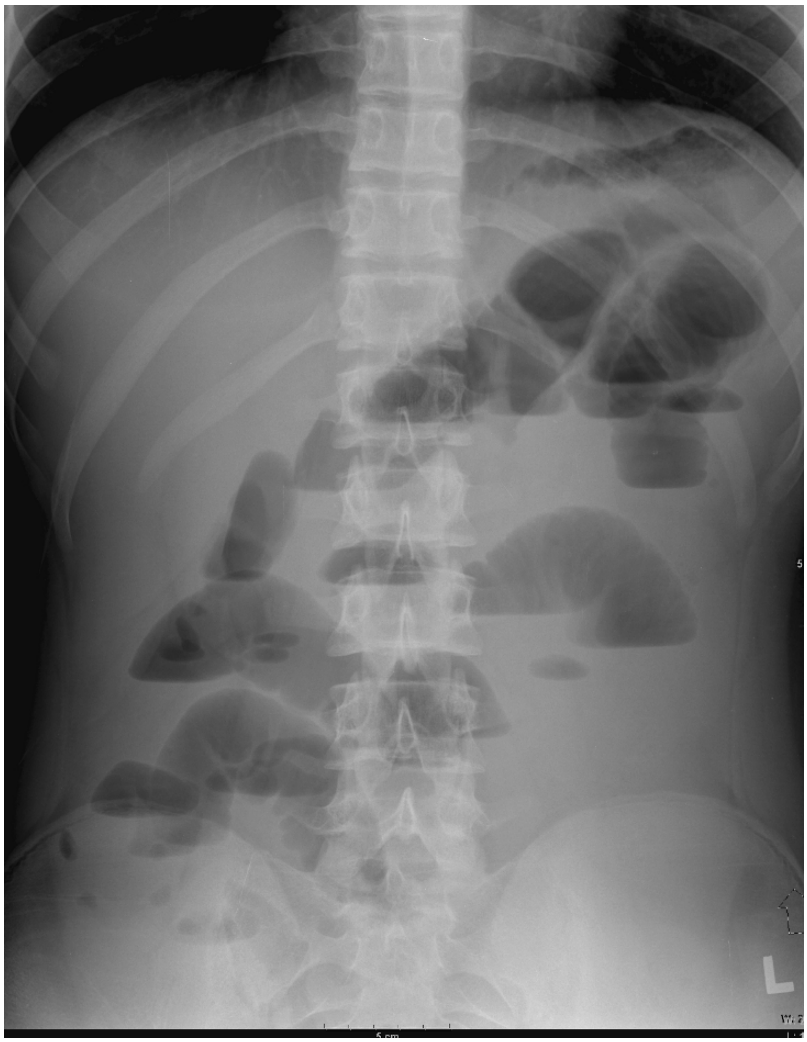

Fig. 10. SBO. Upright view of the abdomen demonstrating unequivocal SBO. Multiple distended loops of small bowel are seen with air–fluid levels. No colonic gas can be identified.

and the diffuse and proportional dilation of the small bowel and colon characteristic of paralytic ileus (Fig. 11).

If there is doubt as to the diagnosis after plain films, contrast studies of the bowel help to separate mechanical obstruction from ileus. If colonic ileus or distal colonic obstruction with an incompetent ileocecal valve is suspected, barium enema is fast and inexpensive. The SBFT examination has been used to triage patients with suspected SBO into surgical and nonsurgical management categories, but has largely been replaced by the widespread use of abdominal CT. The major disadvantages to the SBFT include: inability of patients with suspected SBO to ingest large quantities of contrast; difficulty in assessing distensibility and fixation of the small bowel; flocculation and dilution of barium in high-grade obstruction with incomplete bowel opacification; and the length of exam—hours or longer before contrast reaches the point of obstruction *(26)*.

Enteroclysis challenges the distensibility of the bowel wall and exaggerates the effects of mild or subclinical obstruction (Fig. 12). Intubating the small bowel bypasses the stomach and allows direct delivery of nondiluted barium or iodinated contrast (CT enteroclysis) directly into the jejunum. Advantages include: controlled infusion of contrast promotes antegrade flow toward site of obstruction despite diminished

Fig. 11. Ileus. Supine radiograph of the abdomen demonstrating diffuse gaseous distention of the small and large bowel.

Fig. 12. Spot radiograph from an enteroclysis demonstrating differential dilatation of proximal versus non-dilated (arrow) mid-jejunal loops secondary to low-grade adhesive disease.

bowel peristalsis; facilitates detection of fixed and nondistensible bowel segments; high sensitivity (100%) and specificity (88%) for SBO and high accuracy in determining the cause of obstruction (86%); detects multiple levels of obstruction; and most importantly, is highly reliable in diagnosing partial low-grade obstruction or excluding the diagnosis compared to conventional CT or SBFT *(26)*. SBO is excluded by enteroclysis when contrast passes unimpeded through normal caliber small bowel loops from duodenum to right colon. Mechanical obstruction is confirmed by the demonstration of a transition zone from a proximally distended segment to collapsed distal segment beyond the obstruction *(26,30)*.

Conventional CT is highly sensitive in distinguishing high-grade small bowel obstruction from ileus (Fig. 13), and should be the initial study of choice in patients with suspected SBO in the immediate postoperative period or when the clinical presentation suggests underlying abscess, closed loop obstruction, or strangulation *(26,31)*. In the absence of clinical suspicion of these conditions, or if the CT findings are equivocal for obstruction, CT enteroclysis may establish the diagnosis by providing volume-challenged distention of bowel loops. Water-soluble contrast is initially infused through an enteral catheter placed in the proximal small bowel at fluoroscopy, followed immediately by CT during continued contrast infusion. This technique overcomes the insensitivity of conventional CT for diagnosing lower grades of obstruction and is equivalent to barium enteroclysis in patients with low-grade partial SBO. CT

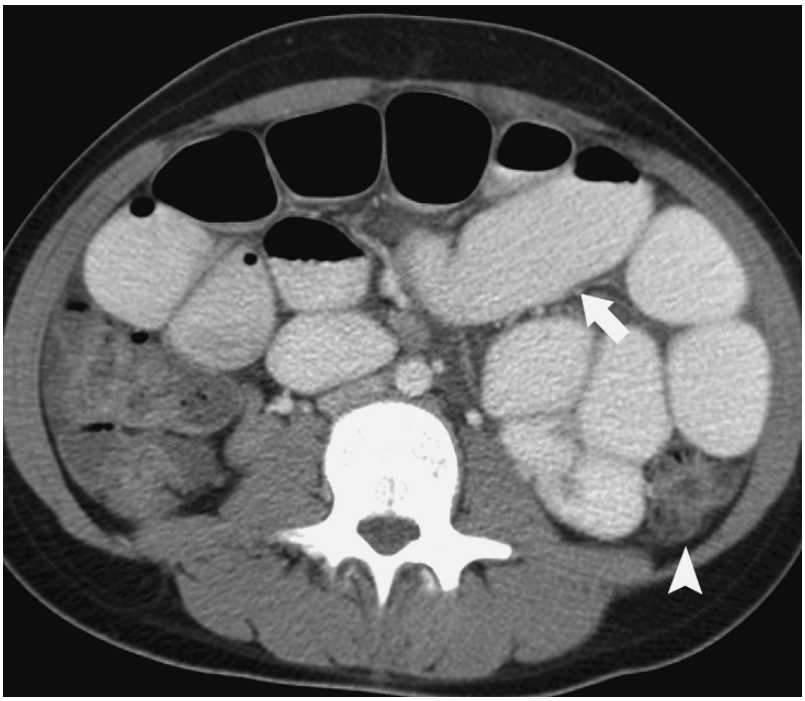

Fig. 13. SBO. Axial image from abdominal CT demonstrating dilated small bowel (arrow) and collapsed colon (arrowhead). Not shown is high-grade distal ileal obstruction caused by severe inflammatory bowel disease.

enteroclysis with multiplanar reformatting can map the location of parietal and visceral adhesions, helping to select appropriate access sites into to the peritoneal cavity *(32)*.

MRI currently has a limited role in mechanical SBO. MRI enteroclysis has the potential to change the assessment of the small bowel through its multiplanar imaging capabilities, its lack of ionizing radiation, and the functional information and soft tissue contrast that it can provide *(26,33)*. Further research and experience may clarify whether MRI imaging and enteroclysis will play a role in evaluating SBO or be used as a problem solving examination.

ESOPHAGEAL DISORDERS

Foreign Body

Ingestion of foreign bodies is common in the young child, coins being the most frequent. Fortunately, the large majority of swallowed objects pass through the gastrointestinal tract without complication. Foreign bodies can become lodged in the esophagus at characteristic locations of physiologic narrowing. The thoracic inlet is most common (75%), followed by the level of the left mainstem bronchus (20%), and least frequently just proximal to the gastroesophageal junction (5%). Patients with underlying esophageal pathology (i.e., caustic ingestion, tracheoesophageal fistula repair, or vascular ring), have foreign body retention in nonphysiologic positions *(34,35)*.

The initial radiographic evaluation should include radiographs of the neck, chest, and abdomen to evaluate the entirety of the intestinal tract from mouth to anus.

Esophageal foreign bodies are characterized as radiopaque or radiolucent, sharp or dull, and single or multiple *(34)*. The imaging appearance will influence treatment options. Complications of foreign body retention should be sought and include: high-grade esophageal obstruction with air–fluid levels; tracheal narrowing owing to local edema or mass effect; perforation with pneumomediastinum; mediastinal migration of the foreign body; and a mediastinal mass secondary to abscess formation.

A contrast esophagram is required for nonradiopaque foreign bodies. The radiolucent foreign body may be outlined by contrast or demonstrated as an irregular contour at the base of the contrast column in complete obstruction (Fig. 14). Contrast extension beyond the confines of the esophageal lumen defines perforation. CT can identify small foreign bodies not seen on standard radiographs, further characterize the features of a foreign body, and evaluate the paraesophgeal anatomy for edema, inflammation, or abscess formation. Esophageal foreign bodies associated with prior esophageal surgery may be retrieved via an endoscope or via transoral interventional radiological snare retrieval with fluoroscopic guidance. Fluoroscopically guided snare removal will either be successful or define foreign bodies that are adherent with granulation tissue that require surgical removal.

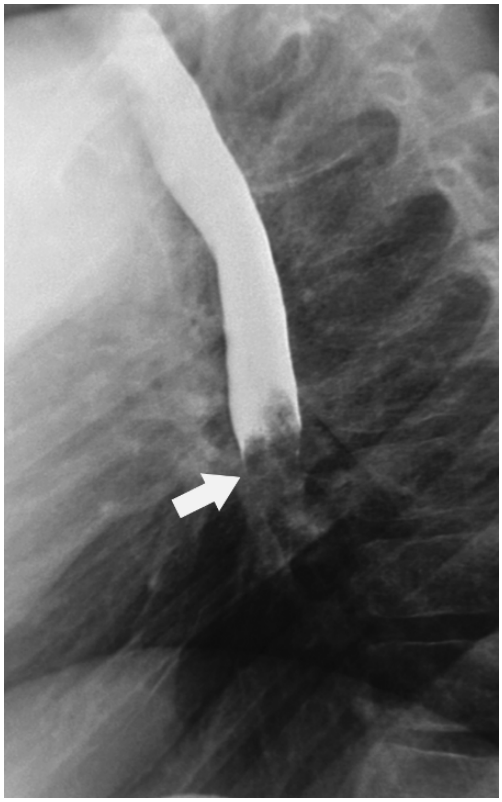

Fig. 14. Radiolucent foreign body. Lateral view from an esophagram demonstrating complete esophageal obstruction due to meat impaction (arrow).

Achalasia

Achalasia is a primary esophageal motility disorder characterized by increased lower esophageal sphincter (LES) tone and decreased lower esophageal peristalsis. Histologic degeneration of the myenteric plexus of Auerbach is the common cause of achalasia and leads to loss of inhibitory postganglionic neurotransmitter (nitrous oxide and vasoactice intestinal peptide) production, which is responsible for the relaxation of the LES and coordinated esophageal peristalsis *(36)*. Impaired emptying and gradual esophageal dilation are responsible for the development of clinical symptoms *(37)*. Patients present with progressive dysphasia to solids and liquids, chest pain, and regurgitation of undigested food.

Achalasia may be identified on the upright chest radiograph as a dilated esophagus with an air–fluid level and a paucity of gastric air. A barium esophagram should follow as the initial diagnostic examination of choice. Classic findings identified in achalasia include smooth tapered narrowing of the distal esophagus ("bird's beak" appearance) associated with atonic dilation of the lower two-thirds of the esophagus and a column of contrast in the esophageal lumen *(37)* (Fig. 15). CT scans are not generally recommended in the evaluation of achalasia unless there is suspicion of a mass

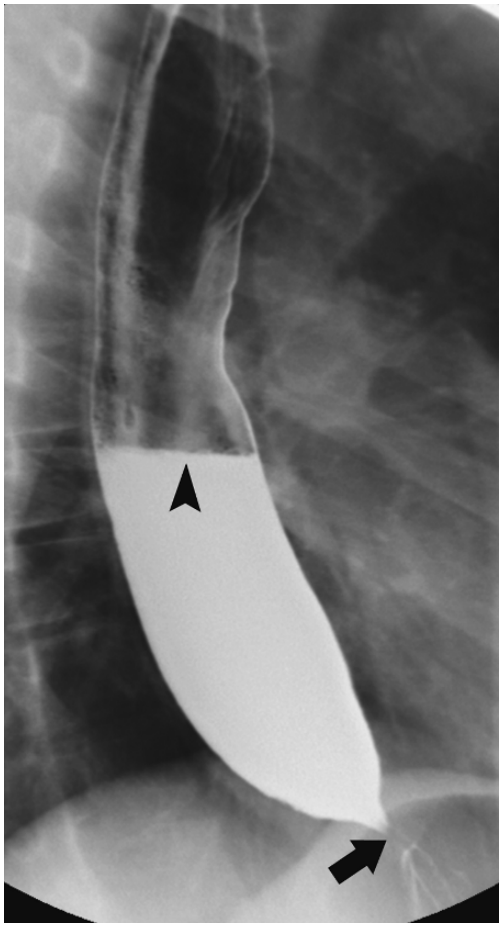

Fig. 15. Achalasia. Lateral view from an esophagram demonstrating a dilated esophagus, air–fluid level (arrowhead) and obstructed distal esophagus (arrow).

(adenocarcinoma, lymphoma, or others) at the gastroesophageal junction mimicking the findings of achalasia. Radiological intervention following surgical treatment of achalasia centers on balloon dilation of postmyotomy strictures. Balloon dilation with fluoroscopic guidance of distal esophageal stricture associated with achalasia is safe, to a diameter of 30 mm.

Esophageal Perforation

Instrumentation of the esophagus accounts for approximately two-thirds of all reported cases of esophageal perforation and can be seen following esophagoscopy, esophageal dilatation (bougienage or pneumatic), sclerotherapy, intraesophageal tube placement, and endotracheal intubation. Other causes include spontaneous perforation (Boerhaave's syndrome), foreign body ingestion, blunt chest trauma, operative injury, tumor, and severe esophagitis *(38,39)*. Rapid development of necrotizing mediastinitis, empyema, sepsis, and multiorgan failure account for the high mortality associated with esophageal perforation. Accurate diagnosis and early treatment are essential to the successful management of patients.

Lateral neck films may detect subcutaneous emphysema before identification on chest radiographs or by physical examination in cervical esophageal perforation *(40)*. When thoracic or abdominal perforation is suspected, posteroanterior and lateral radiographs of the chest as well as an upright or decubitus view of the abdomen should be obtained. Chest radiographs detect 90% of esophageal perforations; however, they can be negative if taken too early. Soft tissue and mediastinal emphysema are seen after 1 hour, whereas pleural effusions and mediastinal widening take several hours to develop *(39,40)*. The presence of pleural effusion, pneumomediastinum, subcutaneous emphysema, hydrothorax, hydropneumothorax, or subdiaphragmatic air on radiographs is highly suggestive of esophageal perforation *(41)*.

The contrast esophagram remains the standard for diagnosis of esophageal perforation (Fig. 16). Water-soluble contrast is recommended for initial screening of suspected perforation. Contrast extravasation is identified in only 50% of cervical and 75–80% of thoracic perforations. If no perforation is initially identified, barium esophagography is recommended. Barium improves detection of small primary or unsuspected secondary perforations. The detection rate increases to 60% for cervical and 90% for thoracic perforations *(42)*. Contrast studies have an overall 10% false negative rate.

CT identifies esophageal perforations that are difficult to diagnose or when contrast esophagrams cannot be performed. Abnormal findings suggestive of perforation include extraluminal air in the soft tissues of the mediastinum, esophageal thickening, visible communication of the air-filled esophagus with a contiguous mediastinal or paramediastinal air–fluid collection, or abscess cavities adjacent to the esophagus in the mediastinum or pleural space. Left-side pleural effusions are highly suggestive. In patients who fail to improve after initial treatment, CT assists in localizing pleural fluid or abscess collections amenable to interventional radiological drainage catheter placement.

Complications of Fundoplication

Gastroesophageal reflux disease (GERD) is a common condition for which medical management is effective in the large majority of patients. Those with intractable vomiting, persistent esophagitis, apnea, and pulmonary infections require further surgical management *(43)*. Antireflux surgery has been shown to be highly effective