

Stilianos E. Kountakis · Joseph B. Jacobs · Jan Gosepath (Eds.)

**Revision Sinus Surgery**

Stilianos E. Kountakis · Joseph B. Jacobs  
Jan Gosepath (Eds.)

# Revision Sinus Surgery

With 274 Figures and 41 Tables

 Springer

**Stilianos E. Kountakis, MD, PhD**

Department of Otolaryngology –  
Head and Neck Surgery  
Medical College of Georgia  
1120 Fifteenth Street, Suite BP-4136  
Augusta, GA 30912-4060  
USA  
*Email: skountakis@mail.mcg.edu*

**Jan Gosepath, MD, PhD**

Department of Otolaryngology –  
Head and Neck Surgery  
Dr. Horst Schmidt Kliniken  
Ludwig-Erhard-Straße 100  
65199 Wiesbaden  
Germany  
*Email: jan.gosepath@hsk-wiesbaden.de*

**Joseph B. Jacobs, MD**

New York University Medical Center  
Department of Otolaryngology  
530 First Avenue, Suite 3C  
New York, NY 10016-6402  
USA  
*Email: joseph.jacobs@med.nyu.edu*

ISBN 978-3-540-78930-7

e-ISBN 978-3-540-78931-4

DOI 10.1007/978-3-540-78931-4

Library of Congress Control Number: 2008923578

© 2008 Springer-Verlag Berlin Heidelberg

This work is subject to copyright. All rights are reserved, whether the whole or part of the material is concerned, specifically the rights of translation, reprinting, reuse of illustrations, recitation, broad-casting, reproduction on microfilm or any other way, and storage in data banks. Duplication of this publication or parts thereof is permitted only under the provisions of the German Copyright Law of September 9, 1965, in its current version, and permission for use must always be obtained from Springer. Violations are liable to prosecution under the German Copyright Law.

The use of general descriptive names, registered names, trademarks etc. in this publication does not imply, even in the absence of a specific statement, that such names are exempt from the relevant protective laws and regulations and therefore free for general use.

Product liability: the publishers cannot guarantee the accuracy of any information about dosage and application contained in this book. In every individual case the user must check such information by consulting the relevant literature.

The publisher and the authors accept no legal responsibility for any damage caused by improper use of the instructions and programs contained in this book and the DVD. Although the software has been tested with extreme care, errors in the software cannot be excluded.

*Cover design:* Frido Steinen-Broo, eStudio Calamar, Spain

*Production, reproduction and typesetting:* le-tex publishing services oHG, Leipzig, Germany

Printed on acid-free paper

9 8 7 6 5 4 3 2 1

springer.com

# Dedication

To the Memory of my mother, Eftihia Kountakis.  
To my wife Eleni, our children and our new baby girl Alexandra Elena.  
To my sister Maria Kountakis for her support during the difficult years.  
To my Rhinology Fellows for a lifetime of learning.

**Stilianos E. Kountakis, MD**

*To the Memory of my mother, Helen Jacobs.*  
To my wife Patti and my children Stacy and Allison.  
To my sons-in-law Rich and Jeff.  
To my granddaughter Ava.  
To the department of Otolaryngology at New York University.

**Joseph B. Jacobs, MD**

To my wife Anja  
To my academic teacher Professor Wolf J. Mann

**Jan Gosepath, MD, PhD**

# Preface

The field of rhinology has rapidly advanced over the last two decades, enabling surgeons to utilize endoscopic techniques and instrumentation to perform the majority of operations within the paranasal sinuses. Despite significant progress with medical management and surgical instrumentation, however, many patients who suffer from chronic sinonasal disease develop recurrences of symptomatic disease requiring revision endoscopic sinus surgery.

Anatomic alteration due to prior sinus surgery, mucosal scarring and associated chronic mucosal inflammation all increase the complexity of such procedures. Therefore, even in the hands of experienced sinus surgeons, increased risk of negative outcomes exists. This project was undertaken to develop a concise reference that provides an exhaustive source of information relating to the complex pre- and post-operative management of the revision

sinus surgery patient. *Revision Sinus Surgery* is the first textbook available dedicated to this topic.

International leading rhinologic experts were invited to author the book. Pertinent topics include specific surgical indications and techniques, pre- and post-operative medical management and recognition and treatment of surgical complications. Chapters are arranged with bulleted tips and pearls, as well as numerous illustrations to highlight the text. A DVD accompanies the book, containing videos that demonstrate actual procedures performed by the contributing authors. This book is a comprehensive volume that can be used as a complete reference source by all otolaryngologists.

**Stilianos E. Kountakis, MD, PhD**

**Joseph B. Jacobs, MD**

**Jan Gosepath, MD**

# Contents

Chapter 1 <b>Imaging Anatomy in Revision Sinus Surgery</b> ..... 1 <i>Ramon E. Figueroa</i>	Chapter 8 <b>Surgical Instruments in Revision Endoscopic Sinus Surgery</b> ..... 63 <i>Vijay R. Ramakrishnan and Todd T. Kingdom</i>
Chapter 2 <b>Indications for Revision Endoscopic Sinus Surgery</b> ..... 13 <i>Marc A. Tewfik and Martin Desrosiers</i>	Chapter 9 <b>Anesthetic Choices, Techniques, and Injections</b> ..... 71 <i>W. Derek Leight and Brent Senior</i>
Chapter 3 <b>Predictors of Failure of Primary Surgery</b> 19 <i>Iman Naseri and John M. DelGaudio</i>	Chapter 10 <b>Tips and Pearls in Revision Sinus Surgery</b> 79 <i>Alexander G. Chiu and David W. Kennedy</i>
Chapter 4 <b>Pathophysiology of Inflammation in the Surgically Failed Sinus Cavity</b> ..... 25 <i>Wytske J. Fokkens, Bas Rinia and Christos Georgalas</i>	Chapter 11 <b>Septal and Turbinate Surgery in Revision Sinus Surgery</b> ..... 91 <i>Joseph Raviv and Peter H. Hwang</i>
Chapter 5 <b>Medical Management after Primary Surgery Failure and Preoperative Medical Management</b> ..... 37 <i>Jan Gosepath</i>	Chapter 12 <b>Revision Endoscopic Surgery of the Ethmoid and Maxillary Sinus</b> ..... 101 <i>Biana G. Lanson, Seth J. Kanowitz, Richard A. Lebowitz, and Joseph B. Jacobs</i>
Chapter 6 <b>New Technologies for Revision Sinus Surgery</b> ..... 45 <i>Elisa M. Lynskey, Richard A. Lebowitz, Joseph B. Jacobs, and Marvin P. Fried</i>	Chapter 13 <b>Revision Endoscopic Surgery of the Sphenoid Sinus</b> ..... 109 <i>Richard R. Orlandi</i>
Chapter 7 <b>Surgical Anatomy in Revision Sinus Surgery</b> ..... 53 <i>Adam J. Folbe and Roy R. Casiano</i>	Chapter 14 <b>Endoscopic and Microscopic Revision Frontal Sinus Surgery</b> ..... 117 <i>Ulrike Bockmühl and Wolfgang Draf</i>

Chapter 15 <b>Revision Endoscopic Frontal Sinus Surgery</b> .....	127	Chapter 23 <b>Allergy and the Patient Requiring Revision Sinus Surgery</b> .....	193
<i>Patricia A. Maeso, Subinoy Das, and Stilianos E. Kountakis</i>		<i>Li-Xing Man and Berrylin J. Ferguson</i>	
Chapter 16 <b>Postoperative Medical Management</b> ...	135	Chapter 24 <b>Staging of Disease after Sinus Surgery Failure</b> .....	199
<i>Dennis F. Chang, David B. Conley, and Robert C. Kern</i>		<i>Valerie J. Lund</i>	
Chapter 17 <b>Evaluation and Treatment of Recurrent Nasal Polyposis</b> .....	143	Chapter 25 <b>Headache and the Patient who Failed Primary Sinus Surgery</b> .....	217
<i>Frederick C. Roediger and Andrew N. Goldberg</i>		<i>William H. Moretz III and Stilianos E. Kountakis</i>	
Chapter 18 <b>Revision Surgery for Allergic Fungal Rhinosinusitis</b> .....	153	Chapter 26 <b>Complications in Revision Sinus Surgery: Presentation and Management</b> .....	223
<i>Subinoy Das, Patricia A. Maeso, and Stilianos E. Kountakis</i>		<i>John Scianna and James Stankiewicz</i>	
Chapter 19 <b>Revision Endoscopic Surgery for Benign Sinonasal Tumors</b> .....	159	Chapter 27 <b>Revision Dacryocystorhinostomy</b> .....	235
<i>Michael J. Sillers and Yvonne Chan</i>		<i>Metin Onerci</i>	
Chapter 20 <b>Recurrent Cerebrospinal Fluid Leaks and Meningoencephaloceles</b> .....	167	Chapter 28 <b>Revision Endoscopic Transsphenoidal Hypophysectomy</b> .....	245
<i>Sarah K. Wise, Richard J. Harvey, and Rodney J. Schlosser</i>		<i>Karen A. Kölln and Brent A. Senior</i>	
Chapter 21 <b>Delayed Complications Following Sinus Trauma</b> .....	179	Chapter 29 <b>Revision Image-Guided Functional Endoscopic Sinus Surgery</b> .....	251
<i>David M. Poetker and Timothy L. Smith</i>		<i>Martin J. Citardi and Pete S. Batra</i>	
Chapter 22 <b>Recurrent Mucoceles</b> .....	185	Chapter 30 <b>Revision Endoscopic Sinus Surgery in Children</b> .....	269
<i>Benjamin Bleier, James N. Palmer, and Bradford A. Woodworth</i>		<i>Hassan H. Ramadan</i>	
		Chapter 31 <b>Open Approaches after Failure of Primary Sinus Surgery</b> .....	275
		<i>Mark C. Weissler</i>	

Chapter 32 <b>“Above and Below” Techniques in Revision Sinus Surgery</b> ..... 281 <i>Timothy Haegen, Ryan M. Rehl, and Winston C. Vaughan</i>	Chapter 36 <b>Objective and Subjective Outcomes after Revision Sinus Surgery</b> ..... 317 <i>Michael G. Stewart and Scott M. Rickert</i>
Chapter 33 <b>Revision Endoscopic Skull-Base Surgery</b> ..... 289 <i>Aldo C. Stamm, João Flávio, and Richard J. Harvey</i>	Chapter 37 <b>Bioabsorbable Materials in Revision Sinus Surgery</b> ..... 329 <i>Rakesh K. Chandra and Robert C. Kern</i>
Chapter 34 <b>Stenting in Revision Sinus Surgery</b> ..... 301 <i>Seth J. Kanowitz, Joseph B. Jacobs, and Richard A. Lebowitz</i>	Chapter 38 <b>Endoscopic Approach after Failure of Open Sinus Procedures</b> ..... 337 <i>Raymond Sacks and Larry Kalish</i>
Chapter 35 <b>Use of Intravenous Antibiotics in Sinus Surgery Failures</b> ..... 309 <i>Seth M. Brown, Abtin Tabaee, and Vijay K. Anand</i>	<b>Subject Index</b> ..... 347



# Contributors

**Vijay K. Anand, MD**

772 Park Ave  
New York, NY 10021  
USA

*Email: vijayanandmd@aol.com*

**Pete S. Batra, MD**

Section of Nasal and Sinus Disorders  
Head and Neck Institute  
Cleveland Clinic Foundation  
9500 Euclid Ave, A71  
Cleveland, OH 44195  
USA

*Email: batrap@ccf.org*

**Benjamin Bleier, MD**

Department of Otorhinolaryngology  
University of Pennsylvania  
3400 Spruce Street  
Philadelphia, PA 19104  
USA

*Email: benjamin.bleier@uphs.upenn.edu*

**Ulrike Bockmühl, MD, PhD**

Department of Otorhinolaryngology – Head and Neck  
Surgery  
University Hospital Gießen  
Klinikstraße 29  
35392 Gießen  
Germany

*Email: ulrike.bockmuehl@hno.med.uni-giessen.de*

**Seth M. Brown, MD, MBA**

12 North Main St., Suite 30  
West Hartford, CT 06107  
USA

*Email: sethmbrown@msn.com*

**Roy R. Casiano, MD**

University of Miami  
1475 NW 12th Ave  
Suite 4025  
Miami, FL 33136-1002  
USA

*Email: rcasiano@med.miami.edu*

**Yvonne Chan, MD, FRCSC**

Georgia Nasal and Sinus Institute  
4750 Waters Avenue  
Suite 112  
Savannah, GA 31404-6220  
USA

*Email: y.chan@utoronto.ca*

**Rakesh K. Chandra, MD**

Northwestern Sinus and Allergy Center  
Department of Otolaryngology – Head and Neck  
Surgery  
Northwestern University  
Feinberg School of Medicine  
675 N. St. Clair St.-Galter 15-200  
Chicago, IL 60611  
USA

*Email: rickchandra@hotmail.com*

**Dennis F. Chang, MD**

Loma Linda University Sinus and Allergy Center  
Department of Otolaryngology – Head and Neck  
Surgery  
Loma Linda University Medical Center  
11234 Anderson Street #2586A  
Loma Linda, CA 92354  
USA

*Email: dfchang@llccp.net*

**Alexander G. Chiu, MD**

Division of Rhinology  
Department of Otorhinolaryngology  
University of Pennsylvania  
3400 Spruce Street  
Philadelphia, PA 19104-4283  
USA

*Email: alexander.chiu@uphs.upenn.edu*

**Martin J. Citardi, MD**

Department of Otorhinolaryngology – Head and Neck  
Surgery  
University of Texas Medical School at Houston  
6431 Fannin, MSB 5.202  
Houston, TX 77030  
USA

*Email: martin.j.citardi@uth.tmc.edu*

**David B. Conley, MD**

Department of Otolaryngology  
Northwestern University  
Feinberg School of Medicine  
303 East Chicago Avenue  
Chicago, IL 60611-3008  
USA

*Email: dbcentmd@northwestern.edu*

**Subinoy Das, MD**

Department of Otolaryngology – Head and Neck  
Surgery  
Medical College of Georgia  
1120 Fifteenth Street, Suite BP-4136  
Augusta, GA 30912-4060  
USA

*Email: sdas@mcg.edu*

**John M. DelGaudio, MD**

Department of Otolaryngology  
The Emory Clinic  
1365 Clifton Road, NE  
Atlanta, GA 30322  
USA

*Email: john.delgaudio@emoryhealthcare.org*

**Martin Desrosiers, MD, FRCSC**

Montreal General Hospital, Room A2-141  
1650 Cedar Avenue  
H3G 1A4 Montreal, Quebec  
Canada

*Email: desrosiers\_martin@hotmail.com*

**Wolfgang Draf, MD, Hon MD, PhD, FRCSC**

INI International Neuroscience Institute  
ENT Department  
Rudolf-Pichlmayr-Straße 4  
30625 Hannover  
Germany

*Email: wdraf@aol.com*

**Berrylin J. Ferguson, MD**

Division of Sino-Nasal Disorders and Allergy  
Department of Otolaryngology  
University of Pittsburgh School of Medicine  
Eye and Ear Institute  
200 Lothrop Street, Suite 500  
Pittsburgh, PA 15213-2546  
USA

*Email: fergusonbj@upmc.edu*

**Ramon E. Figueroa, MD**

Department of Radiology  
Medical College of Georgia  
1120 Fifteenth Street, Suite BA-1414  
Augusta, GA 30912  
USA

*Email: rfigueroa@mcg.edu*

**João Flávio, MD**

Hospital Prof. Edmundo Vasconcelos  
Rua Borges Lagoa, 1450  
Vila Clementino  
CEP 04038-905, Sao Paulo  
Brazil

**Adam J. Folbe, MD**

Department of Otolaryngology – Head and Neck  
Surgery  
Wayne State University  
4201 St. Antoine  
5E UHC  
Detroit, MI 48201  
USA

*Email: afolbe@med.wayne.edu*

**Wytske J. Fokkens, MD**

Department of Otorhinolaryngology  
Academic Medical Centre  
University of Amsterdam  
Postbus 22660  
1100 DD Amsterdam  
The Netherlands

*Email: w.j.fokkens@amc.nl*

**Marvin P. Fried, MD**

Albert Einstein College of Medicine  
Department of Otolaryngology  
3400 Bainbridge Avenue, 3rd Floor  
Bronx, NY 10467  
USA  
*Email: mfried@montefiore.org*

**Christos Georgalas, MD**

Academic Medical Centre  
University of Amsterdam  
Postbus 22660  
1100 DD Amsterdam  
The Netherlands

**Andrew N. Goldberg, MD, MSCE, FACS**

University of California, San Francisco  
Department of Otolaryngology – Head and Neck  
Surgery  
San Francisco, CA 94143  
USA  
*Email: agoldberg@ohns.ucsf.edu*

**Jan Gosepath, MD, PhD**

Department of Otolaryngology – Head and Neck  
Surgery  
Dr. Horst Schmidt Kliniken  
Ludwig-Erhard-Straße 100  
65199 Wiesbaden  
Germany  
*Email: gosepath@hno.klinik.uni-mainz.de*

**Timothy Haegen, MD**

Head and Neck Surgery  
Naval Hospital Camp Pendleton  
PSC 477 Box 555191  
Camp Pendleton, CA 92055  
USA  
*Email: timothy.haegen@med.navy.mil*

**Richard J. Harvey, MD**

Medical University of South Carolina  
Department of Otolaryngology  
PO Box 250550  
135 Rutledge Ave., Suite 1130  
Charleston, SC 29425  
USA  
*Email: richard@richardharvey.com.au*

**Peter H. Hwang, MD**

Department of Otolaryngology  
Stanford University  
801 Welch Road  
Stanford, CA 94304  
USA  
*Email: phwang@ohns.stanford.edu*

**Joseph B. Jacobs, MD**

New York University Medical Center  
Department of Otolaryngology  
530 First Avenue, Suite 3C  
New York, NY 10016-6402  
USA  
*Email: joseph.jacobs@med.nyu.edu*

**Larry Kalish, MBBS (Hons), MS, MMed (Clin Epi), FRACS**

Department of Otorhinolaryngology  
Concord Repatriation Hospital  
Concord, Sydney  
NSW Australia  
*Email: lhkalish@mac.com*

**Seth J. Kanowitz, MD**

Ear, Nose, Throat – Head and Neck Surgery  
Advanced Sinus and Nasal Surgery  
95 Madison Avenue, Suite 105  
Morristown, NJ 07960  
USA  
*Email: sethkanowitzmd@gmail.com*

**David W. Kennedy, MD**

Department of Otolaryngology  
University of Pennsylvania  
3400 Spruce Street  
5th Floor – Ravdin Building  
Philadelphia, PA 19104-4283  
USA  
*Email: kennedyd@uphs.upenn.edu*

**Robert C. Kern, MD**

Department of Otolaryngology  
Northwestern University  
Feinberg School of Medicine  
303 East Chicago Avenue  
Chicago, IL 60611-3008  
USA  
*Email: rkern@nmff.org*

**Todd T. Kingdom, MD**

Department of Otolaryngology  
 University of Colorado  
 AO-1, 12631E 17th Ave, B205  
 P.O. Box 6511  
 Aurora, CO 80045  
 USA  
*Email: todd.kingdom@uchsc.edu*

**Karen A. Kölln, MD**

G0412 Neurosciences Hospital  
 101 Manning Drive  
 Chapel Hill, NC 27599-7070  
 USA  
*Email: kkolln@unch.unc.edu*

**Stilianos E. Kountakis, MD, PhD**

Department of Otolaryngology – Head and Neck  
 Surgery  
 Medical College of Georgia  
 1120 Fifteenth Street, Suite BP-4136  
 Augusta, GA 30912-4060  
 USA  
*Email: skountakis@mail.mcg.edu*

**Biana G. Lanson, MD**

Department of Otolaryngology  
 New York University  
 462 First Avenue  
 NBV 5E5  
 New York, NY 10016  
 USA  
*Email: bgl201@med.nyu.edu*

**Richard A. Lebowitz, MD**

Department of Otolaryngology  
 New York University Medical Center  
 530 First Avenue, Suite 3C  
 New York, NY 10016-6402  
 USA  
*Email: richard.lebowitz@nyumc.org*

**W. Derek Leight, MD**

Department of Otolaryngology – Head and Neck  
 Surgery  
 The University of North Carolina at Chapel Hill  
 G0412 Neurosciences Hospital, CB #7070  
 Chapel Hill, NC 27599  
 USA

**Valerie J. Lund MS FRCS FRCSEd**

Institute of Laryngology and Otology  
 University College London  
 Royal National Throat Nose and Ear Hospital  
 330 Grays Inn Road  
 London WC1X 8DA  
 United Kingdom  
*Email: v.lund@ucl.ac.uk*

**Elisa M. Lynskey, MD**

Department of Otolaryngology  
 New York University  
 462 First Avenue, NBV 5E5  
 New York, NY 10016  
 USA  
*Email: elisa.lynskey@med.nyu.edu*

**Patricia A. Maeso, MD**

Department of Otolaryngology – Head and Neck  
 Surgery  
 Medical College of Georgia  
 1120 Fifteenth Street, Suite BP-4136  
 Augusta, GA 30912-4060  
 USA  
*Email: pmaeso@mcg.edu*

**Li-Xing Man, MD, MSc**

Department of Otolaryngology  
 University of Pittsburgh School of Medicine  
 Eye and Ear Institute  
 200 Lothrop Street, Suite 500  
 Pittsburgh, PA 15213-2546  
 USA  
*Email: manl@upmc.edu*

**William H. Moretz III, MD**

Department of Otolaryngology – Head and Neck  
 Surgery  
 Medical College of Georgia  
 1120 Fifteenth Street, Suite BP-4136  
 Augusta, GA 30912-4060  
 USA  
*Email: wmoretz@mcg.edu*

**Iman Naseri, MD**

Department of Otolaryngology  
 The Emory Clinic  
 1365 Clifton Road, NE  
 Atlanta, GA 30322  
 USA

**Metin Önerci, MD**

Department of Otorhinolaryngology – Head and Neck Surgery  
University of Hacettepe  
06100 Sıhhiye, Ankara  
Turkey  
*Email: metin@tr.net*

**Richard R. Orlandi, MD, FACS**

Division of Otolaryngology – Head and Neck Surgery  
University of Utah School of Medicine  
50 North Medical Drive, 3C120  
Salt Lake City, UT 84132  
USA  
*Email: richard.orlandi@hsc.utah.edu*

**James N. Palmer, MD**

Hospital University of Pennsylvania  
3400 Spruce Street  
5th floor, Ravdin Building  
Philadelphia, PA 19104  
USA  
*Email: james.palmer@uphs.upenn.edu*

**David M. Poetker, MD, MA**

Department of Otolaryngology  
and Communication Sciences  
Medical College of Wisconsin  
9200 W. Wisconsin Ave  
Milwaukee, WI 53226  
USA  
*Email: dpoetker@mcw.edu*

**Hassan H. Ramadan, MD**

Department of Otolaryngology  
West Virginia University  
PO Box 9200  
Morgantown, WV 26506-9200  
USA  
*Email: hramadan@hsc.wvu.edu*

**Vijay R. Ramakrishnan, MD**

Department of Otolaryngology  
University of Colorado  
AO-1, 12631E 17th Ave, B205  
P.O. Box 6511  
Aurora, CO 80045  
USA

**Joseph Raviv, MD**

Department of Otolaryngology – Head and Neck Surgery  
Northwestern University Feinberg School of Medicine  
Evanston, IL  
USA  
*Email: j-raviv@enh.org*

**Ryan M. Rehl, MD**

Arizona Sinus Center  
1515 North 9th Street, Suite B  
Phoenix, AZ 85006  
USA  
*Email: rrehl@arizonasinus.com*

**Scott M. Rickert, MD**

Department of Otorhinolaryngology  
Weill Cornell Medical College  
1305 York Avenue, 5th Floor  
New York, NY 10021  
USA  
*Email: smr139@columbia.edu*

**Bas Rinia, MD**

Department of Otorhinolaryngology  
Academic Medical Centre  
University of Amsterdam  
Postbus 22660  
1100 DD Amsterdam  
The Netherlands

**Frederick C. Roediger, MD**

University of California, San Francisco  
Department of Otolaryngology – Head and Neck Surgery  
San Francisco, CA 94143  
USA  
*Email: froediger@ohns.ucsf.edu*

**Raymond Sacks, MD, Bch FCS, ORL FRACS**

Head of Department of Otorhinolaryngology  
Concord Repatriation Hospital  
Suite12, Level 1, The Madison  
25–29 Hunter Street  
Hornsby  
NSW Australia 2075  
*Email: rsacks@commander360.com*

**Rodney J. Schlosser, MD**

Department of Otolaryngology  
 Medical University of South Carolina  
 PO Box 250550  
 135 Rutledge Ave., Suite 1130  
 Charleston, SC 29425  
 USA  
*Email: schlossr@musc.edu*

**John Scianna, MD**

Department of Otolaryngology  
 Loyola University  
 2160 South First Avenue  
 Maywood, IL 60153-3304  
 USA

**Brent A. Senior, MD, FACS**

Department of Otolaryngology – Head and Neck  
 Surgery  
 The University of North Carolina at Chapel Hill  
 G0412 Neurosciences Hospital, CB #7070  
 Chapel Hill, NC 27599  
 USA  
*Email: brent\_senior@med.unc.edu*

**Michael J. Sillers, MD, FACS**

Alabama Nasal and Sinus Center  
 7191 Cahaba Valley Road  
 Birmingham, AL 35242  
 USA  
*Email: michaelsillers@charter.net*

**Timothy L. Smith, MD, MPH**

Oregon Sinus Center  
 Department of Otolaryngology/Head and Neck Surgery  
 Oregon Health and Science University (OHSU)  
 3181 SW Sam Jackson Park Rd., PV-01  
 Portland, OR 97239  
 USA  
*Email: smithtim@ohsu.edu*

**Aldo C. Stamm, MD, PhD**

Director of ENT Sao Paulo Center  
 Rua Alfonso Bras 525 - Cj 13  
 04511-010 Sao Paulo  
 Brazil  
*Email: cof@centrodeorl.com.br*

**James Stankiewicz, MD**

Department of Otolaryngology  
 Loyola University  
 2160 South First Avenue  
 Maywood, IL 60153-3304  
 USA  
*Email: jstank@lumc.edu*

**Michael G. Stewart, MD, MPH**

Department of Otorhinolaryngology  
 Weill Cornell Medical College  
 1305 York Avenue, 5th Floor  
 New York, NY 10021  
 USA  
*Email: mgs2002@med.cornell.edu*

**Abtin Tabaee, MD**

10 Union Square East  
 Suite 4J  
 New York  
 USA  
*Email: atabaee@hotmail.com*

**Marc A. Tewfik, MD**

Montreal General Hospital, Room A2-141  
 1650 Cedar Avenue  
 H3G 1A4 Montreal, Quebec  
 Canada  
*Email: marc.tewfik@mail.mcgill.ca*

**Winston C. Vaughan, MD**

Stanford Sinus Center  
 Stanford University  
 R-135 Edwards Building  
 300 Pasteur Drive  
 Stanford, CA 94305  
 USA  
*Email: sinusmd@aol.com*

**Mark C. Weissler, MD, FACS**

University of North Carolina  
 G0412 Neurosciences Hospital  
 CB 7070  
 Chapel Hill, NC 27599  
 USA  
*Email: mark\_weissler@med.unc.edu*

**Sarah K. Wise, MD**

Department of Otolaryngology  
 Medical University of South Carolina  
 PO Box 250550  
 135 Rutledge Ave., Suite 1130  
 Charleston, SC 29425  
 USA  
*Email: wisesa@musc.edu*

**Bradford A. Woodworth, MD**

Division of Otolaryngology  
 Department of Surgery  
 University of Alabama – Birmingham  
 BDB 563, 1530 3rd Ave S  
 Birmingham, AL 35294  
 USA  
*Email: bwoodwo@hotmail.com*

# Imaging Anatomy in Revision Sinus Surgery

Ramon E. Figueroa

# 1

## Core Messages

- An intimate knowledge of sinus anatomy and a clear understanding of the baseline postsurgical anatomy are required for safe and effective revision sinus surgery.
- Appropriate utilization of computer-assisted surgical navigation with CT crossregistration improves safety margins on revision sinus surgery.
- Rhinologists should evaluate each side of the face as a completely independent anatomic, functional, and surgical entity.
- Familiarity with anatomic variants in the frontal recess is required for safe anterior skull base and frontal recess surgery.
- Persistent mucosal polypoid changes in a surgical site on follow-up postsurgical computed tomography, retained surgical surfaces (uncinate process, agger nasi, frontal bulla cells), or new bone formation are negative prognostic signs.

## Contents

Introduction	1
Caldwell-Luc and Nasoantral Windows	2
Imaging Anatomy in Post-FESS Ostiomeatal Complex	2
Septoplasty	3
Turbinectomies	3
Uncinectomy and Maxillary Sinus Ostium Opening	4
Internal Ethmoidectomy	5
Frontal Sinus Drainage Surgery	6
Endoscopic Frontal Recess Approach (Draf I Procedure)	7
Endoscopic Frontal Sinusotomy (Draf II Procedure)	7
Median Frontal Drainage (Modified Lothrop Procedure or Draf III)	8
Frontal Sinus Trephination	9
Osteoplastic Flap with Frontal Sinus Obliteration	9
Endoscopic Sphenoidotomy	9
Negative Prognostic Findings Post-FESS	10
Conclusion	10

## Introduction

The resulting imaging anatomy of the paranasal sinuses following initial functional endoscopic sinus surgery (FESS) must be thoroughly evaluated to establish the new postsurgical baseline of the sinonasal anatomy. These postsurgical changes may vary from subtle remodeling of anatomy to extensive resection with loss of sinus landmarks, frequently resulting in widely open sinus spaces into the nasal cavity. The great variability of the postsurgical changes is a reflection of the variety of accepted surgical techniques, the surgeon's perception of the specific problem prior to FESS, and the individualized surgical approach to the resolution of the identified problem. The detailed assessment of the postsurgical changes must emphasize which structures have been resected and which

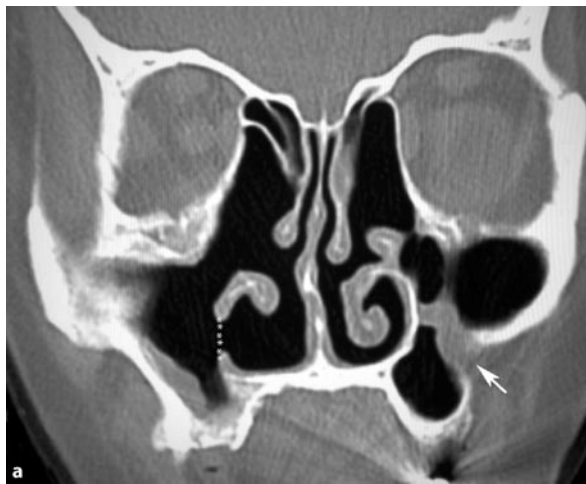anatomy is still intact. In addition, it must identify the presence of any scar tissue formation, retraction of mucosal surfaces, and unresolved sinus drainage issues. In cases where revision surgery is needed to solve persistent sinus obstruction or postsurgical synechia, a detailed presurgical mapping of the anatomy must be performed with emphasis on the identification of endoscopic landmarks related to the anatomic surgical targets, especially if the surgical target is close to the lamina papyracea, cribriform plate, or sphenoid sinus walls.

The recent introduction of multidetector helical scanning with its seamless high-resolution imaging databases and the wide availability of computer-assisted surgical navigation workstations allow today a real-time mapping of the progress through the surgical procedure, even in postsurgical fields devoid of residual endoscopic anatomic

landmarks. The combination of improved imaging clarity from surgical navigation with computed tomography (CT) crossregistration and recent development of new powered instruments and modern endoscopic devices is effectively extending the surgical safety margin, allowing the rhinologist to solve more complex sinonasal and skull-base problems.

### Caldwell-Luc and Nasoantral Windows

The Caldwell-Luc operation, named after the American physician George Caldwell and the French laryngologist Henry Luc, was first described in the late nineteenth century as a surgical decompressive technique to remove diseased mucosa from the maxillary sinus, be it infectious or tumor [1]. The procedure is performed via direct trocar puncture through the anterior maxilla above the second molar tooth, allowing for initial decompression of the maxillary disease, followed by the opening of a nasoantral window at the inferior meatus to connect the maxillary sinus lumen to the nasal cavity. This procedure is recognized on sinus CT by the associated focal defect of the anterior maxillary wall above the alveolar process and the opening within the inferior meatus into the lumen of the maxillary sinus (Fig. 1.1). This operation, which has been used widely over the last century, is being performed with less frequency today, having been replaced by the more physiologic endoscopic middle meatal antrostomy. Still, this surgery is considered safe and effective when removal of all of the diseased maxillary sinus mucosa is desired.



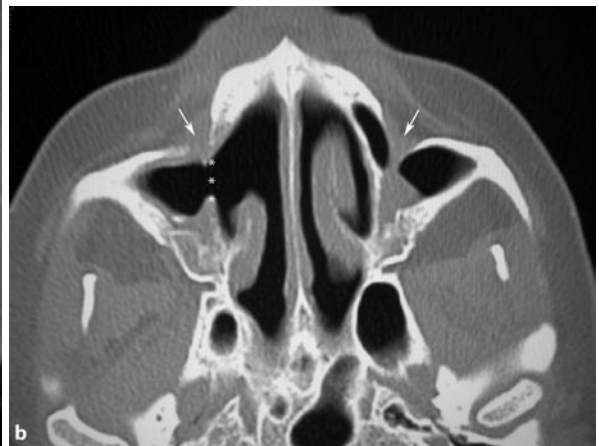
**Fig. 1.1a,b** Caldwell-Luc procedure. Coronal and axial computed tomography (CT) images at the level of the maxillary sinuses, showing bilateral anterior maxillary sinus-wall defects (*arrows* in

### Imaging Anatomy in Post-FESS Ostiomeatal Complex

The postsurgical CT anatomy of the ostiomeatal complex will reflect the presurgical anatomic problems leading to surgery combined with the surgical management chosen by the surgeon to address the patient's clinical problem. An almost infinite variety of surgical changes result from the appropriately tailored surgical approach selected by experienced rhinologists, who must carefully individualize the extent of the procedure to the specific patient's problem (Fig. 1.2). These surgical changes, alone or in combinations, may include septoplasty, turbinate remodeling/resection, uncinectomy, middle meatal antrostomy, internal ethmoidectomy, sphenoidotomy, and/or frontal recess/frontal bulla cell/agger nasi decompression [2, 3].

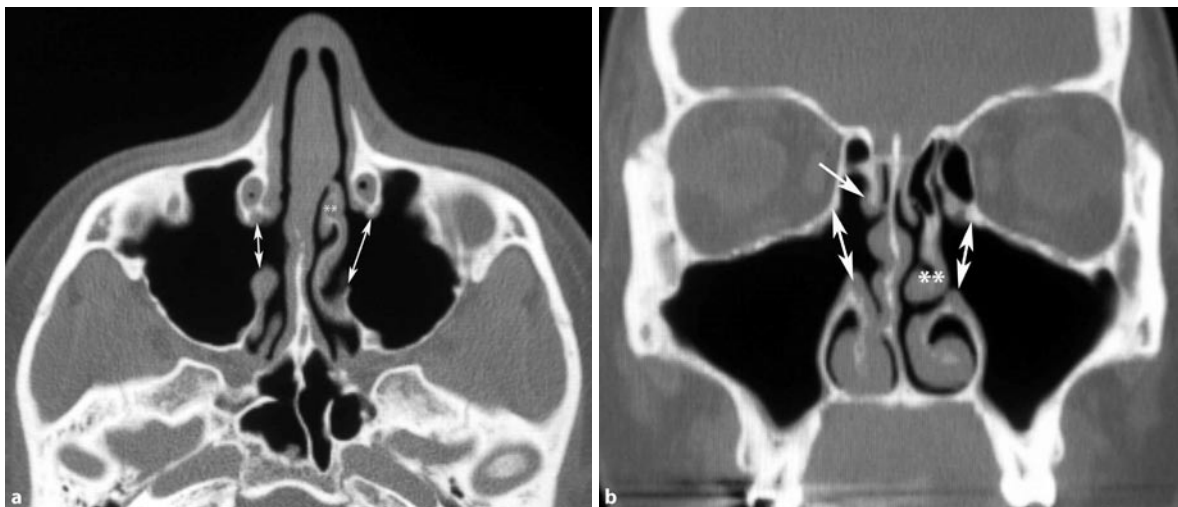
- The first step in a comprehensive evaluation of a postsurgical nasal cavity is to determine which structures have been previously resected and which structures remain, thus establishing the new anatomic baseline of the nasal cavity.
- The second step in this evaluation is to determine the relationship between the postsurgical changes and the patient's current symptoms.
- The third and final step is to review the danger zones of the nasal cavity in the light of the distorted postsurgical anatomy prior to any revision surgery.

This relationship is inferred by the presence of acute sinus fluid levels, sinus opacity, or persistent sinus mucosal dis-



**a and b**) as a result of Caldwell-Luc surgery, combined with inferior meatal nasoantral windows (*asterisks*). Notice also the right middle meatal antrostomy and right inferior turbinate resection





**Fig. 1.2** a and b Middle meatal antrostomies. There are bilateral middle meatal antrostomies (*double-headed arrows*), with a right-sided middle turbinectomy (*arrow in b*). Notice the com-

plete resection of the uncinate processes and the wide pattern of communication with the middle meatus. There is also a left paradoxical middle turbinate

ease. Soft-tissue density within the surgical ostia is an important postsurgical finding, suggesting the presence of scar tissue formation, polyps and/or hyperplastic mucosal changes, all of which are indistinct by CT findings.

### Septoplasty

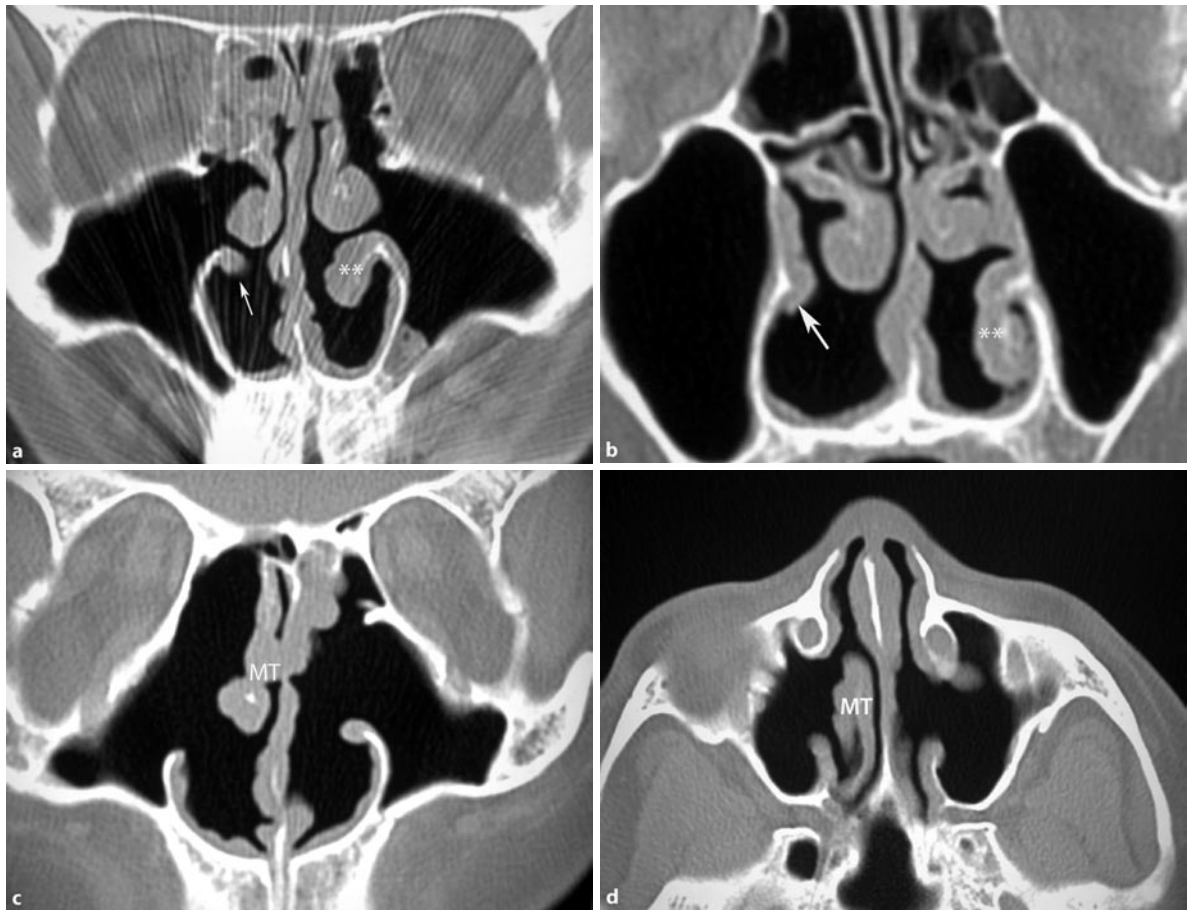Septoplasty is a common adjunct finding in FESS due to the frequency of septal deviations producing asymmetric nasal cavity narrowing, occasionally to the point of laterally deflecting the middle and/or inferior turbinates. After septoplasty, the nasal septum will appear unusually vertical and straight, with a thin mucosa and no apparent nasal spurs. Postsurgical complications such as septal hematomas or septal ischemia may lead to triangular cartilage chondronecrosis, resulting in nasal septal perforations or saddle-nose deformity.

### Turbinectomies

Partial resection of the inferior turbinate is seen frequently in patients with symptoms of chronic nasal congestion and polyposis, with the reduction of turbinate surface increasing meatal diameters, thus increasing the total air volume through the nose. Inferior turbinectomy is recognized on coronal CT as a foreshortened “stumped” inferior turbinate (Fig. 1.3).

Partial or subtotal resection of the middle turbinate may be necessary whenever a concha bullosa or a lateralized middle turbinate is producing a mass effect toward the lateral nasal wall. Whenever truly indicated, middle turbinate surgical remodeling must be carefully performed to the minimal degree that solves the clinical problem, taking into consideration the fact that its mucosa is critical for olfactory function. Its basal lamella is one of the most important surgical landmarks for safe endonasal navigation, maintaining turbinate stability by function of its three-planar attachments (vertical attachment to the cribriform plate, coronal attachment to the lamina papyracea, and axial attachment to the medial maxillary sinus wall at the prechoanal level). The iatrogenic fracture of the middle turbinate vertical attachment is a dreaded complication, resulting in the risks of cerebrospinal fluid fistula at the cribriform plate, floppy middle turbinate behavior, and postsurgical lateralization and scarring. Thus, the resulting postsurgical appearance of the middle turbinate may vary from a barely perceptible thinning of its bulbous portion, to a small residual upper basal lamella stump in cases of subtotal resection.

- Lateralization of the middle turbinate is an important postsurgical finding, since it secondarily narrows the middle meatus, potentiates synechia formation, and predisposes to recurrent obstruction of the underlying drainage pathways by granulation tissue and scarring (Fig. 1.4).



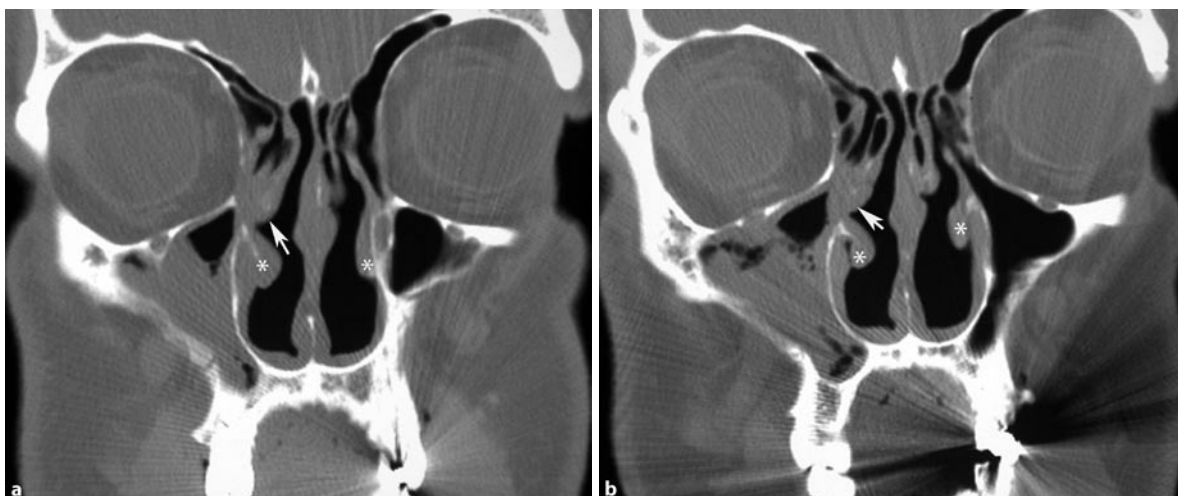**Fig. 1.3a–d** Inferior turbinectomies. **a** Coronal image showing extensive changes as a result of functional endoscopic sinus surgery (FESS), with subtotal right inferior turbinectomy (*arrow*) and partial left inferior turbinectomy (*asterisks*), wide bilateral middle meatal anastomoses, and left internal ethmoidectomies. Note the persistent polypoid mucosal disease in the right ante-

rior ethmoid sinus. **b** Coronal image of the selective right inferior turbinate prechoanal resection (*arrow*) showing prominent widening of the inferior meatal airway. **c,d** A different patient with extensive FESS showing by coronal (**c**) and axial CT (**d**), loss of all lateral wall landmarks bilaterally, except for the right middle turbinate (*MT*)

### Uncinectomy and Maxillary Sinus Ostium Opening

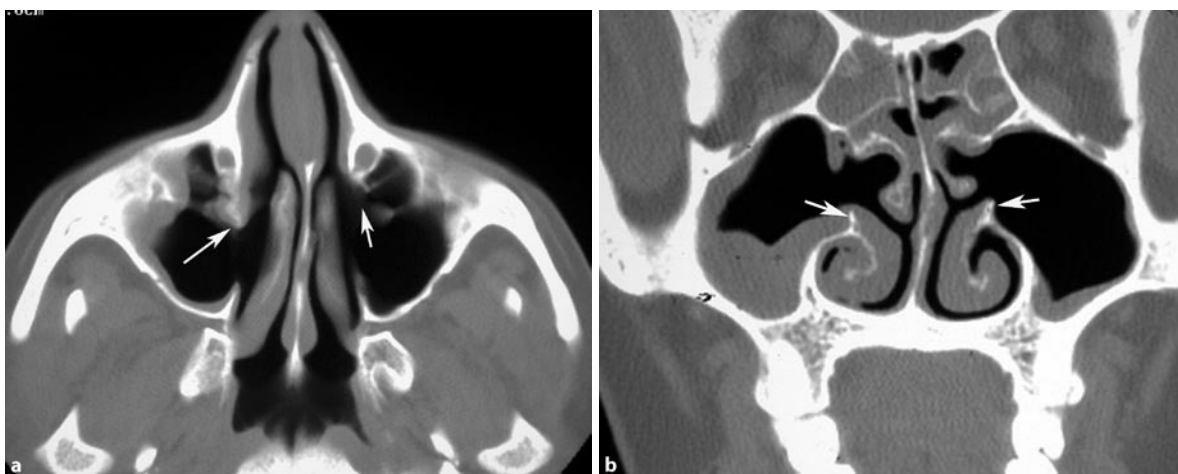
Resection of the uncinete process is an important element in the performance of a functional maxillary sinusotomy. Its incomplete resection is recognized by CT as a visible uncinete process within the surgical field, usually surrounded by soft tissue from a scar/granulation reaction. This granulation and scar, a part of the postsurgical healing response, may contribute to recurrent obstruction at the natural ostium of the maxillary sinus, the ethmoidal infundibulum, or even toward the frontal sinus outflow tract, depending upon where the residual uncinete process is located (Fig. 1.5). Widening of the maxillary sinus ostium is also variable, depending on the uncinete resec-

tion, presence of Haller cells, large bulla ethmoidalis, or the configuration of the adjacent orbital wall. Any soft tissue within the natural ostium of the maxillary sinus or in the ethmoidal infundibulum must be identified due to its potential for impairment of the mucociliary clearance. The presence of a nasoastral window is a good clinical indicator for the surgeon to look for the phenomenon of mucus recirculation, where mucociliary clearance already in the middle meatus may return to the maxillary sinus lumen through a surgical nasoastral window, thus increasing the mucus load and potential for sinus colonization with nasal pathogens. Naturally occurring posterior fontanelles must also be taken into consideration during the planning for revision FESS to avoid mistaking this space endoscopically with the maxillary sinus os-



**Fig. 1.4a,b** Lateralized middle turbinate in a patient 4 months after FESS, with recurrent facial pain and fever. These sequential coronal images show lateralization of the right middle turbinate

(arrow) obstructing the middle meatal antrostomy, already with active mucosal disease in the right maxillary sinus. Note also subtotal resection of both inferior turbinates (asterisk)



**Fig. 1.5a,b** Residual uncinete process. Axial (a) and coronal (b) CT images demonstrate persistent uncinete processes (arrows) bilaterally in spite of previous FESS. Note the persistent active

mucosal thickening in both maxillary sinuses, which is worse on the right side

tium, which would result in a maxillary sinusotomy not bearing mucociliary clearance.

### Internal Ethmoidectomy

The internal ethmoidectomy is an intranasal endoscopic procedure that is performed to manage mucosal disease within the anterior ethmoidal air cells. It requires the ini-

tial resection of the bulla ethmoidalis followed by resection of the ethmoidal cells, located anterior and inferior to the basal lamella of the middle turbinate. If a posterior ethmoidectomy is also needed, the basal lamella of the middle turbinate is then penetrated to decompress the posterior ethmoidal air cells. This approach is also extendable to the sphenoid sinus (transethmoidal sphenoidotomy). An internal ethmoidectomy appears by CT as a wide ethmoidal cavity that is devoid of septations

(Fig. 1.6). It is important that residual opaque ethmoidal air cells are identified, since they may be an indicator for recurrent sinus disease. The presence of mucosal polypoid changes and mucosal congestion within any residual ethmoidal cells is also a concern as they obscure the underlying anatomic landmarks that are necessary for safe surgery near the skull base.

### Frontal Sinus Drainage Surgery

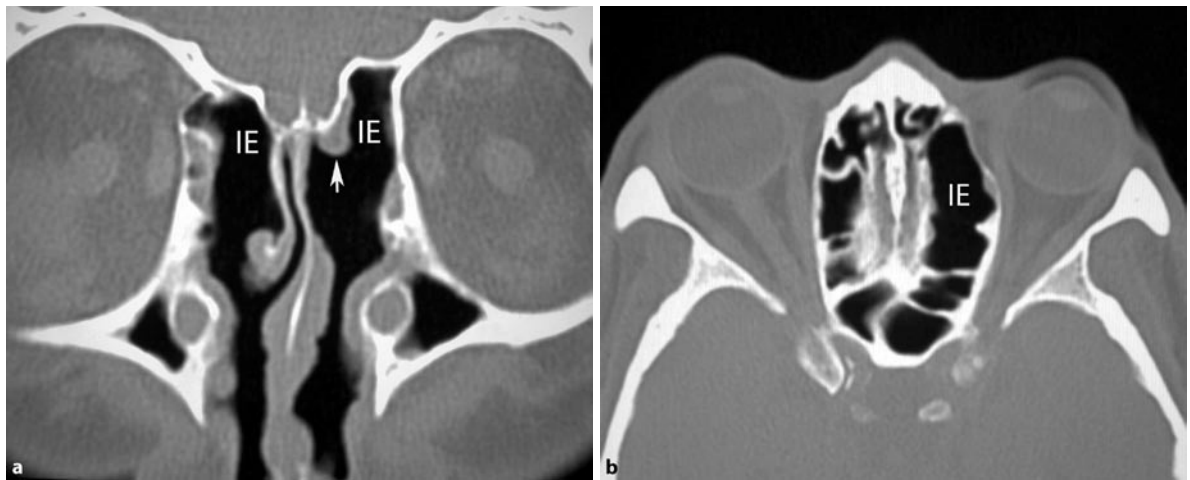
The frontal sinus drainage pathway is one of the most complex anatomic areas of the skull base. Its drainage pathways, the frontal sinus ostium and the frontal recess, are modified, shifted, and narrowed by the pneumatized agger nasi, anterior ethmoid cells, frontal cells, supraorbital ethmoid cells, and the surrounding anatomic structures (vertical insertion of the uncinat process and bulla lamella) [4]. The complexity of the frontal sinus variable drainage pathway starts at the frontal sinus ostium, which is oriented nearly perpendicular to the posterior sinus wall, indented anteriorly by the nasal beak. Its caliber is modified by the presence and size of pneumatized agger nasi and/or frontal cells. When markedly pneumatized, agger nasi cells can cause obstruction of the frontal sinus drainage pathway and thus have surgical implications. A second group of frontal recess cells, the frontal cells, are superior to the agger nasi cells. Bent and Kuhn described the frontal cells grouping them into four patterns [5]:

1. Type 1: a single cell above the agger nasi.
2. Type 2: a tier of two or more cells above the agger cell.

3. Type 3: a single cell extending from the agger cell into the frontal sinus.
4. Type 4: an isolated cell within the frontal sinus.

The frontal sinus ostium may also be narrowed by supraorbital ethmoid cells arising posterior to the frontal sinus and pneumatizing the orbital plate of the frontal bone. The frontal sinus ostium communicates directly with the frontal recess inferiorly, a narrow passageway bounded anteriorly by the agger nasi, laterally by the orbit, and medially by the middle turbinate. The posterior limit of the frontal recess varies depending upon the ethmoid bulla or bulla lamella, reaching to the skull base. When the bulla lamella reaches the skull base, it provides a posterior wall to the frontal recess. When the bulla lamella fails to reach the skull base, the frontal recess communicates posteriorly, directly with the suprabullar recess, and the anterior ethmoidal artery may become its only discrete posterior margin. The frontal recess opens inferiorly to either the ethmoid infundibulum or the middle meatus depending on the uncinat process configuration. When the anterior portion of the uncinat process attaches to the skull base, the frontal recess opens to the ethmoid infundibulum, and from there to the middle meatus via the hiatus semilunaris. When the uncinat process attaches to the lamina papyracea instead of the skull base, the frontal recess opens directly to the middle meatus [6].

- Each pneumatized sinus space grows independently, with its rate of growth, final volume, and configuration being determined by its ventilation, drainage, and the



**Fig. 1.6a,b** Internal ethmoidectomy. **a** Coronal image showing bilateral internal ethmoidectomies (*IE*) and left middle turbinate resection (*arrow*). **b** Axial image at the level of the orbit shows

the asymmetric lack of internal septations in the left ethmoid labyrinth internal ethmoidectomy

corresponding growth (or lack of it) of the competing surrounding sinuses and skull base.

This independent and competing nature of the structures surrounding the frontal recess adds an additional dimension of complexity to the frontal sinus drainage pathway. It is thus understandable why chronic frontal sinusitis secondary to impaired frontal recess drainage is so difficult to manage surgically, as reflected by the wide range of surgical procedures devised for frontal sinus decompression over the years. The spectrum of treatment options ranges from surgical ostiomeatal complex decompression combined with conservative long-term medical management, to endoscopic frontal recess exploration, the more recent endoscopic frontal sinus modified Lothrop procedure, external frontal sinusotomy, osteoplastic fat obliteration, or multiple variations of all of these [7].

Most endoscopic frontal sinus procedures are performed in patients who had previous ostiomeatal complex surgery in whom long-term conservative medical management failed. In these patients, it is not uncommon to find frontal recess scarring, osteoneogenesis, and incompletely resected anatomic variants, particularly incomplete removal of obstructing agger nasi cells and/or frontal cells leading to chronic frontal sinusitis (Fig. 1.7). Modern endoscopic surgical techniques and instruments, combined with image-guided three-dimensional navigation techniques have resulted in increased endoscopic management of most frontal sinus pathology. Endoscopic approaches tend to preserve the sinus mucosa, with less scar tissue than external approaches, resulting in

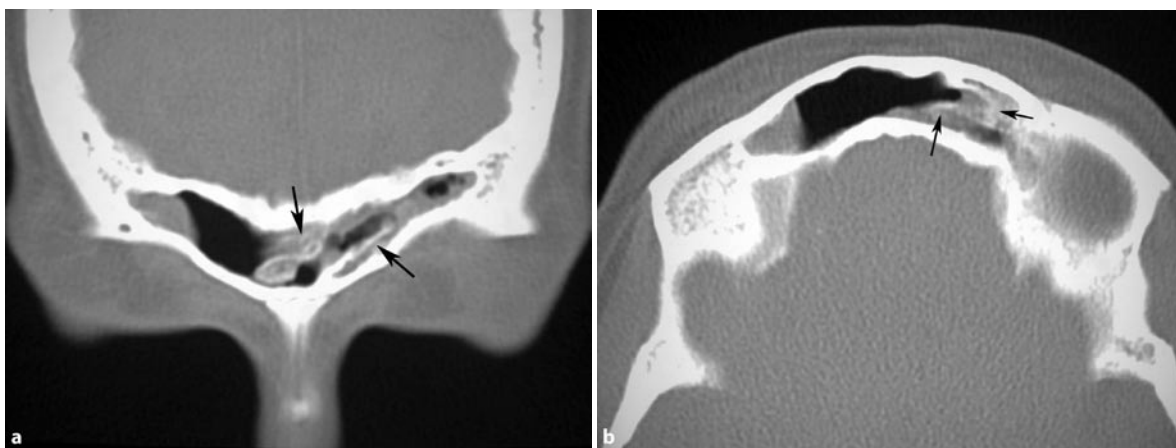
less mucosal shrinkage and secondary obstruction. If the endoscopic approach fails to provide long-term drainage of the frontal sinus, then an external approach with obliteration of the frontal sinus still remains as a viable surgical alternative.

#### Endoscopic Frontal Recess Approach (Draf I Procedure)

Dr. Wolfgang Draf popularized a progressive three-stage endoscopic approach to the management of chronic frontal sinus drainage problems for patients in whom classic ostiomeatal endoscopic sinus surgery is unsuccessful [8]. The Draf type I procedure, or endoscopic frontal recess approach, is indicated when frontal sinus disease persists in spite of more conservative ostiomeatal and anterior ethmoid endoscopic approaches. The Draf I procedure involves complete removal of the anterior ethmoid cells and the unciniate process up to the frontal sinus ostium, including the removal of any frontal cells or other obstructing structures to assure the patency of the frontal sinus ostium.

#### Endoscopic Frontal Sinusotomy (Draf II Procedure)

The endoscopic frontal sinusotomy, or Draf II procedure, is performed in severe forms of chronic frontal sinusitis for which the endoscopic frontal recess approach was un-



**Fig. 1.7a,b** Postinflammatory osteoneogenesis. Coronal (a) and axial (b) sinus CT sections at the level of the frontal sinuses show osteoneogenesis with persistent frontal sinus inflammatory mucosal engorgement (*black arrows*)

1 successful. The previous endoscopic drainage procedure is extended by resecting the frontal sinus floor from the nasal septum to the lamina papyracea. The dissection also removes the anterior face of the frontal recess to enlarge the frontal sinus ostium to its maximum dimension. The Draf II procedure looks very similar to the Draf I procedure on coronal images, requiring the evaluation of sequential axial or sagittal images to allow the extensive removal of the anterior face of the frontal recess and the frontal sinus floor. Endoscopic frontal sinusotomy (Draf II) procedure can also be easily distinguished from the Draf III procedure (see below) by the lack of resection of the superior nasal septum and the entire frontal sinus floor.

### Median Frontal Drainage (Modified Lothrop Procedure or Draf III)

The modified Lothrop procedure, or Draf III procedure, first described in the mid-1990s, is indicated for the most severe forms of chronic frontal sinusitis, where the only other choice is an osteoplastic flap with frontal sinus obliteration. This procedure involves the removal of the inferior portion of the interfrontal septum, the superior part of the nasal septum, and both frontal sinus floors. The lamina papyracea and posterior walls of each frontal sinus remain intact. This procedure results in a wide opening into both frontal sinuses (Fig. 1.8).

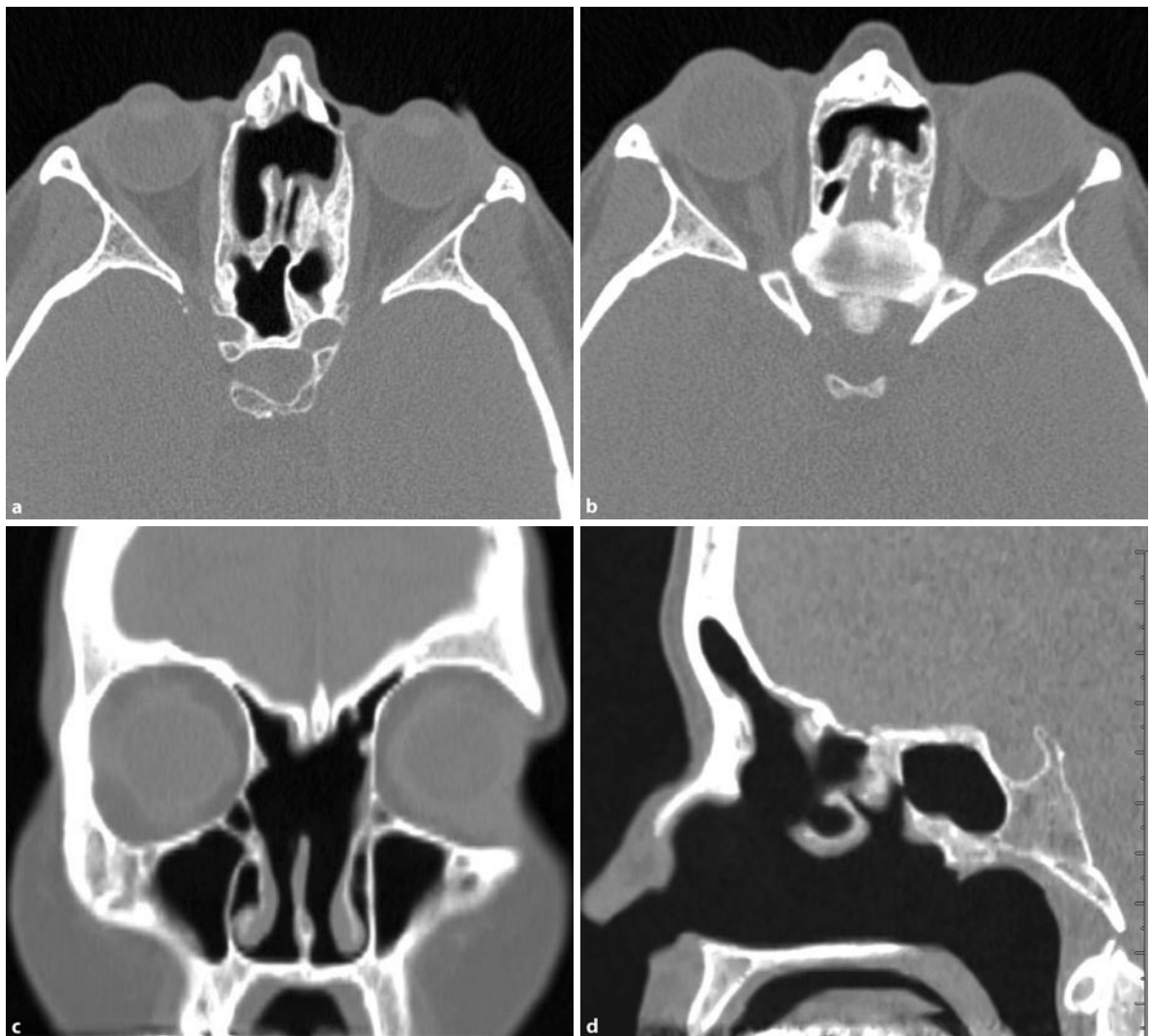


Fig. 1.8a–d Draf III (modified Lothrop) procedure. Axial (a,b) coronal (c), and sagittal CT images

- The surgical defect component in the superior nasal septum after a Draf III procedure should not be mistaken for an unintended postoperative septal perforation.

### Frontal Sinus Trephination

The trephination procedure is a limited external approach for frontal sinus drainage. An incision is made above the brow and a hole is drilled through the anterior wall of the frontal sinus taking care to avoid the supratrochlear and supraorbital neurovascular bundles (see Chap. 33). The inferior wall of the frontal sinus is devoid of bone marrow, which may lessen the risk of developing osteomyelitis. Frontal sinus trephination is indicated in complicated acute frontal sinusitis to allow the release of pus and irrigation of the sinus to prevent impending intracranial complications. It can also be used in conjunction with endoscopic approaches to the frontal sinus in chronic frontal sinusitis or frontal sinus mucoceles, where the trephination helps to identify the frontal recess by passing a catheter down the frontal recess, also allowing it to be stented and to prevent its stenosis. This approach provides fast and easy access to the frontal sinus to place an irrigation drain in the sinus. Its main disadvantages are the risks of associated scarring, sinocutaneous fistula formation, and injury to the supraorbital nerve bundle and the trochlea, which can cause diplopia [9]. Image guidance is critical for accurate trephine placement in particularly small frontal sinuses or to gain access to isolated type 4 frontal sinus disease.

### Osteoplastic Flap with Frontal Sinus Obliteration

- Long-term stability of the mucociliary clearance of the frontal sinus must be maintained for endoscopic surgery of the frontal sinus to be successful. If this is not achieved, an osteoplastic flap procedure with sinus obliteration may be the only remaining option.

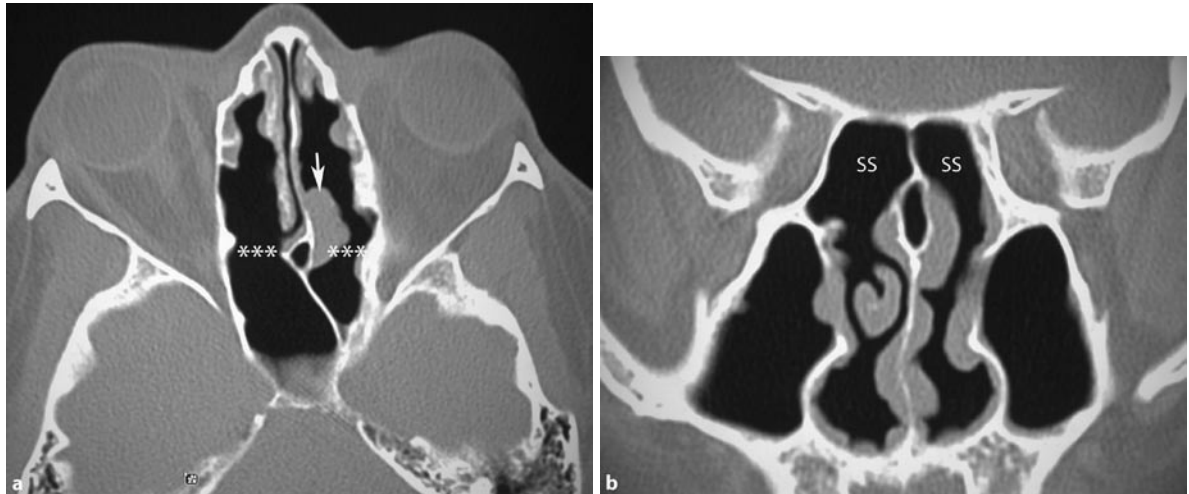
The indications for this procedure include chronic frontal sinusitis in spite of prior endoscopic surgery, mucocele, frontal bone trauma with fractures involving the drainage pathways, and resection of frontal tumors near the frontal recess. The outline of the sinus can be determined by using a cut template made from a 6-foot (1.83 m) Caldwell x-ray, which approaches the exact size of the frontal sinus. Other methods include the use of a wire thorough an image-guidance-placed frontal sinus trephination to palpate the extent of the sinus. Beveled

osteotomy cuts through the frontal bone prevent collapse of the anterior table into the sinus lumen upon postoperative closure. Frontal sinus obliteration requires all of the mucosa to be drill-removed and the frontal recess occluded. The sinus is then packed with fat, bone marrow, pericranial flaps, or synthetic materials, and then the bony flap is replaced.

The postoperative imaging appearance by CT and/or magnetic resonance imaging (MRI) is highly variable due to the spectrum of tissues used for sinus packing, with imaging behavior reflecting fat, chronic inflammatory changes, retained secretions, granulation tissue, and fibrosis. MRI may be of limited utility in distinguishing symptomatic patients with recurrent disease from asymptomatic patients with imaging findings related to scar tissue. Imaging is useful for the early detection of postoperative mucocele formation, which is recognized by its mass effect and signal behavior of inspissated secretions [10, 11].

### Endoscopic Sphenoidotomy

The postsurgical appearance of the sphenoidal recess following endoscopic sphenoidotomy varies depending upon whether the sphenoidotomy was transnasal, transthemoidal, or transeptal. Transnasal sphenoidotomy may be performed as a selective procedure, where the only subtle finding may be a selective expansion of the sphenoid sinus ostium in the sphenoidal recess. Transthemoidal sphenoidotomies, on the other hand, are performed in the realm of a complete functional endoscopic surgery, where middle meatal antrostomy changes, internal ethmoidectomy changes, and sphenoid sinus rostrum defects ipsilateral to the ethmoidectomy defects become parts of the imaging constellation (Fig. 1.9). Finally, transeptal sphenoidotomy changes are a combination of septal remodeling with occasional residual septal split appearance combined with a midline sphenoid rostrum defect and variable resection of the sphenoid intersinus septum. These changes are seen typically in the realm of more extensive sphenoid sinus explorations or surgical exposures for transsphenoidal pituitary surgery. The accurate imaging identification of the optic nerves, internal carotid arteries, maxillary division of the trigeminal nerve, and the vidian neurovascular package in reference to the pneumatized sphenoid sinus is even more important in postsurgical sphenoid re-exploration, since the usual anatomic and endoscopic sinus appearance may be significantly distorted by previous procedures, postsurgical scar and/or persistent inflammatory changes. Imaging guidance is thus critical for the safe and accurate depiction of all of neighboring structures of the sphenoid sinus.



**Fig. 1.9a,b** Sphenoidotomy. **a** Axial CT showing bilateral internal ethmoidectomies and transthemoidal sphenoidotomies (*asterisks*). Note the persistent polypoid disease (*arrow*) in the left posterior ethmoid sinus. **b** Coronal CT at the level

of the rostrum of the sphenoid showing open communication into the sphenoid sinus (SS), with no residual sphenothmoid recess components. Note the absent left-middle and bilateral inferior turbinates from prior turbinectomies

### Negative Prognostic Findings Post-FESS

There is a series of postsurgical imaging findings that imply a persistent underlying physiologic problem, with poor prognostic implications for recurrence of sinus disease. These CT findings may include a wide range of elements, such as incomplete resection of surgical structures (especially uncinata process, agger nasi, or frontal bulla cells), mucosal nodular changes at areas of prior surgical manipulation (mucosal stripping, granulation tissue, mucosal scarring, synechia formation, polyposis), or postinflammatory increased bone formation (osteoneogenesis). All of these changes should be detectable in a good-quality postsurgical sinus CT, which should be performed ideally at least 8 weeks after the surgical trauma to allow for reversible inflammatory changes to resolve. These changes result in recurrent or persistent obstruction of the mucociliary drainage at the affected points, with increased potential for recurrent symptoms. Persistent nasal septal deviation leading to a narrowed nasal cavity and lateralization of the middle turbinate against the lateral nasal wall are two additional factors with poor prognostic implications for recurrent sinus disease. The relevance of these CT findings must be judged by the rhinologist based on the presence of mucosal congestion and/or fluid accumulation in the affected sinus space in combination with assessment of the patient's clinical behavior (persistent sinus pressure, pain and/or fever).

### Conclusion

The postsurgical anatomy of the paranasal sinus drainage pathways and their surrounding structures must be evaluated in an integrated fashion, emphasizing the interrelationship between sinus anatomy and function. The presence of residual surgical structures, mucosal nodular changes at areas of prior surgical manipulation or postinflammatory new bone formation are poor prognostic factors for recurrent postsurgical sinus disease.

### References

1. KE Matheny, JA Duncavage (2003) Contemporary indications for the Caldwell-Luc procedure. *Curr Opin Otolaryngol Head Neck Surg* 11:23–26
2. Stammberger HR, Kennedy DW, Bolger WE, et al. (1995) Paranasal sinuses: anatomic terminology and nomenclature. *Ann Rhinol Otol Laryngol (Suppl)* 167:7–16
3. Kayalioglu G, Oyar O, Govsa F (2000) Nasal cavity and paranasal sinus bony variations: a computed tomographic study. *Rhinology* 38:108–113
4. Daniels DL, Mafee MF, Smith MM, et al. (2003) The frontal sinus drainage pathway and related structures. *AJNR Am J Neuroradiol* 24:1618–1626
5. Bent JP, Cuiltly-Siller C, Kuhn FH (1994) The frontal cell as a cause of frontal sinus obstruction. *Am J Rhinol* 8:185–191



6. Perez P, Sabate J, Carmona A, et al. (2000) Anatomical variations in the human paranasal sinus region studied by CT. *J Anat* 197:221–227
7. Benoit CM, Duncavage JA (2001) Combined external and endoscopic frontal sinusotomy with stent placement: a retrospective review; *Laryngoscope* 111:1246–1249
8. Draf W (1991) Endonasal micro-endoscopic frontal sinus surgery: the Fulda concept. *Operative Tech Otolaryngol Head Neck Surg* 4:234–240
9. Lewis D, Busaba N (2006) *Surgical Management: Sinusitis*; Taylor and Francis Group, Boca Raton, Florida, pp 257–264
10. Melhelm ER, Oliverio PJ, Benson ML, et al. (1996) Optimal CT evaluation for functional endoscopic sinus surgery. *AJNR Am J Neuroradiol* 17:181–188
11. Weber R, Draf W, Keerl R, et al. (2000) Osteoplastic frontal sinus surgery with fat obliteration: technique and long-term results using magnetic resonance imaging in 82 operations. *Laryngoscope* 110:1037–1044

# Indications for Revision Endoscopic Sinus Surgery

Marc A. Tewfik and Martin Desrosiers

## Core Messages

- The goal of assessment of the patient with symptoms suggestive of persistent or recurrent sinus disease is to identify the presence of technical, mucosal, and systemic factors contributing to poor outcome by using appropriate investigations.
- The goal of surgery is to improve medical management by reducing disease load and improving access for continuing medical care for those with severe mucosal disease.
- Indications for revision endoscopic sinus surgery can be categorized as follows: (i) incomplete previous surgery, (ii) complications of previous surgery, (iii) recurrent or persistent sinus disease, and (iv) histological evidence of neoplasia. These criteria are not absolute and the decision to reoperate is most often based on clinician judgment and experience.
- The most common technical factors associated with failure of primary surgery are: (i) middle-meatal scarring and lateralization of the middle turbinate, and (ii) frontal sinus obstruction from retained agger nasi or anterior ethmoid cells. These common situations must be actively sought out with endoscopy and radiologic imaging.
- Given the multiple factors that contribute to the persistence of disease, combinations of both medical therapy and surgery may play a role in the continuum of management as the patient's disease condition evolves over time.
- The patient should be informed that further surgery may be necessary in the future.

## Contents

Introduction .....	13
Indications for Surgery .....	14
Incomplete Previous Surgery .....	14
Complications of Previous Surgery .....	15
Recurrent or Persistent Sinus Disease .....	15
Histological Evidence of Neoplasia .....	16
Preoperative Workup .....	16
Assessment of the Patient with Post-ESS Symptoms .....	16
Imaging Studies .....	16
The Role of Image-Guided Surgery .....	17
Other Causes .....	17
Surgery .....	17

## Introduction

The management of chronic rhinosinusitis (CRS) can be quite challenging, even to the experienced rhinologist. This is particularly true for severe CRS that has not responded to an initial surgical attempt (refractory CRS). Revision surgery may have a role in the continuum of management of the patient's disease condition; however, the clinician should understand that different care may be required at different time points, depending on the underlying factors contributing to sinus disease.

The decision to reoperate on a patient with sinus disease is centered principally on the demonstration of a symptomatic obstruction to sinus drainage or the presence of significant disease load in the sinuses. This must be tempered by the clinician's judgment, experience, and comfort level. Given the nature of endoscopic sinus surgery (ESS) and the close proximity of numerous critical structures, special care must be taken to avoid serious intraoperative complications as a result of damage to adjacent structures [8,10,16]. Preoperative sinus imaging and

a precise understanding of the patient's anatomy are thus of paramount importance.

Indications for revision sinus surgery can be grossly divided into four main categories:

1. Incomplete previous surgery.
2. Complications of previous surgery.
3. Recurrent or persistent sinus disease.
4. Histological evidence of neoplasia.

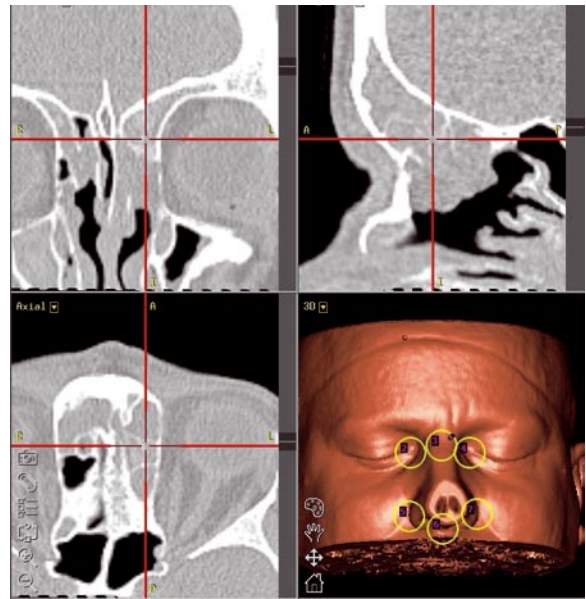
The first occurs when prior surgery has been incomplete. Such is the case when there is refractory CRS or recurrent acute sinusitis with persistence of ethmoid cells, or a deviated nasal septum not adequately repaired and causing obstruction to access or drainage. Incompletely resected cells can be identified by their typical appearance and position. Often, the agger nasi and anterior ethmoid cells have been left in place while surgery clears a straight-line back through the posterior ethmoids up to the skull base (Fig. 2.1). Unopened infraorbital ethmoid (Haller) cells can obstruct maxillary sinus outflow. The "missed ostium sequence," as described by Parsons et al. [13], occurs when there is incomplete removal of the most anterior portion of the uncinate process, thus obscuring the position of the natural maxillary sinus ostium. This prevents the middle meatal antrostomy from communicating with the natural ostium, resulting in a recirculation phenomenon. In this instance, mucociliary flow causes mucus to re-enter the sinus, causing a functional obstruction of the maxillary sinus and continued sinus disease.

Several series have looked at the causes of postsurgical persistent or recurrent disease, and provide information regarding the frequency of various anatomic findings. Chu et al. [7] evaluated 153 patients requiring revision ESS, and found that the most common surgical alteration associated with recurrent sinus disease was middle-meatal scarring and lateralization of the middle turbinate. This was usually the result of partial middle turbinectomy during the initial surgery.

Musy and Kountakis [11] reported that the most common postsurgical findings associated with primary surgery failure are:

1. Lateralization of the middle turbinate (78%).
2. Incomplete anterior ethmoidectomy (64%).
3. Scarred frontal recess (50%).
4. Retained agger nasi cell (49%).
5. Incomplete posterior ethmoidectomy (41%).
6. Retained uncinate process (37%).
7. Middle meatal antrostomy stenosis (39%).
8. Recurrent polypsis (37%).

Ramadan [14] reviewed 52 cases and found that the most common cause of failure was residual air cells and adhesions in the ethmoid area (31%), followed by maxillary



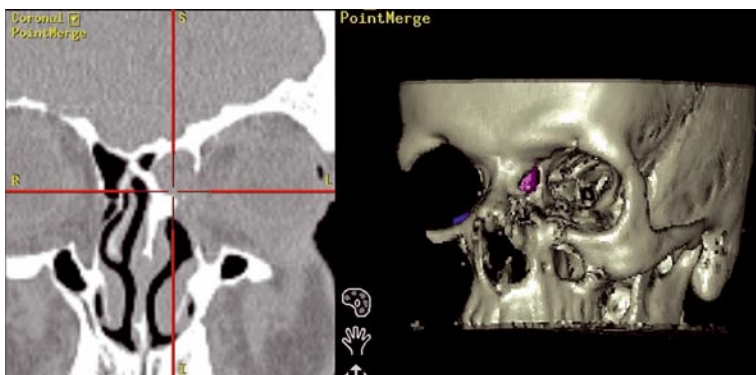
**Fig. 2.1** Symptomatic frontal sinus obstruction. Screen shot from a computer-assisted navigation system demonstrating frontal sinus obstruction in three planes on computed tomography (CT). Persistent agger nasi cells and anterior ethmoid cells responsible for obstruction are best identified on a sagittal view (*top right*)

sinus ostial stenosis (27%), frontal sinus ostial stenosis (25%), and a separate maxillary sinus ostium stenosis (15%). In their series of 67 patients requiring revision frontal sinus surgery, Chiu and Vaughn [6] identified residual agger nasi cell or ethmoid bulla remnants in 79.1% of cases, retained uncinate process in 38.8%, lateralized middle turbinate remnant in 35.8%, recurrent polypsis in 29.9%, unopened frontal recess cells in 11.9%, and neo-osteogenesis of the frontal recess in 4.5%. A maxim to guide the surgeon is that the patient can never truly be deemed a failure of therapy until all obstructions to drainage and ventilation (or irrigation) are corrected.

## Indications for Surgery

### Incomplete Previous Surgery

1. Persistence of symptoms and signs of CRS with or without nasal polyposis or recurrent acute sinusitis with persistent ethmoid cells on computed tomography (CT).
2. Deviated nasal septum not adequately repaired at primary surgery and causing obstruction.



**Fig. 2.2** Mucocele. Left frontal sinus mucocele presenting as a painless left exophthalmos. Note the circular, sphere-like form typical of mucocoeles. A three-dimensional, computer-generated illustration of the lesion is also shown (*right*)

3. Persistent maxillary sinus disease in the setting of a retained uncinete process.

### Complications of Previous Surgery

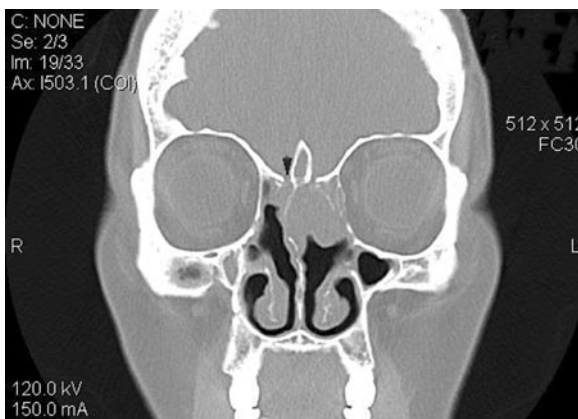
Complications of prior ESS constitute the second major group of indications for surgical revision. These include:

1. Suspected mucocele formation.
2. Suspected cerebrospinal fluid (CSF) leak for which conservative management was unsuccessful.
3. Synechiae causing obstruction of the nasal passage or sinus outflow tract.

Due to its narrow anatomic outflow pathway, the frontal sinus is particularly susceptible to this group of complications, and thus is often the target of revision sinus

surgery. A mucocele can be suspected on CT when there is smooth, round enlargement of a completely opacified sinus cell with associated bony remodeling and thinning (Fig. 2.2). It is useful to follow a graded approach to the frontal sinus; a discussion of frontal sinus techniques is presented later on.

The surgeon should always be alert to the risk of pre-existing CSF leaks, which may have gone unnoticed during previous surgery. A significant proportion of CSF leaks are iatrogenic in origin. They occur most commonly in the areas of the olfactory fossa and fovea ethmoidalis (Fig. 2.3). The skull-base bone in these areas can be extremely thin, and may be penetrated by direct instrumentation or cauterization for control of bleeding [15]. In some cases, bony remodeling expose the once-protected vital structures to trauma during surgery.



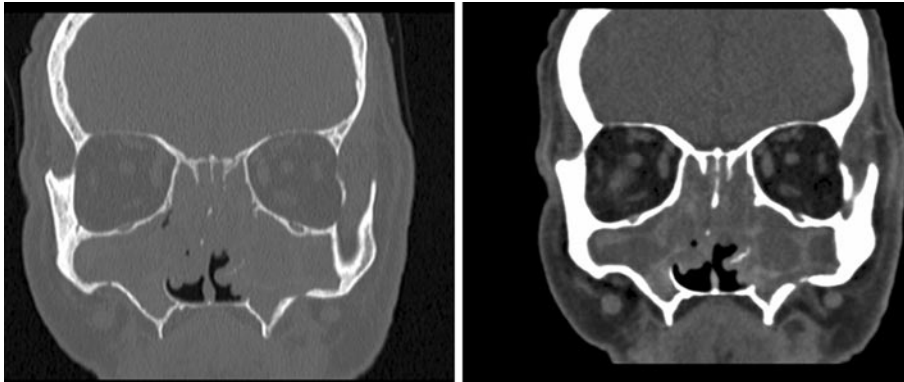
**Fig. 2.3** Cerebrospinal fluid leak. Coronal CT demonstrating a possible skull-base defect (*arrowhead*), which proved to be a pre-existing trauma at the time of surgery

### Recurrent or Persistent Sinus Disease

Recalcitrant inflammatory sinus disease is the third category of indications for revision ESS. This includes:

1. Recurrent acute sinusitis.
2. CRS with or without nasal polyps.
3. Allergic fungal rhinosinusitis (Fig. 2.4).

Another indication included in this category is in the management of patients with nasal polyposis who have an intolerance or contraindication to oral corticosteroids. It remains, as a whole, a poorly understood group of diseases. Considerable research efforts are currently focused on improving the management of these difficult patients. Although discussions of these entities and of medical management are presented in depth in later chapters, a guiding principal is that an adequate trial of maximal medical therapy must be attempted preoperatively and documented in the chart.



**Fig. 2.4** Allergic fungal rhinosinusitis. Involvement of all of the sinus cavities is shown on CT in the bone window (*left*); examination in the soft-tissue window (*right*) shows evidence of allergic fungal sinusitis/eosinophilic mucinous rhinosinusitis in all sinuses

### Histological Evidence of Neoplasia

1. Unexpected diagnosis of neoplasia on pathological analysis with subtotal resection.
2. Localized severe disease suspicious for neoplasia, such as inverted papilloma.

Once diagnosed, these patients are reoperated for complete removal of the tumor. These most commonly consist of inverted papillomas [12,17,18]; however, they may be any of a variety of benign or malignant nasal or paranasal sinus tumors [2].

### Preoperative Workup

#### Assessment of the Patient with Post-ESS Symptoms

The clinician should attempt to elicit the patient's symptoms and classify them according to their severity. The goal of the medical workup is to identify the mucosal, systemic, and environmental factors responsible for poor outcome. A history of underlying immune deficiency, connective tissue disorder, malignancies, or genetic disorder such as cystic fibrosis or primary ciliary dyskinesia should be sought. A complete immune workup, and possibly a vaccine response, should be ordered to rule out immune deficiency if it is suspected. Blood work is also helpful to rule out other systemic disorders such as Wegener's granulomatosis and sarcoidosis. Defects in functional immune response not evident in static testing have been identified in certain patients who have refractory CRS. In the absence of a response to all other therapies, a 6-month trial of intravenous immunoglobulin may be

warranted [5]. This option should be discussed with the patient before administration.

It is important to consider the potential contribution of allergy to symptoms or disease, as a significantly higher percentage of these patients will have allergies as compared to the general population. A total serum IgE level, as well as a hemogram with differential cell count to detect serum eosinophilia, may be useful to further characterize patients. Allergy testing and management should be included in their care to minimize the contribution of allergy to the disorder. Allergen reduction or avoidance, medications, and possibly immunotherapy may play a role in management.

Cigarette smoking has been associated with statistically worse outcomes after ESS based on disease-specific quality-of-life measures [4].

Sinonasal endoscopy, preferably rigid, is essential in evaluating persistent disease. It may help identify structural anomalies, masses, or secretions not seen on anterior rhinoscopy. The bacteriology of CRS may vary in an individual patient over time. Obtaining endoscopically guided cultures from the middle meatus or the sphenoidal recess (not the nasal cavity) will help in the selection of antibiotic therapy, particularly in cases that are unresponsive to empiric therapy. Care must be taken to avoid contact with the nasal wall or vestibule to minimize contamination, and to sample directly within purulent secretions when present, rather than adjacent areas.

### Imaging Studies

CT of the sinuses is essential for completing the assessment of the patient with persistent post-ESS complaints. CT may be used to assess disease load or to identify tech-

nical factors that may not be revealed on endoscopy, such as residual ethmoid cells, obstructions to sinus drainage, or mucocele formation. Disease load can be determined by identifying the number of sinuses involved with disease and the extent of their involvement (mucosal thickening vs. opacification). The Lund-MacKay staging system is an effective method of standardizing reporting of radiologic severity of disease [3,9]. Care must be exercised in the face of exuberant local disease out of proportion to the rest of the sinus cavities to ensure against a missed diagnosis of neoplasm such as inverted papilloma.

When frontal sinus involvement is suspected, helical CT with three-dimensional reconstruction is needed for analysis of the anatomy of the frontal recess. Frontal sinus opacification is often noted on CT. However, this radiologic finding also needs to be assessed in terms of clinical context by assessing the patient's symptoms. For example, it is not unusual in extensive sinonasal polyposis for patients to demonstrate a significant amount of frontal sinus involvement. Thus, in patients with nasal polyposis, frontal sinus opacification in the absence of frontal symptoms or bony remodeling is not in and of itself an indication for revision.

### The Role of Image-Guided Surgery

When ordering imaging studies, consideration should be given to the possibility of image-guided surgery as part of the initial evaluation of the potential surgical patient. The rationale for this is that normal anatomy is invariably altered in previously operated patients, and the usual anatomic landmarks – including the middle turbinate, uncinate process, and basal lamella – may have been removed. Formal indications for computer-aided surgery endorsed by the American Academy of Otolaryngology – Head and Neck Surgery are [1]:

1. Revision sinus surgery.
2. Distorted sinus anatomy of development, postoperative, or traumatic origin.
3. Extensive sinonasal polyposis.
4. Pathology involving the frontal, posterior ethmoid, and sphenoid sinuses.
5. Disease abutting the skull base, orbit, optic nerve, or carotid artery.
6. CSF rhinorrhea or conditions where there is a skull-base defect.
7. Benign and malignant sinonasal neoplasms.

### Other Causes

In patients with post-ESS symptoms where no origin for their symptoms can be identified, other causes of sinonasal symptoms should be considered. In the case of facial

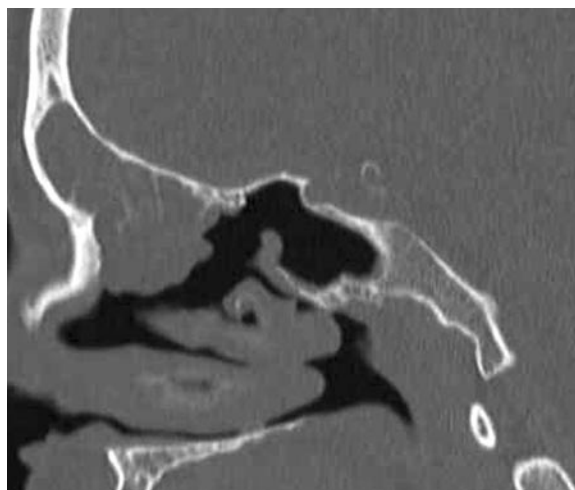
pain: neuralgia, migraine equivalent (midfacial headache), or dental problems may be responsible. The axial CT should be used to carefully assess the possibility of a small periapical dental abscess producing pain. In individuals with a history of migraine or multiple surgeries, a trial of amitriptyline may be warranted.

### Surgery

The role of revision surgery is principally to improve medical management, and surgery should be planned and executed to optimize this. This is achieved by either reducing disease load, by removing recurrent nasal polyps or hypertrophic sinonasal mucosa (Fig. 2.5), or improving access for continuing medical care in the form of topical solutions. Wide antrostomies are created for problem sinuses in order to provide better access for irrigating solutions. Continued postoperative medical therapy is essential and can be considered an integral part of surgical care.

### Tips and Pearls

1. Ensure an adequate trial of maximal medical therapy before planning surgery.
2. Surgery is indicated only after failure of appropriate medical management.
3. Be wary of pain as a sole presenting symptom in the absence of other physical findings.
4. Know when and how to use navigation.
5. Know your limitations as a surgeon – be realistic.



**Fig. 2.5** Recurrence of sinonasal polyposis. Sagittal CT showing extensive soft-tissue changes and polypoid disease in the region of the frontal recess. Note is made of the persistence of the anterior ethmoid cells, which indicates that previous surgery has not addressed these areas