

Pediatric ECG Interpretation: An Illustrative Guide

Barbara J. Deal M.D.

M.E. Wodika Professor of Pediatrics
Northwestern University Feinberg School of Medicine
Director, Electrophysiology Services
Children's Memorial Hospital
Chicago, IL

Christopher L. Johnsrude M.D.

Associate Professor of Pediatrics
Division of Pediatric Cardiology
University of Louisville School of Medicine
Louisville, KY

Scott H. Buck M.D.

Associate Professor of Pediatrics
University of North Carolina at Chapel Hill
Division of Pediatric Cardiology
North Carolina Children's Hospital
Chapel Hill, NC

Pediatric ECG Interpretation: An Illustrative Guide

The accompanying CD

This CD has been prepared for the reader's use with three purposes in mind:

- 1** as a self-evaluation tool for interpretation of ECGs
- 2** as a teaching reference for Cardiology fellows, residents, and house staff
- 3** as an invaluable resource for the Emergency Room physician or pediatrician who might obtain an ECG on a pediatric patient.

BJD

Pediatric ECG Interpretation: An Illustrative Guide

Barbara J. Deal M.D.

M.E. Wodika Professor of Pediatrics
Northwestern University Feinberg School of Medicine
Director, Electrophysiology Services
Children's Memorial Hospital
Chicago, IL

Christopher L. Johnsrude M.D.

Associate Professor of Pediatrics
Division of Pediatric Cardiology
University of Louisville School of Medicine
Louisville, KY

Scott H. Buck M.D.

Associate Professor of Pediatrics
University of North Carolina at Chapel Hill
Division of Pediatric Cardiology
North Carolina Children's Hospital
Chapel Hill, NC

© 2004 by Futura, an imprint of Blackwell Publishing

Blackwell Publishing, Inc., 350 Main Street, Malden, Massachusetts 02148-5020, USA

Blackwell Publishing Ltd, 9600 Garsington Road, Oxford OX4 2DQ, UK
Blackwell Science Asia Pty Ltd, 550 Swanston Street, Carlton, Victoria 3053, Australia

All rights reserved. No part of this publication may be reproduced in any form or by any electronic or mechanical means, including information storage and retrieval systems, without permission in writing from the publisher, except by a reviewer who may quote brief passages in a review.

04 05 06 07 5 4 3 2 1

ISBN: 1-4051-1730-3

Library of Congress Cataloging-in-Publication Data

Deal, Barbara J.

Pediatric ECG interpretation : an illustrative guide / Barbara J. Deal, Christopher L. Johnsrude, Scott H. Buck.

p. ; cm.

Includes bibliographical references and index.

ISBN 1-4051-1730-3

1. Electrocardiography—Interpretation. 2. Pediatric cardiology—Diagnosis. I. Johnsrude, Christopher L. II. Buck, Scott H. III. Title.

[DNLM: 1. Electrocardiography—Child—Atlases. 2. Heart Diseases—diagnosis—Child—Atlases. WS 17 D279p 2004]

RJ423.5.E43D43 2004

618.92'1207547—dc22

2003026391

A catalogue record for this title is available from the British Library

Acquisitions: Steve Korn

Production: Charlie Hamlyn

Typesetter: SNP Best-set Typesetter Ltd., Hong Kong

Printed and bound by Ashford Colour Press, in the UK

For further information on Blackwell Publishing, visit our website:

www.blackwellfutura.com

The publisher's policy is to use permanent paper from mills that operate a sustainable forestry policy, and which has been manufactured from pulp processed using acid-free and elementary chlorine-free practices. Furthermore, the publisher ensures that the text paper and cover board used have met acceptable environmental accreditation standards.

Notice: The indications and dosages of all drugs in this book have been recommended in the medical literature and conform to the practices of the general community. The medications described do not necessarily have specific approval by the Food and Drug Administration for use in the diseases and dosages for which they are recommended. The package insert for each drug should be consulted for use and dosage as approved by the FDA. Because standards for usage change, it is advisable to keep abreast of revised recommendations, particularly those concerning new drugs.

Contents

Acknowledgements, 6

Introduction, 7

Normal ECGs, 16

Abnormal ECGs, 40

Acquired Heart Disease, 60

Congenital Heart Disease, 88

Bradycardia and Conduction Defects, 122

Supraventricular Tachycardia, 154

Ventricular Arrhythmias, 202

Pacemakers, 240

Appendix 1: Age-related normal ECG values in children, 257

Appendix 2: Criteria for distinguishing VT from SVT, 258

Appendix 3: Location of accessory atrioventricular connection using initial delta wave polarity, 259

Appendix 4: Indications for pacing in childhood, 260

Index, 261

Acknowledgements

We gratefully acknowledge the following cardiologists for contributing electrocardiographic tracings: M. Ackerman M.D., E. Alboliras M.D., R. Friedman M.D., A. Griffin M.D., J. Hokanson M.D., J. Patel M.D., V. Pyevich M.D., and D. Ruschhaupt M.D. We also wish to thank the many people who lent their research, technical, and editorial support to this project, among them Joseph Hubbard, Marie Cross-Gilmore, Amos Carr, Brenda Delgadillo, Melanie Gevitz, and Peter Harris M.D.

B.J. Deal M.D.

C.L. Johnsrude M.D.

S.H. Buck M.D.

Introduction

Pattern recognition is an important learning tool in the interpretation of electrocardiograms (ECGs). Pediatric practitioners generally receive limited exposure to reading ECGs until faced with a patient with an arrhythmia or structural heart disease. The ability to clearly distinguish an abnormal ECG pattern from a normal variant in an emergency situation is an essential skill, but one that many physicians feel ill-prepared to confidently utilize. This atlas is directed at medical students, housestaff, and practitioners with limited background in pediatric cardiology.

In this atlas, we illustrate many of the ECG patterns a pediatric practitioner is likely to encounter. Normal variations of ECGs in children of different ages are presented, followed by examples of ECG abnormalities such as ventricular hypertrophy and atrial enlargement. ECGs of common forms of acquired heart disease are presented, followed by typical ECG examples of congenital heart disease. Arrhythmias are presented in sections on bradycardia and supraventricular and ventricular tachycardia, with a basic section on pacemaker ECGs. Simple techniques used to interpret mechanisms of arrhythmias are described, as the nonspecialist in cardiology or electrophysiology may not have a readily accessible resource for these ECG examples.

Pattern recognition in ECG interpretation is not intended to replace an understanding of the genesis of the ECG, but to complement the basic skills of ECG interpretation. Thus, the reader of this atlas is presumed to have mastered one of the many excellent texts on the basics of ECG interpretation.¹⁻⁵ This atlas relies on previously accepted norms for interpretation of pediatric ECGs.⁶ Other ECG norms obtained using computer-automated voltage amplitudes at sampling rates higher than in older ECG machines have been recently published.⁷ These data suggest some gender and ethnic variations in pediatric ECG norms likely exist, and may provide the basis for establishing new standards for abnormal values. Where helpful, we have provided limited references for those interested in further details on certain topics. With this approach, we hope that the reader will find ECG interpretation in children an enjoyable challenge.

ECG Interpretation

Interpreting ECGs involves a sequential analysis of each component of the tracing: **rate, rhythm, axis, intervals, morphology, and chamber hypertrophy and enlargement.**⁵ Reference values for normal age-related ECG measurements for pediatric patients are found in Appendix 1, modified from Davignon *et al.*⁶

Heart Rate: Normal heart rates on 12-lead ECG vary significantly with the age of the child. In the newborn, heart rates by ECG range from 90 to 170 bpm. The average heart rate increases slightly after the first week of age, to 105 bpm, and by 1 month of age may be 120 to 180 bpm. After the neonatal period, the heart rate drops gradually with age, ranging from 75 to 140 bpm by 3–5 years of age. By adolescence, the normal heart rate ranges from 65 to 120 bpm. Heart rates measured by ambulatory ECG (Holter) monitoring are significantly different than those recorded on the resting 12-lead ECG, reflecting the child’s level of activity.

Rhythm: The relationship of the P wave to the QRS complex is analyzed to determine the cardiac rhythm. The P wave of normal sinus rhythm is normally smooth and upright in leads I, II, III, and aVF, and biphasic in lead V1. In normal sinus rhythm, a P wave precedes each QRS complex, with a constant P–QRS relationship, and the heart rate falls in the normal range for age.

Automatic (ectopic) atrial rhythm is characterized by an abnormal P wave axis and/or morphology. *Primary atrial tachycardia* (Table 1, Classification of SVT) is an arrhythmia arising within the atria, such as atrial flutter or atrial re-entry, and is characterized by an abnormal P wave axis and/or morphology, with an abnormal atrial rate. The degree of atrioventricular conduction may vary from 1:1 to 2:1 or 3:1, or higher degrees of block in the presence of medications.

In the presence of tachycardia, one attempts to identify the mechanism of tachycardia by analysis of the QRS–P relationship.^{8,9} Retrograde P waves are frequently identified in supraventricular tachycardia, with a 1:1 ventriculoatrial or QRS–P relationship. A P wave buried in the QRS or at the end of the QRS complex is commonly seen in *atrioventricular nodal re-entry tachycardia*. A

Table 1: Classification of Supraventricular Tachycardia

| |
|--|
| • Supraventricular tachycardia utilizing accessory connections |
| Orthodromic reciprocating tachycardia (ORT) |
| Permanent form of junctional reciprocating tachycardia (PJRT) |
| Antidromic reciprocating tachycardia |
| Atrial tachycardia with antidromic conduction |
| Pre-excitation variants |
| • Atrioventricular nodal tachycardia |
| AV nodal re-entry tachycardia (AVNRT) |
| Junctional (automatic) tachycardia |
| • Primary atrial tachycardia |
| Sinus tachycardia |
| Atrial flutter |
| Atrial re-entry tachycardia |
| Automatic atrial tachycardia |
| Multifocal atrial tachycardia |
| Atrial fibrillation |

negative P wave following the QRS complex may be seen with *orthodromic reciprocating tachycardia* utilizing an accessory connection (e.g., the Wolff–Parkinson–White syndrome). In orthodromic reciprocating tachycardia, the QRS–P interval is greater than 0.07 sec, in contrast to atrioventricular nodal tachycardia, where the QRS–P interval is typically less than 70 msec.

Wide QRS tachycardia may be due to supraventricular tachycardia conducted to the ventricles with aberrancy (bundle branch block), atrial tachycardia conducted antegradely via an accessory atrioventricular connection (such as atrial fibrillation in the presence of Wolff–Parkinson–White syndrome), or ventricular tachycardia. Knowledge of the presence of pre-existing bundle branch block or pre-excitation may allow comparison of the QRS morphology in sinus rhythm and during tachycardia to establish the mechanism. The QRS–P relationship is analyzed. The ECG diagnosis of ventricular tachycardia is suggested by ventriculoatrial dissociation, the presence of fusion beats, a leftward QRS axis, and marked QRS duration prolongation greater than the 98th percentile for age. Criteria useful for differentiating ventricular tachycardia from supraventricular tachycardia with aberrancy have been summarized in Appendix 2.^{9–11}

Axis: The frontal plane axis of the P wave, QRS complex, and T wave is analyzed sequentially. Sinus rhythm is characterized by a P wave axis usually between +30 and +90 degrees (upright P wave in leads I and aVF). A left atrial rhythm shows a P wave axis between +90 and +270 degrees (negative P wave in leads I and V6), and a low right atrial rhythm exhibits superior axis deviation of the P wave (upright P in lead I, negative in aVF).

The QRS axis shifts significantly with age. The neonate has a QRS axis typically between +60 and +210 degrees, with gradual shifting to the left with development. By 1–5 years of age, the QRS axis is +10 to +110 degrees. Variations in QRS axis may be due to ventricular hypertrophy or abnormalities of ventricular conduction (bundle branch block, ventricular pre-excitation).

The T wave axis should generally correspond to the QRS axis, known as QRS–T concordance. Greater than a 90 degree difference between the QRS and T wave axis, or QRS–T wave discordance, may reflect myocardial injury or strain.

Intervals: The PR, QRS, and QT intervals are measured individually, and are compared to age-related normal values. A normal PR interval is shorter in a child than in an adult. Normal PR intervals in the neonate range from 0.08 to 0.16 sec. The normal PR interval lengthens gradually with age, so that by 12–16 years of age, the normal PR interval is 0.09–0.18 sec. A short PR interval with a delta wave (slurred onset of the QRS complex) may be seen with manifest pre-excitation, or Wolff–Parkinson–White syndrome. The initial delta wave polarity may be helpful in determining the location of the accessory atrioventricular connection; one schema is included in Appendix 3.¹²

The QRS duration is typically shorter in a young infant than in an adult. Under 4 years of age, the QRS duration is less than 0.09 sec, and less than 0.10 sec up to 16 years of age. By late adolescence, the QRS duration should be less than 0.11 sec. Longer QRS durations are associated with abnormal intra-ventricular conduction (bundle branch block, myocardial injury, electrolyte disturbances, ventricular pre-excitation) or cardiac arrhythmia (ventricular tachycardia).

The QT interval, as measured from the onset of the Q wave to the end of the T wave in lead II, should be corrected for heart rate (QTc). In general, the normal QTc is less than or equal to 0.44 sec. In the first several days of life there may be transient prolongation of the QTc, which should normalize after the first week of life. Prolonged QT intervals may be seen with congenital long QT syndrome, abnormal ventricular depolarization (bundle branch block), cardiomyopathy, or metabolic or electrolyte abnormalities.

Morphology: The appearance of the P wave, Q wave, QRS complex, and T waves is analyzed sequentially. Notching or prolongation of the P wave may indicate an ectopic atrial rhythm or other atrial tachycardia, atrial enlargement, or intra-atrial conduction abnormality.

Q waves are normally seen in the inferior leads II, III, aVF and lateral leads V5–V6. The presence of a Q wave in V1 is abnormal at any age, and may reflect right ventricular hypertrophy, ventricular inversion, myocardial infarction, left bundle branch block, or pre-excitation pattern. Pathologic Q waves are characterized by abnormally deep or wide Q waves. Deep Q waves in leads I, aVL, and the left precordium may be seen in infants with anomalous origin of the left coronary artery, reflecting a pattern of myocardial infarction. Deep Q waves in inferior and lateral leads may be seen in left ventricular hypertrophy.

Delays in ventricular conduction manifest as a prolonged QRS complex, usually with abnormal QRS morphology and axis. *Bundle branch block* is identified by QRS duration greater than normal for age (see above), and in children is usually due to surgery for structural heart disease, or cardiomyopathy. *Right bundle branch block* is characterized by an rsR' or rR' pattern in lead V1, with a broad, slurred S wave in leads I and V6. *Left bundle branch block* is identified by a tall, notched R wave in V6, with a broad slurred QS complex in lead V1.

The ST segment and T waves reflect ventricular repolarization. A normal ST segment is less than 1 mm above or less than 0.5 mm below the baseline. The T wave axis should be concordant with the QRS axis in most leads. In children, tall T waves in the mid and lateral precordium are often seen; in general, the T wave amplitude should be less than 10 mm in the precordial leads. Abnormal ST segments and T waves may reflect a normal variation such as early repolarization, or indicate pathology such as myopericarditis, metabolic/electrolyte imbalances, hypertrophy, cardiomyopathy, or long QT syndrome.

Chamber hypertrophy and enlargement: Atrial enlargement can be determined by ECG only when the patient is in sinus rhythm. The ECG cannot be used to reliably diagnose ventricular hypertrophy in the presence of bundle branch block, ventricular pre-excitation, paced ventricular rhythm, or ventricular arrhythmia.

Right atrial enlargement is characterized by tall peaked P waves, greater than 2.5 mm in amplitude in any lead, often best seen in lead II.

Left atrial enlargement is characterized by prolonged P wave duration, greater than 0.09–0.10 sec, and a negative terminal deflection in V1 >0.04 sec wide and >1 mm in depth. For *biatrial enlargement*, criteria for both right and left atrial enlargement are met.

Right ventricular hypertrophy (Table 2) is diagnosed when the height of the R wave in V1 or the depth of the S wave in V6 are greater than normal for age. Age-related criteria for normal QRS amplitude in leads V1 (which overlies the right ventricle) and V6 (which overlies the left ventricle) are summarized in Appendix 1. The normal neonate has right ventricular predominance, with gradual shifting to left ventricular dominance by 3–5 years of age. The T wave in V1 is normally upright at birth, inverts by 1 week of age, and may become upright once more when a mature ECG pattern is obtained, usually after 8 years of age. A persistently upright T wave in lead V1 after 1 week of age and before 8 years of age is indicative of right ventricular hypertrophy.

Left ventricular hypertrophy (Table 3) is diagnosed when the R wave amplitude in lead V6 or the S wave amplitude in lead V1 is greater than the 98th

Table 2: Right Ventricular Hypertrophy Criteria

| |
|---|
| R wave >98th percentile in lead V1 |
| S wave >98th percentile in lead V6 |
| R wave in V1 + S wave in V6 >98th percentile |
| R/S ratio >98th percentile in lead V1 |
| Right axis deviation (>98th percentile of QRS in frontal plane) |
| qR pattern in V1 |
| Upright T wave in V1 (1 week old to 8 years old) |
| RSR' pattern in lead V1, where R' >15 mm (<1 year old) or R' >10 mm (>1 year old) |
| Pure R wave in V1 >10 mm (newborn) |
| RVH (by voltage criteria) with strain pattern |

Table 3: Left Ventricular Hypertrophy Criteria

| |
|---|
| R wave >98th percentile in lead V6 |
| S wave >98th percentile in lead V1 |
| R wave in V6 + S wave in V1 >98th percentile |
| Q wave >98th percentile in lead III or V6 |
| R/S ratio >98th percentile in lead V6 |
| LVH (by voltage criteria) with strain pattern |

percentile for age. In the neonate, left ventricular forces in lead V6 range from 0 to 12 mm in height, with an average of 5 mm. The left ventricular voltage increases with age, and in general, an R wave greater than 27 mm in V6 at any age indicates left ventricular hypertrophy. Exceptionally deep S waves in V1 and V2, or very tall R waves in the inferior limb leads, are other indicators of left ventricular hypertrophy.

Biventricular hypertrophy is present when criteria for both right and left ventricular hypertrophy are present. The Katz–Wachtel criteria¹³ for biventricular hypertrophy is combined R + S wave voltage in the mid-precordial leads V3–V4 greater than 60 mm at any age.

Pacemakers: Pacemakers may be single or dual chamber systems, and are commonly described using the three-to-five-letter designation of the pacemaker nomenclature.¹⁴ The first letter states the chamber(s) paced; the second letter the chamber(s) sensed; the third letter designates the pacemaker’s response to intrinsic sensed beats; the fourth letter indicates programmable functions, including rate-responsiveness; the fifth letter indicates anti-tachycardia pacing functions. The more common designations are summarized in Table 4.

Table 4: Pacing Nomenclature and Common Programmable Generator Features

| Feature | Measures and Options | Description |
|-------------|--|--|
| Pacing mode | <i>Single-chamber pacemakers</i> AAI, AOO, AAIR, VVI, VOO, and VVIR | Shorthand description of: chamber(s) paced (1st letter) and sensed (2nd letter), response to sensed beat (3rd letter), and whether pacemaker has a rate-adaptive sensor (R) |
| | <i>Dual-chamber pacemakers</i> DDD, DOO, VDD, DDI, DDDR, and DDIR | |
| Output | Voltage, current, and duration of pulse | Measures of energy generated by pacemaker when stimulus is delivered |
| Sensitivity | Atrial, ventricular, or both | Amplitude of intracardiac signal sensed as intrinsic atrial or ventricular activity |
| Rate | Lower rate limit, upper rate limit | Minimal intrinsic heart rate tolerated before pacing begins (lower rate limit); for dual-chamber pacemakers programmed to sense intrinsic atrial activity, maximal rate at which pacemaker tracks atrial activity in a 1 : 1 relation (upper rate limit) |

A, atrium; D, dual; I, inhibited; O, none; R, rate-adaptive; V, ventricle

Indications for pacing are not reviewed in the text, but current recommendations are summarized below as a reference resource (Appendix 4).¹⁵ **Class I** indications are those for which there is evidence or general agreement that a given procedure or treatment is beneficial, useful, and effective. **Class II** indications are those for which there is conflicting evidence or a divergence of opinion about the usefulness or efficacy of a procedure or treatment. In **Class IIa** the weight of evidence or opinion is in favor of the procedure's usefulness or efficacy, while in **Class IIb** the usefulness or efficacy is less well established. **Class III** indications are those for which there is evidence or general agreement that a procedure or treatment is not useful or effective and in some cases may be harmful.

References

- 1 Walsh EP. Electrocardiography and introduction to electrophysiologic technique. In Fyler DC, ed. *Nadas' Pediatric Cardiology*. Philadelphia: Hanley & Belfus, 1992, 117–158.
- 2 Park MK, Gunteroth WG. *How to Read Pediatric ECGs*, 3rd edn. St. Louis: Mosby Year Book, 1992.
- 3 Garson A Jr. *The Electrocardiogram in Infants and Children: A Systematic Approach*. Philadelphia: Lea & Febiger, 1983.
- 4 Surawicz B, Knilans TK, Chou T-C. *Chou's Electrocardiography in Clinical Practice—Adult and Pediatric*, 5th edn. Philadelphia: WB Saunders, 2001.
- 5 Dubin D. *Rapid Interpretation of EKGs*, 6th edn. Tampa, FL: Cover Publishing, 2000.
- 6 Davignon A, Rautaharju P, Boisselle E, Soumis F, Megelas M, Choquette A. Normal ECG standards for infants and children. *Pediatr Cardiol* 1980;1:123–131.
- 7 Rijnbeek PR, Witsenburg M, Schrama E, Hess J, Kors JA. New normal limits for the paediatric electrocardiogram. *Eur Heart J* 2001;22:702–711.
- 8 Josephson ME, Wellens HJ. Differential diagnosis of supraventricular tachycardia. *Cardiol Clin* 1990;8:411–442.
- 9 Tipple MA. Usefulness of the electrocardiogram in diagnosing mechanisms of tachycardia. *Pediatr Cardiol* 2000;21:516–521.
- 10 Antunes E, Brugada J, Steurer G, Andries E, Brugada P. The differential diagnosis of a regular tachycardia with a wide QRS complex on the 12 lead ECG. *Pacing Clin Electrophysiol* 1994;17:1515–1522.
- 11 Brugada P, Brugada J, Mont L, Smeets J, Andries EW. A new approach to the differential diagnosis of a regular tachycardia with a wide QRS complex. *Circulation* 1991;83:1649–1659.
- 12 Arruda MS, McClelland JH, Wang X, Beckman KJ, Widman LE, Gonzalez MD, Nakagawa H, Lazzara R, Jackman WM. Development and validation of an ECG algorithm for identifying accessory pathway ablation site in Wolff–Parkinson–White syndrome. *J Cardiovasc Electrophysiol* 1998;9:2–12.
- 13 Katz LN, Wachtel H. The diphasic QRS type of electrocardiogram in congenital heart disease. *Am Heart J* 1937;13:202–206.

14 Introduction

- 14 Bernstein AD, Daubert J-C, Fletcher RD, Hayes DL, Lüderitz B, Reynolds DW, Schoenfeld MH, Sutton R. NASPE position statement. The revised NASPE/BPEG generic code for antibradycardia, adaptive-rate, and multisite pacing. *Pacing Clin Electrophysiol* 2002;**25**:260–264.
- 15 Gregoratos G, Abrams J, Epstein AE, Freedman RA, Hayes DL, Hlatky MA, *et al.* ACC/AHA/NASPE 2002 guideline update for implantation of cardiac pacemakers and antiarrhythmia devices—summary article: a report of the American College of Cardiology/American Heart Association Task Force on Practice Guidelines (ACC/AHA/NASPE Committee to Update the 1998 Pacemaker Guidelines). *J Am Coll Cardiol* 2002;**40**:1703–1719.

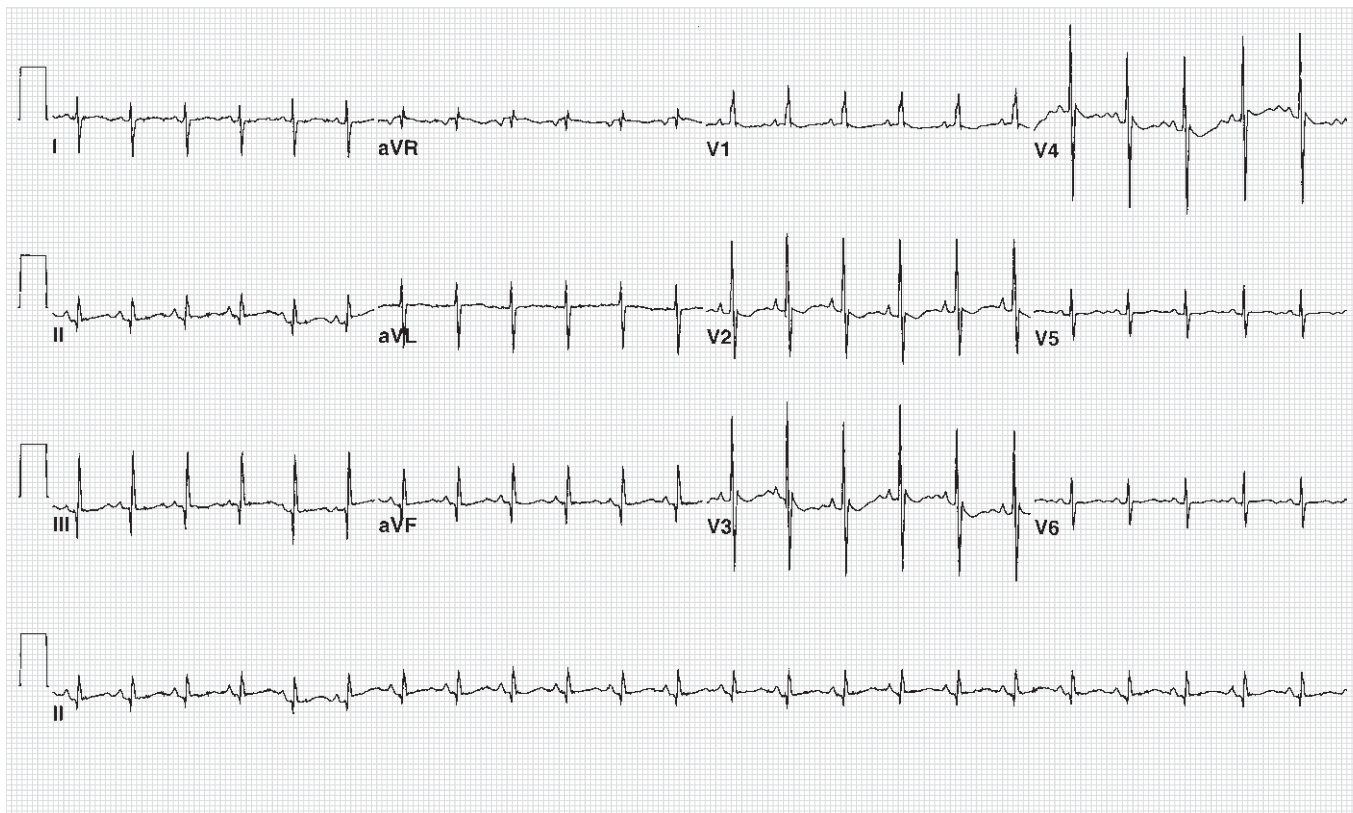


Figure 1 1-day-old infant.

Figure 1

- Normal sinus rhythm, 140 bpm
- QRS axis $+120^\circ$
- Pure R wave in V1
- S wave in V6 = 5 mm
- Nonspecific ST flattening

Normal ECG: 1 day old

- Heart rate: 94–155 bpm
- QRS axis: $+58^\circ$ to 192°
- Upright T waves in V1 are normal up to 7 days old
- Right ventricular predominance:
 - R wave in V1 ≤ 27 mm
 - R/S ratio in V1 = 0.2–9.8, mean 2.3
- R wave in V6: range 0–12 mm

Reference

Rautaharju M, Davignon A, Soumis F, Boisselle E, Choquette A. Evolution of QRS–T relationship from birth to adolescence in Frank-lead orthogonal electrocardiograms of 1492 normal children. *Circulation* 1979;**60**:196–204.

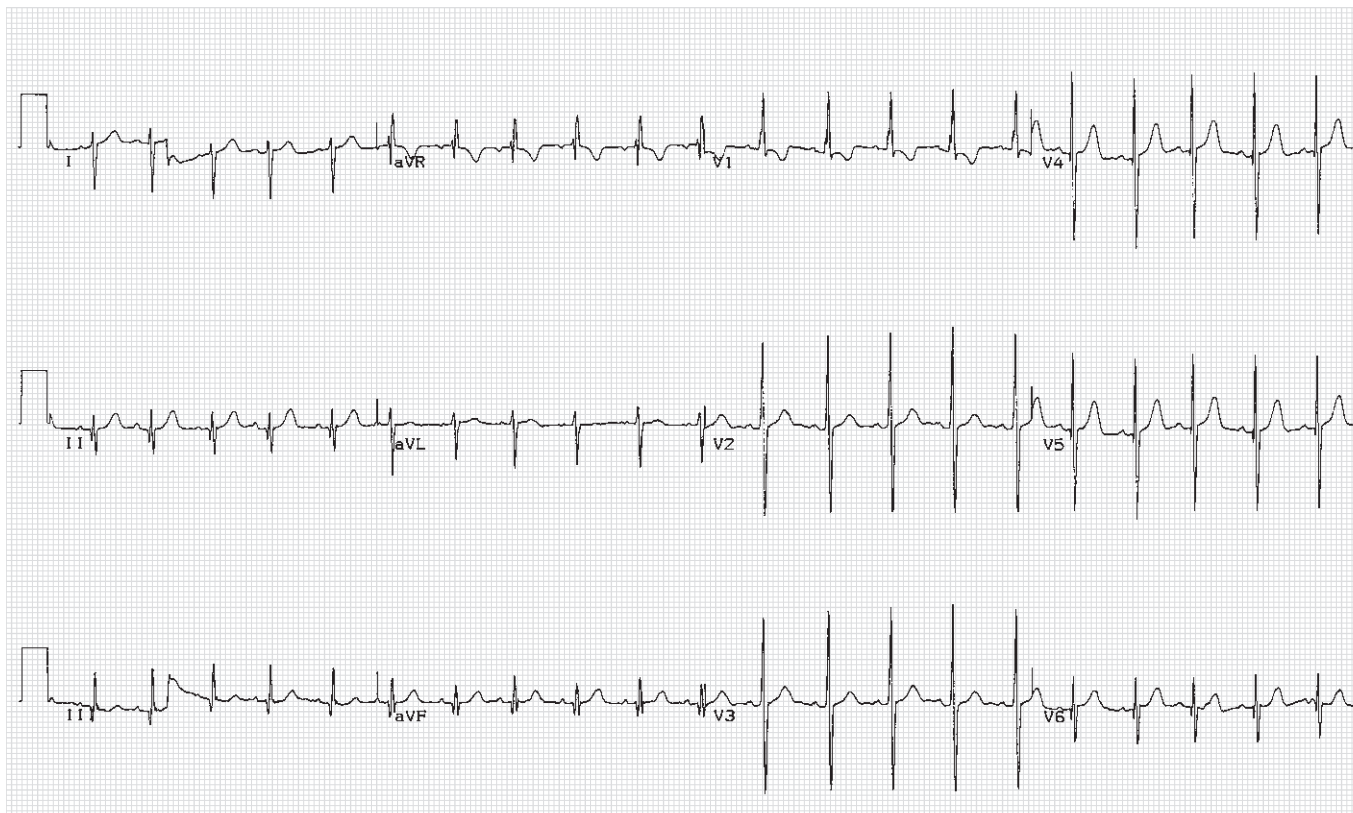

Figure 2 2-week-old infant.

Figure 2

- Normal sinus rhythm, 130 bpm
- QRS axis $+160^\circ$
- Tall R wave in V1
- S wave in V6 = 6 mm
- Inverted T waves in V1

Normal ECG: 2 weeks old

- Heart rate: 106–182 bpm
- QRS axis: $+65^\circ$ to $+160^\circ$
- R wave in V1 ≤ 22 mm
- R wave in V6 = 3–17 mm
- R/S ratio in V1 = 1.0–7.0

Reference

VanHare GF, Dubin AM. The normal electrocardiogram. In Allen HD, Clark EB, Gutgesell HP, Driscoll DJ, eds, *Moss and Adams' Heart Disease in Infants, Children, and Adolescents—Including the Fetus and Young Adults*, 6th edn. Philadelphia: Lippincott Williams & Wilkins, 2001, 425–442.

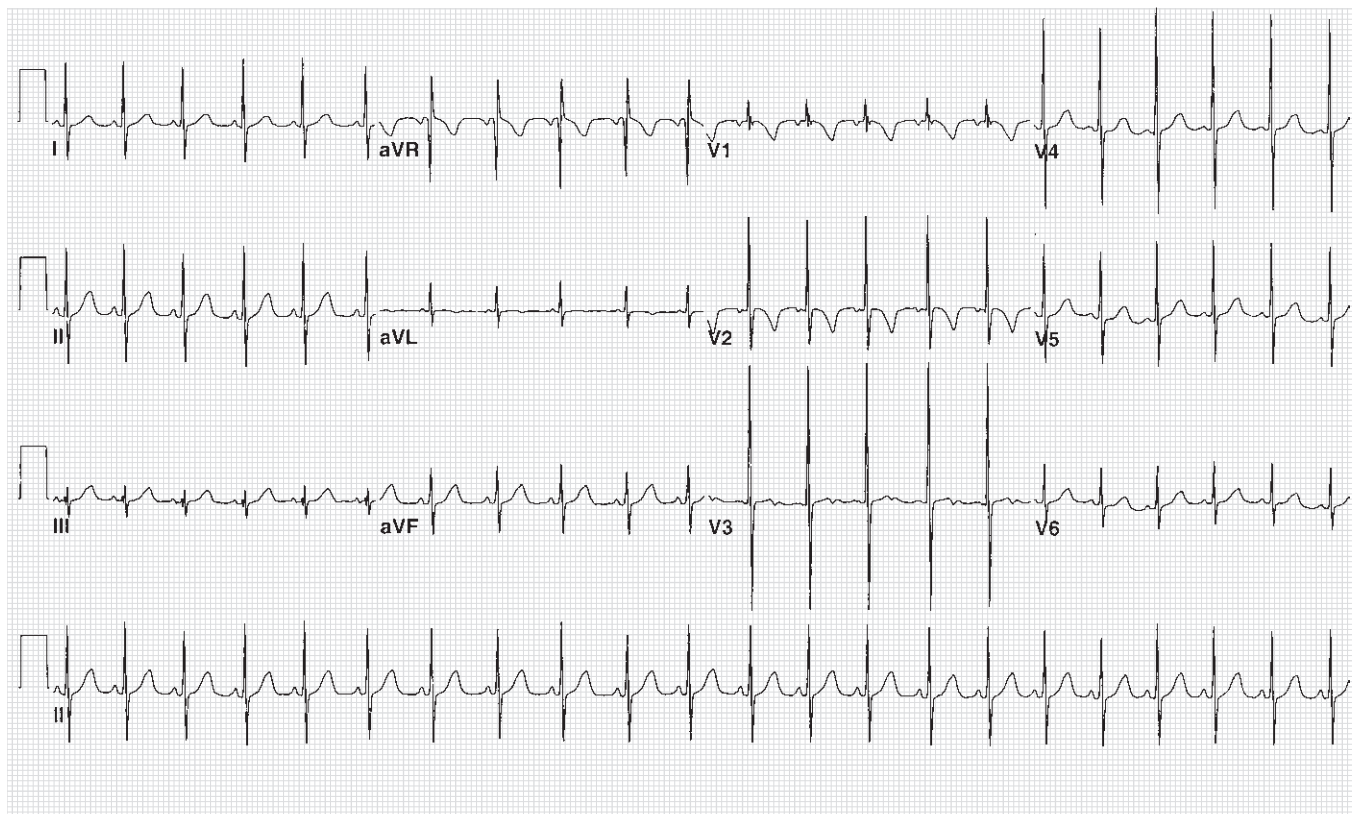


Figure 3 5-month-old female.

Figure 3

- Normal sinus rhythm, 130 bpm
- QRS axis $+30^\circ$
- Rsr' pattern in V1
- S wave in V6 = 3 mm

Normal ECG: 5 months old

- Heart rate: 105–185 bpm
- QRS axis: $+7^\circ$ to $+105^\circ$
- R wave in V1 ≤ 20 mm
- R wave in V6 = 6–23 mm
- R/S ratio in V1 = 0.2–6.0
- Q in lead III ≤ 7 mm

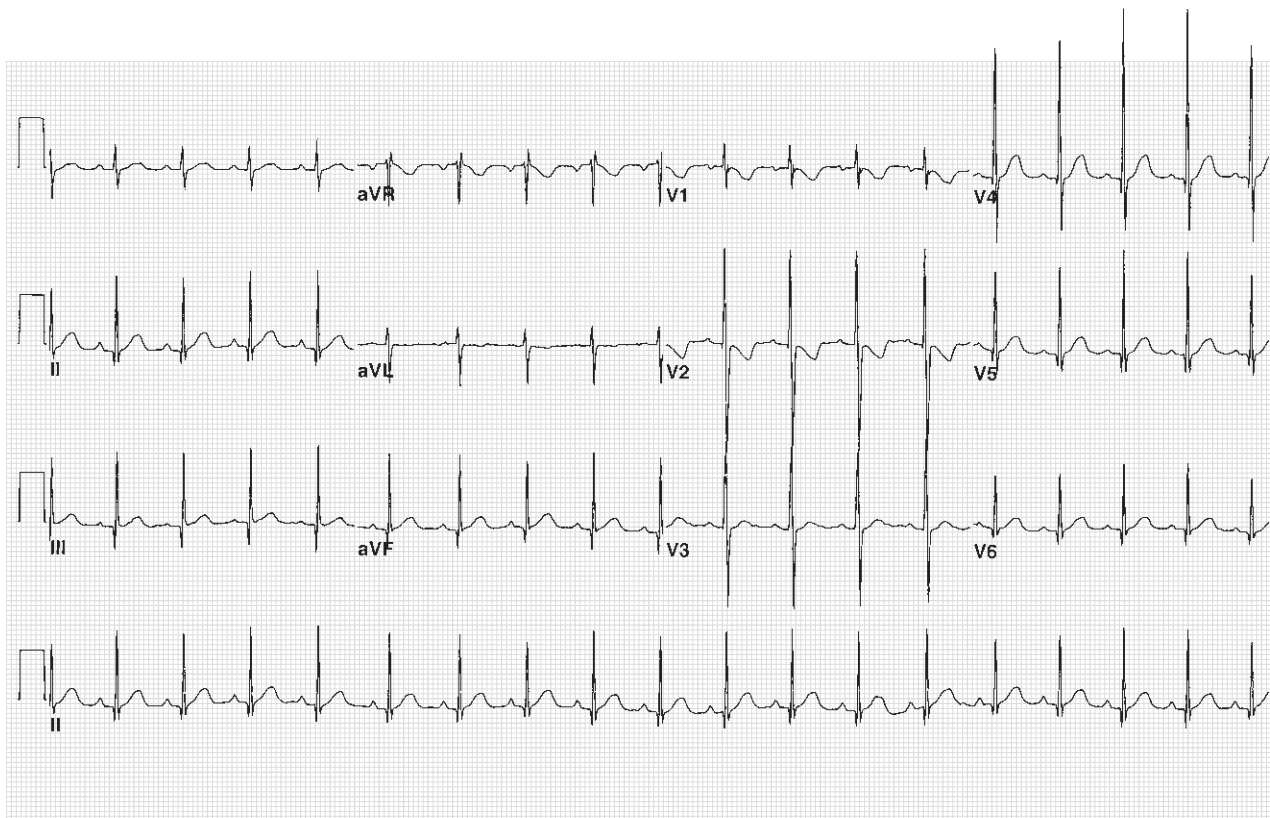


Figure 4 Asymptomatic 1-year-old male.

Figure 4

- Normal sinus rhythm, 110 bpm
- QRS axis $+80^\circ$
- Small q waves in inferior and lateral leads
- rS in V1 progressing to dominant R wave in V6

Normal ECG: 1 year old

- Heart rate: 90–150 bpm
- QRS axis: $+8^\circ$ to $+100^\circ$
- R wave in V1: 3–18 mm
- R wave in V6: 6–23 mm
- R/S ratio in V1: 0.1–4.2
- Q wave in lead III ≤ 5 mm

Reference

Walsh EP, Lang P, Ellison RC, Zierler S, Harned HS, Miettinen OS. Electrocardiogram of the premature infant at 1 year of age. *Pediatrics* 1986;77:353–356.

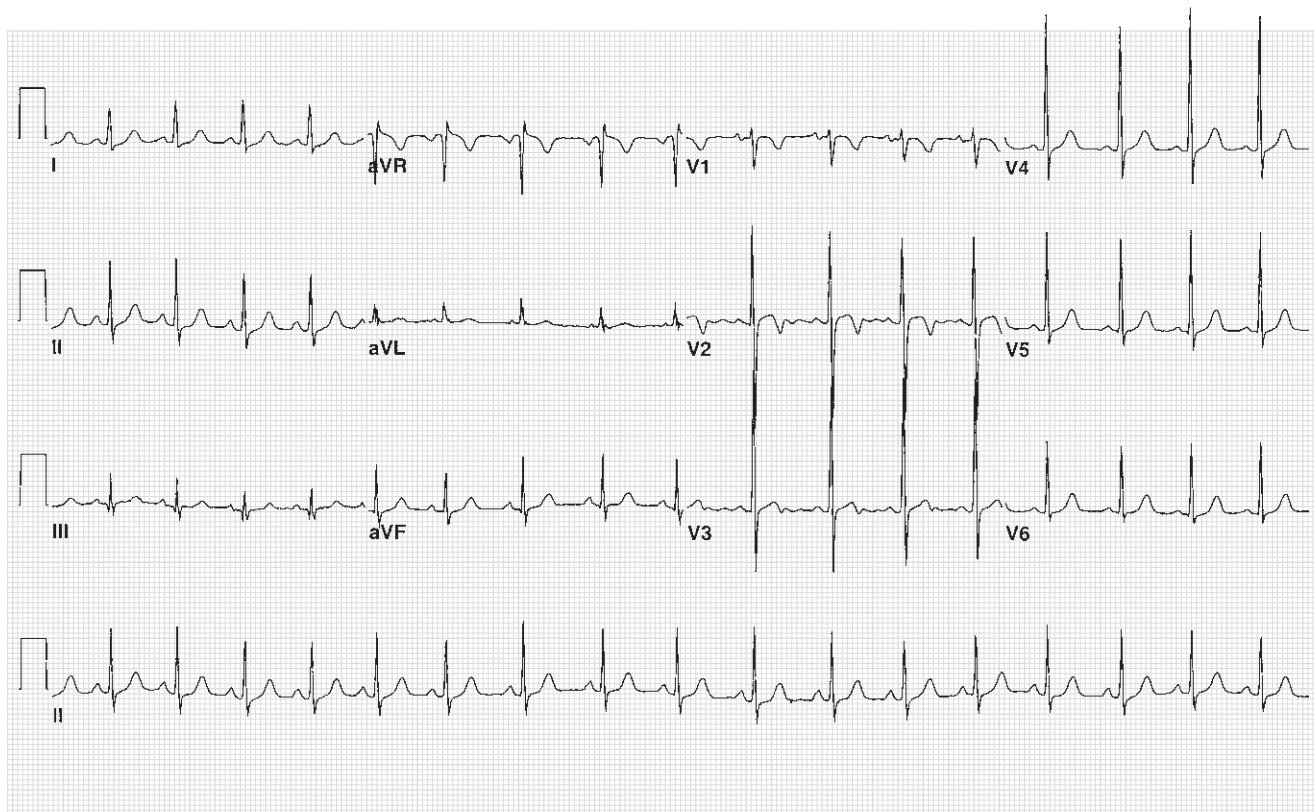


Figure 5 Asymptomatic 5-year-old female.

Figure 5

- Normal sinus rhythm, 105 bpm
- QRS axis $+50^{\circ}$
- rS in V1, progressing to dominant R wave in V6
- Normal precordial voltage

Normal ECG: 5 years old

- Heart rate: 70–140 bpm
- QRS axis: $+7^{\circ}$ to $+105^{\circ}$
- R wave in V1: 2–18 mm
- R wave in V6: 9–25 mm
- R/S ratio in V1: 0–2.8