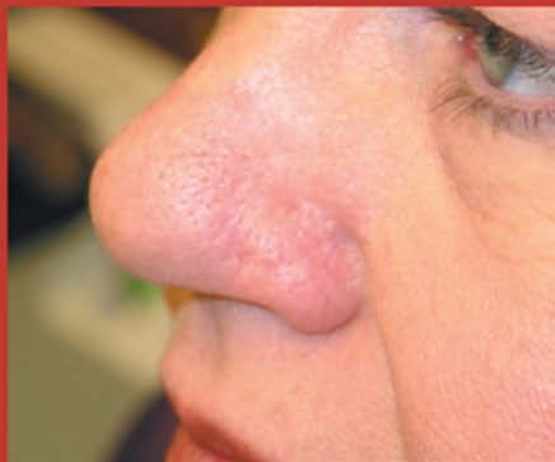
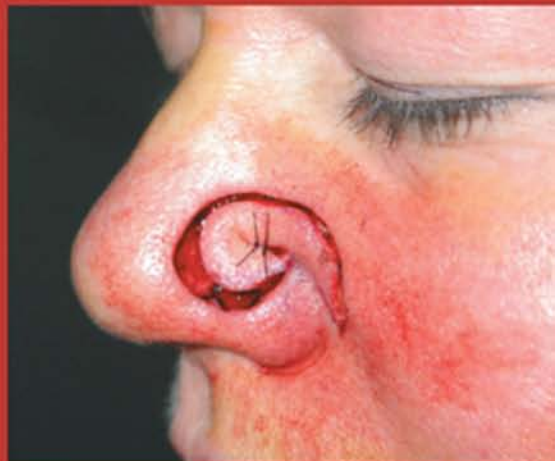
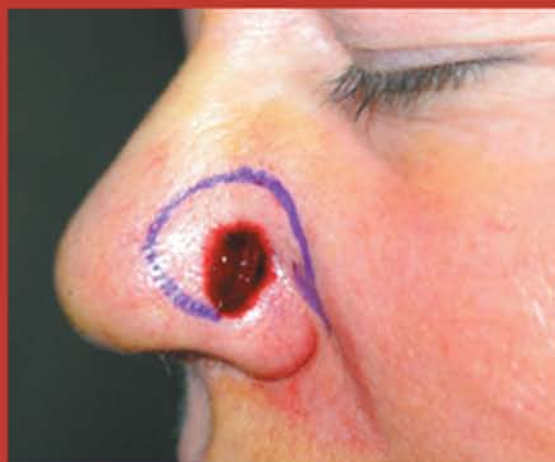Reconstructive Conundrums in Dermatologic Surgery

The Nose

Edited by
Désirée Ratner
Joel L. Cohen
David G. Brodland



AS|DS.
American Society for
Dermatologic Surgery
EXPERTISE FOR THE *life* OF YOUR SKIN™

WILEY Blackwell

Reconstructive Conundrums
in Dermatologic Surgery
The Nose

Reconstructive Conundrums in Dermatologic Surgery

The Nose

EDITED BY

Désirée Ratner, MD

Director, Comprehensive Skin Cancer Program, Beth Israel Medical Center, Mount Sinai Health System, New York, NY, USA

Joel L. Cohen, MD

Director, AboutSkin Dermatology and DermSurgery, Englewood, CO, USA
Associate Professor, Department of Dermatology, University of Colorado, Aurora, CO, USA
Assistant Professor, Department of Dermatology, University of California, Irvine, CA, USA

David G. Brodland, MD

Co-Director, Z & B Skin Cancer Center, Pittsburgh, PA, USA
Assistant Professor, Departments of Dermatology and Otolaryngology, University of Pittsburgh, Pittsburgh, PA, USA

WILEY Blackwell

AS|DS
American Society for
Dermatologic Surgery

This edition first published 2014 © 2014 by American Society for Dermatologic Surgery

Registered office: John Wiley & Sons, Ltd, The Atrium, Southern Gate, Chichester, West Sussex, PO19 8SQ, UK

Editorial offices: 9600 Garsington Road, Oxford, OX4 2DQ, UK
The Atrium, Southern Gate, Chichester, West Sussex, PO19 8SQ, UK
111 River Street, Hoboken, NJ 07030-5774, USA

For details of our global editorial offices, for customer services and for information about how to apply for permission to reuse the copyright material in this book please see our website at www.wiley.com/wiley-blackwell

The right of the author to be identified as the author of this work has been asserted in accordance with the UK Copyright, Designs and Patents Act 1988.

All rights reserved. No part of this publication may be reproduced, stored in a retrieval system, or transmitted, in any form or by any means, electronic, mechanical, photocopying, recording or otherwise, except as permitted by the UK Copyright, Designs and Patents Act 1988, without the prior permission of the publisher.

Designations used by companies to distinguish their products are often claimed as trademarks. All brand names and product names used in this book are trade names, service marks, trademarks or registered trademarks of their respective owners. The publisher is not associated with any product or vendor mentioned in this book. It is sold on the understanding that the publisher is not engaged in rendering professional services. If professional advice or other expert assistance is required, the services of a competent professional should be sought.

The contents of this work are intended to further general scientific research, understanding, and discussion only and are not intended and should not be relied upon as recommending or promoting a specific method, diagnosis, or treatment by health science practitioners for any particular patient. The publisher and the author make no representations or warranties with respect to the accuracy or completeness of the contents of this work and specifically disclaim all warranties, including without limitation any implied warranties of fitness for a particular purpose. In view of ongoing research, equipment modifications, changes in governmental regulations, and the constant flow of information relating to the use of medicines, equipment, and devices, the reader is urged to review and evaluate the information provided in the package insert or instructions for each medicine, equipment, or device for, among other things, any changes in the instructions or indication of usage and for added warnings and precautions. Readers should consult with a specialist where appropriate. The fact that an organization or Website is referred to in this work as a citation and/or a potential source of further information does not mean that the author or the publisher endorses the information the organization or Website may provide or recommendations it may make. Further, readers should be aware that Internet Websites listed in this work may have changed or disappeared between when this work was written and when it is read. No warranty may be created or extended by any promotional statements for this work. Neither the publisher nor the author shall be liable for any damages arising herefrom.

Library of Congress Cataloging-in-Publication Data

Reconstructive conundrums in dermatologic surgery : the nose / edited by Desiree Ratner, Joel L. Cohen, David G. Brodland.

1 online resource.

Other title: Nose

Includes bibliographical references and index.

Description based on print version record and CIP data provided by publisher; resource not viewed.

ISBN 978-1-118-29498-7 (ePub) – ISBN 978-1-118-29499-4 (Adobe PDF) –

ISBN 978-1-118-27232-9 (cloth)

I. Ratner, Desiree, editor of compilation. II. Cohen, Joel L. (Dermatologist), editor of compilation. III. Brodland, David G., editor of compilation. IV. American Society for Dermatologic Surgery, issuing body. V. Title: Nose.

[DNLM: 1. Nose – surgery – Case Reports. 2. Dermatologic Surgical Procedures – methods – Case Reports. WV 312]

RF350

617.523059 – dc23

2014002389

A catalogue record for this book is available from the British Library.

Wiley also publishes its books in a variety of electronic formats. Some content that appears in print may not be available in electronic books.

Cover images: © American Society for Dermatologic Surgery

Cover design by Andy Meaden

Set in 9/12 pt Minionpro by Laserwords Private Limited, Chennai, India



Contents

Introduction, vii

Part I Nasal Dorsum, 1

- 1 Combined Linear Closure and Burow's Graft for a Dorsal Nasal Defect, 3
- 2 Reconstruction of Two Nasal Defects Following Mohs Surgery, 9
- 3 Repair of Adjacent Nasal Defects with One Double-Rotation Flap Closure, 13
- 4 Contralateral Nasolabial Flap for a Large Nasal Defect, 19

Part II Nasal Sidewall, 23

- 5 Dual Nasal Sidewall and Lip Defects Combined into a Single Arcuate Advancement Flap, 25
- 6 Advancement Flap in the Reconstruction of a Lateral Nasal Sidewall Defect, 31
- 7 Repair of the Left Nasal Sidewall, Nasofacial Sulcus, and Medial Cheek, 35

Part III Nasal Tip, 41

- 8 The Dorsal Nasal Flap for Reconstruction of Large Nasal Tip Defects, 43
- 9 Adjunctive Use of Primary Nasal Tip Closure to Facilitate Local Flap Closure of Challenging Nasal Defects, 49
- 10 Repair of a Large, Exposed-Cartilaginous Nasal Tip Defect Using Nasalis-Based Subcutaneous Pedicle Flaps and Full-Thickness Skin Grafting, 55
- 11 Nasal Tip Wound Repair Using a Rhombic Transposition Flap with a Double Z-Plasty at Its Base, 63

Part IV Nasal Ala, 69

- 12 Spiral Subcutaneous Island Pedicle Advancement Flap for Repair of Alar Defects, 71
- 13 Combined Hinge Flap Full-Thickness Skin Graft for a Through-and-Through Nasal Defect, 75
- 14 Combined Hinge and Nasolabial Transposition Flap for Repair of a Full-Thickness Nasal Ala Defect, 79

Part V Alar Groove/Perialar Defects, 85

- 15 Shark Island Pedicle Flap for Repair of Combined Nasal Ala-Perialar Defects, 87
- 16 "Jigsaw Puzzle" Advancement Flap for Repair of a Surgical Defect Involving the Lateral Nasal Ala, 93
- 17 Dog-Ear Island Pedicle Flap for Repair of Ala and Nasal Wall Defects, 99

Part VI Alar Rim, 105

- 18 Repair of an Alar Defect, 107
- 19 Reconstruction of a Full Thickness Soft Triangle Defect, 113
- 20 A Tunneled and Turned-Over Nasolabial Flap for Reconstruction of Full-Thickness Nasal Ala Defects, 119
- 21 Reconstruction of an Alar Rim Defect, 127
- 22 Island Pedicle Flaps for Repair of a Nose, Cheek, and Lip Defect, 131
- 23 Revisionary Technique for Alar Rim Notching: The Stair-Step Flap, 137
- 24 Reconstruction of a Surgical Defect Involving the Nasal Ala and Alar Crease, 145
- 25 One-Stage Reconstruction of a Full-Thickness Nasal Defect Involving the Alar Rim, 151

- 26 Repair of a Defect on the Ala, 157
- 27 Single-Stage Reconstruction of a Combined Upper Lip and Nasal Ala Defect, 163
- 28 Nasal Dorsum Transposition Flap for Closure of an Alar Rim Defect, 169
- 29 Bilobed Flap for Full-Thickness Nasal Defect: A Common Flap for an Uncommon Indication, 175
- 30 One-Stage Reconstruction Following Complete Alar Loss, 181
- Index, 187



Introduction

The Reconstructive Conundrum section of the journal *Dermatologic Surgery* first appeared in the year 2000. Edited by David Brodland, this section was intended to focus on teaching points related to closure type, defect site, and underlying anatomy. Photographs of the defect to be reconstructed, an immediate postreconstruction photograph, and two long-term follow-up views were required, and discussion of the closure specifically included the authors' thought process regarding the best option for repair, as well as possible alternative options and why they were not chosen. Historical details relevant to the case were often included in the presentation, and pearls relating to the specific closure or to reconstruction in general could be included in the discussion as well.

Over time, a wide variety of reconstructive conundrums have appeared in the journal exploring new directions with innovative repair options. Dermatologic surgeons in training, as well as more experienced practitioners, have found these manuscripts to be a valuable educational resource. The creativity of the surgeons authoring the conundrums, as well as the depth and breadth of their knowledge and experience, as demonstrated by the cases they present, is both impressive and inspiring.

Our trainees are always looking for texts and atlases illustrating reconstructive options for difficult defects. It occurred to us that a collection of the “best of the best” reconstructive conundrums might therefore be both interesting and useful as an educational resource to residents in dermatology, plastic surgery, otolaryngology, Mohs surgery fellows, and reconstructive surgeons still early in their careers. These physicians would most benefit from a book focusing on critical analysis of tissue defects and creative approaches to soft tissue reconstruction. Our intent in putting together such a text is to

compile these cases for easy perusal as it is difficult at this point of time to view multiple conundrums consecutively and efficiently either electronically or in print, and it seemed to us that an “atlas-like” textbook would therefore be of value to these groups of readers. Because the nose is by far the site that tends to cause the most angst among reconstructive surgeons, as well as the most common site discussed in these conundrums, it made sense for the first group of cases to focus on complex nasal reconstruction.

While the reasoning and thought processes associated with the accomplishment of each closure are thoroughly discussed in each published conundrum, there are always alternative points of view which highlight additional points and “pearls”. We therefore felt that commentaries by more experienced reconstructive surgeons would both complement and supplement the existing text.

To this end, we have compiled a series of 30 outstanding nasal reconstruction cases published in the Reconstructive Conundrum section over the past 10 years, grouped them by nasal subunits, and appended them to commentaries of our own. We have sought to include a diverse group of defects and reconstructions, and in some cases, we have included our own photographs of similar defects with contrasting closures to illustrate points relevant to a particular case.

We hope that you will find this compilation of nasal reconstructive conundrum cases both educational and inspirational and that you will enjoy reading them and thinking about them as much as we have.

Désirée Ratner, MD
Joel Cohen, MD
David Brodland, MD

I

PART I

Nasal Dorsum

1

CONUNDRUM 1

Combined Linear Closure and Burow's Graft for a Dorsal Nasal Defect

Daniel S. Behroozan¹ & Leonard H. Goldberg²

¹DermSurgery Associates, Houston, Texas

²Department of Medicine (Dermatology), University of Texas, MD Anderson Cancer Center, Houston, Texas

An 80-year-old man with a history of nonmelanoma skin cancers of the head and neck presented for treatment of a basal cell carcinoma of the nose. Physical examination revealed a poorly defined, exophytic, ulcerated nodule of the mid-dorsal nose. Given the size, location, and ill-defined margins of the tumor, Mohs micrographic surgical excision was indicated. The tumor was excised in three stages with microscopic control. The final defect was full thickness of the dermis, sparing the underlying muscle and measuring 3.2×2.4 cm on the mid-dorsal, supratip, and lateral aspects of the nose (Figure 1). How would you repair this defect?

Resolution

This is an interesting case in that a large defect on the dorsal nose was created by tumor excision, resulting in a challenging reconstructive dilemma. Our patient was experienced with reconstructive options following Mohs micrographic surgery given his extensive history of facial skin cancers. His concern with the ultimate cosmetic outcome, coupled with his insistence on the ease of postoperative care and rapidity of healing, was the basis of the resolution of this reconstructive conundrum.

Perhaps the easiest option in this situation would be a full-thickness skin graft (FTSG). FTSGs are useful for

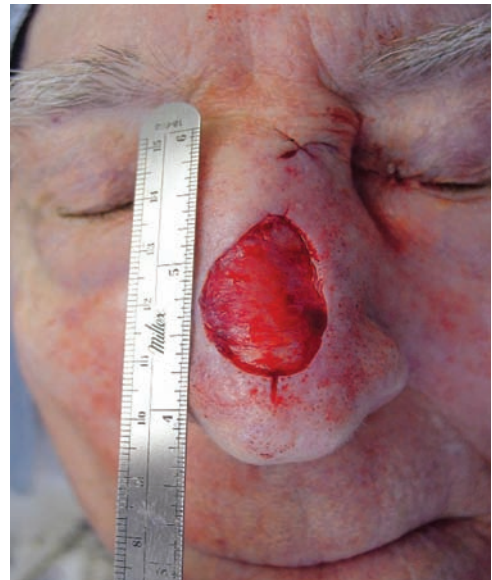

Figure 1 Anterior view of the nasal defect following Mohs micro-graphic surgery.

larger skin defects, given their simplicity, good cosmetic outcome, and lack of distortion of adjacent structures. The disadvantages of full-thickness grafting include the need for a donor site offering enough similar quality of skin for coverage, the possibilities of poor graft take and

poor color and texture match at the recipient site, and the need for a bulky bolster dressing for at least a week. In addition, given the depth and size of the defect at hand, a FTSG from the pre- or postauricular region may have resulted in a large secondary defect, which may have been difficult to close.

Second-intention healing is a time-honored method of healing that is especially useful for older patients with loose skin. Granulation and epithelialization of defects are often expected in 6 to 12 weeks, and the cosmetic results are often excellent. The advantages of this technique lie in its simplicity and lack of need for further surgical procedures for reparative needs. The disadvantages include the length of time for complete healing and the need for prolonged daily wound care. In addition, the cosmetic outcome following contracture of tissue with large defects is difficult to predict. As such, wound healing on convex surfaces such as the nose may result in hypertrophic scarring in the vicinity of free tissue margins and suboptimal outcomes.

A forehead flap for repair of large defects of the dorsal nose is another option for postoperative reconstruction. Many different designs of this two-stage flap have been described, but the paramedian or midline flaps are most commonly used and often give the best overall results. The vascular supply to these flaps is excellent, with good flap viability. A second procedure 2 to 3 weeks later is necessary to divide the resulting pedicle, and additional procedures may be necessary to debulk the flap further. A secondary donor site on the forehead is created that may be closed primarily but usually results in a visible scar. Second-intention healing may be necessary for larger secondary forehead donor sites. The main advantage of this reconstructive option is the large amount of skin that the forehead provides and its good color and texture match for nasal skin. Precise and detailed explanation of postoperative wound care and large bandages that may be necessary to cover what the patient may perceive to be a disfiguring flap on the face must be understood prior to pedicle take-down by the patient and family.

Our experience with vertical linear closures for defects of the dorsal nose has been outstanding, and, as such, it has become our closure of choice for midline and paramedian dorsal nasal lesions. The long-term postoperative cosmetic results are so good that we have tried to incorporate this closure for larger defects in this anatomic location. Tension resulting from closing

larger defects on the nasal dorsum may cause elevation of the nasal ala. Usually, this elevation is temporary, with improvement and resolution over the next few weeks. When there is a slight permanent residual raising of the ala, patients perceive an enhanced cosmetic look and an ease of breathing through the nostrils, which may help with snoring problems at night. Another result of the midline closure is thinning of the nasal tip, which results from the removal of the inferior dog-ear from this region. This has also been perceived by patients as a potential cosmetic benefit.

When repairing defects of the nasal dorsum, undermining of the lateral sides of the defect can be done at the subdermal level or above the cartilage and bone of the nasal sidewall. At this deep level, the undermining can be safely carried out onto the maxillary bone and cheek. This undermining provides a large amount of movement of skin medially. When using this wide undermining technique, even larger defects can be closed on the nasal dorsum. The vertical closure technique is thus more versatile for defects of larger sizes, which can be closed with excellent cosmetic results.

When a defect on the nasal dorsum is so large that an attempt to close primarily is unsuccessful, the superior or inferior dog-ear can be used as an FTSG to complete the closure. We initially tried to close this defect as a vertical linear closure but found that the superior dog-ear was needed as an FTSG to complete the closure. This technique is demonstrated in this case report.

In this case, the large defect following Mohs micrographic surgery could not be closed primarily despite wide lateral undermining (Figure 2). We chose to reconstruct this defect with a linear closure combined with a local Burow's (dog-ear) graft. A dog-ear was removed superiorly, and the resulting defect was closed in a linear side-to-side fashion using 5-0 subcutaneous buried poliglecaprone (Monocryl) sutures (Figure 3).

The Burow's (dog-ear) graft was then sutured centrally into the area of the defect that could not be closed primarily. To graft the dog-ear, 6-0 nylon (Ethilon) running sutures were used (Figure 4), and a bolster dressing was applied. The bolster dressing and sutures were removed after 1 week; the graft was pink, with 100% take (Figure 5).

Four-week follow-up results are shown in Figure 6. Elevation of the nasal ala is imperceptible, and the nasal passages are widely patent (Figure 7). The use of

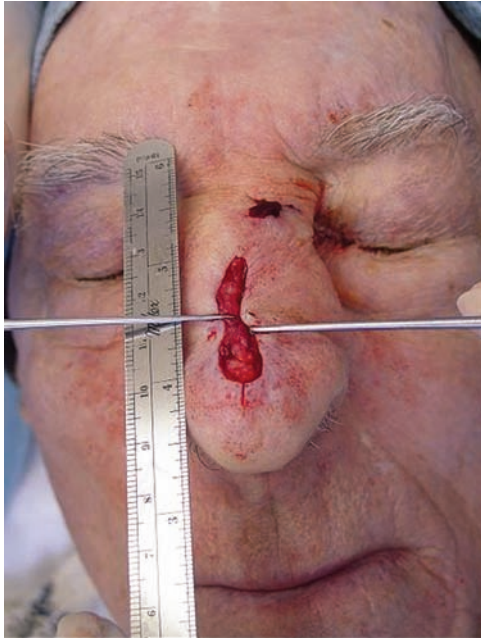

Figure 2 Anterior view showing inability to completely close the defect primarily.

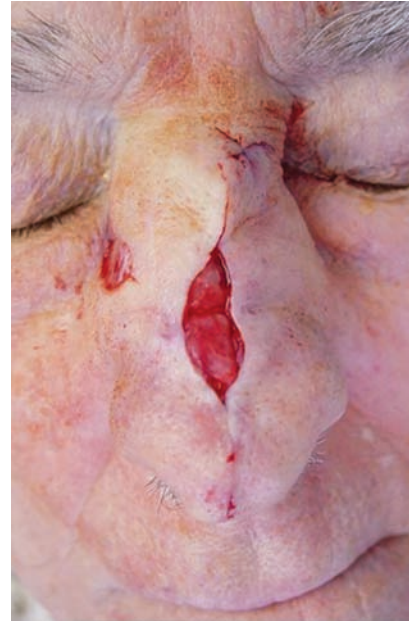
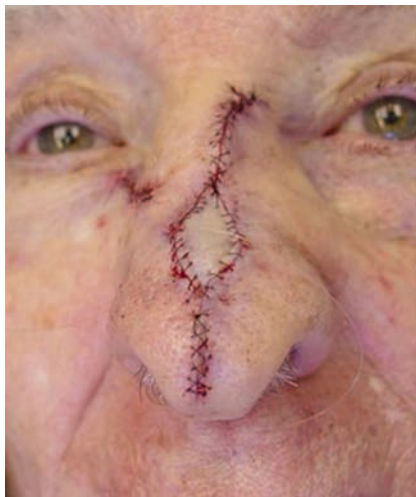
Figure 3 Removal of superior and inferior dog-ears prior to use as a full-thickness skin graft centrally.

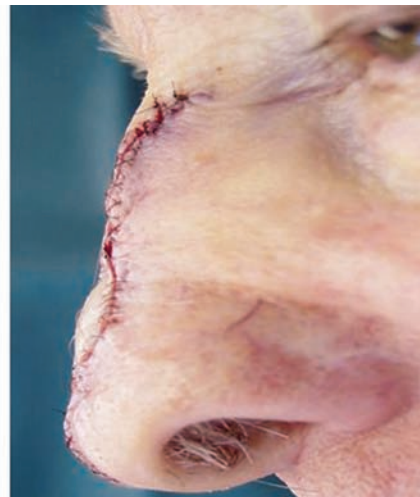local-tissue skin grafts from the nose allows for excellent cosmesis, with precise color and texture match. The patient was very pleased with the appearance of his nose and has not required further follow-up for scar revision.

Conundrum keys

- Large defects of the nose can be particularly challenging, but there are a vast number of reconstructive options for repair.



(a)



(b)

Figure 4 Anterior (a) and lateral (b) views of combined linear closure with a Burow's graft centrally.

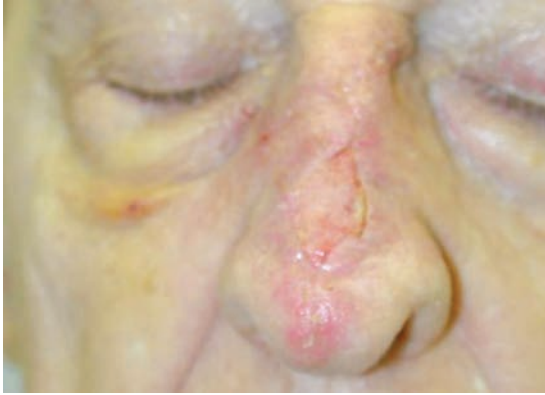

Figure 5 One-week follow-up.

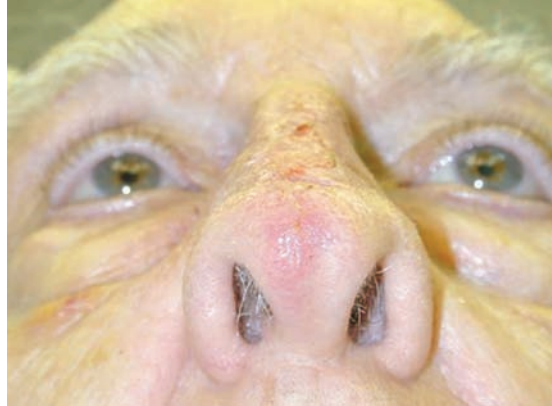

Figure 7 The nasal ala are widely patent, and elevation of the ala is imperceptible at 4 weeks.

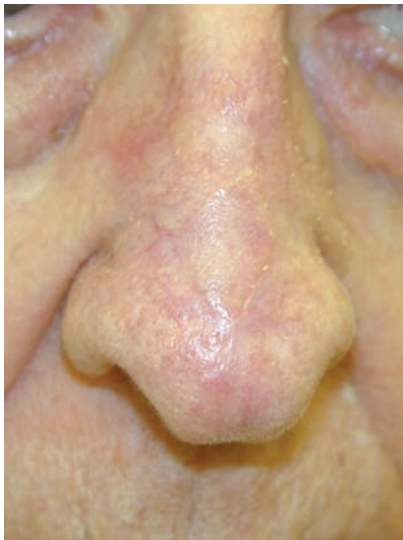

Figure 6 Four-week follow-up.

· When choosing a reconstructive option, both the patient and the surgeon must understand the pre- and

postoperative implications, complications, and potential outcomes of a chosen reparative option.

- Linear closures, when feasible, are an outstanding option for dorsal nasal defects.
- For larger dorsal nasal defects that are not amenable to complete primary closure, local Burow's grafts provide superb color and texture match and facilitate an excellent cosmetic outcome.

Additional readings

- Chester EC Jr. Closure of a surgical defect in a nose using island grafts from the nose. *J Dermatol Surg Oncol* 1982;8:790–1.
- Chester EC Jr. The use of dog-ears as grafts. *J Dermatol Surg Oncol* 1981;7:956–9.
- Cook J, Zitelli JA. Primary closure for mid-line defects of the nose: a simple approach for reconstruction. *J Am Acad Dermatol* 2000;43:508–10.
- Kaufman AJ. Adjacent-tissue skin grafts for reconstruction. *Dermatol Surg* 2004;30:1350–3.
- Zitelli JA. Burow's grafts. *J Am Acad Dermatol* 1987;17:271–9.

Commentary on conundrum 1

This case highlights several important principles in caring for patients with skin cancer. The first has to do with patients' involvement in choosing the reconstruction. As illustrated by the authors, there are a number of viable options for closure of this defect and early on, the authors imply that the patients were consulted regarding their goals and expectations for their repair. Every cutaneous surgeon has his or her own style. Some surgeons involve patients and allow them to play a significant part in determining which of several options they would prefer, while others make the decision independently. Neither extreme is ideal; soliciting the patient's participation is one facet of informed consent, and requires taking the time to assess patients' capacity to provide input and then clarifying their expectations. Some patients will gladly leave the entire decision process up to the surgeon, while others will give an opinion on how extensive a surgery they are willing to undergo and the level of cosmesis they require. This mutual participation process is invaluable in obtaining a reconstructive result that patients will find acceptable. However, it is surprising how often patients express a strong opinion on how involved a procedure they are willing to undergo, which may differ from the preconception of the surgeon. It would be advisable to have at least a preliminary conversation with patients regarding their goals and expectations.

The advantages and disadvantages of full-thickness skin graft closure are well known. The most common cause of a poor outcome with this method is the failure of continuous graft contact with the wound bed – which is usually avoidable – and if it occurs, will lead to an undesirable cosmetic result. It should be noted that in a case, such as this, in which the adjacent skin has been partially advanced, the depth of the wound base is often greater relative to the adjacent skin edges than it would have been otherwise. It is therefore even more important to assure graft contact with the wound base as there is a greater risk of unwanted lifting of these grafts from their recipient bed. Bolster dressings and basting sutures are effective ways to minimize this risk.

The second most common cause of partial graft failures is frictional trauma that avulses an area of the graft. Avulsion injury is most often seen when grafts are located

on more prominent or projecting facial sites such as the nose and ears, but can occur in any location. This type of injury most frequently occurs within a month of the procedure. After the initial dressing has been removed, it is prudent to advise the patient to wear a protective, cushion-like bandage for about a month after the surgery to minimize the risk of this complication.

The authors' description of the advantages of linear closure on the nose, as described by Cook and Zitelli, is excellent. Critical to optimization of this technique is extensive undermining of the skin lateral to the defect. Deep-plane undermining just above the periosteum and cartilage is most effective on the nose. As described, undermining carried out beyond the nasal sidewall onto the cheek often affords a quantum increase in tissue movement. A previously uncloseable wound can often achieve reapproximation merely by extending the plane of undermining onto the maxillary bone and cheek.

The authors also describe a "plan B" intraoperative decision. While it is always preferable to have a well-designed and workable plan preoperatively, the experienced surgeon realizes that having a backup plan, even one devised intraoperatively, can be invaluable.

As noted in Figure 3, the defect was reduced in size by 70%, which means that the majority of the wound was closed with perfectly matching adjacent skin. The concept of minimizing wound size when placement of a graft is contemplated is appropriate in most situations because minimizing graft size is generally desirable. However, when deciding upon the size of the graft to be harvested, the actual extent of the tissue loss, not the gaping wound, should be taken into consideration. The ideal scenario is to have the smallest possible graft filling the defect – with the graft stretched to its natural state of expansion. Assessing the true extent of tissue loss, which is usually less than the size of the defect due to the gaping phenomenon, is therefore critical because a correctly sized graft is esthetically superior to the one that is either oversized and redundant, or undersized and stretched to an unnatural degree.

In summary, on tight skin or in areas where tissue conservation needs to be at a premium, a Burow's graft combined with a partial closure can be an ideal solution. It is

important to note, however, that Burow's grafting necessitates a high degree of confidence that tumor-free margins have been obtained. A wound resulting from Mohs surgery fosters the ideal scenario for use of such adjacent grafts. However, when a wound results from excisional removal with less meticulous tissue examination

compared with the Mohs technique, the option of a Burow's graft should be considered much more cautiously, as unwittingly grafting tumor-containing skin into such a defect may result in a relatively rapid recurrence.

Commentary by Dr. Brodland

2

CONUNDRUM 2

Reconstruction of Two Nasal Defects Following Mohs Surgery

Alison O. Moon & Michael E. Lutz

Department of Dermatology, Mayo Clinic, Jacksonville, Florida

A 61-year-old woman had two defects involving the nose from Mohs micrographic surgery for basal cell carcinoma. The patient, an otherwise healthy non-smoker, was referred by her primary care physician for evaluation of a possible recurrent basal cell carcinoma of the nasal dorsum. On examination, a 5 mm × 7 mm area of hyperkeratotic erythema was observed. In addition, a 2 mm × 3 mm firm white papule was found on the right nasal ala, which the patient stated was new. Histologically both lesions were basal cell carcinoma.

After Mohs surgery the nasal dorsum defect was 1.0 cm in diameter and the nasal ala defect was 1.2 cm × 1.0 cm (Figure 1). How would you manage these wounds?

Resolution

There are several reconstructive options in this scenario. In our case, a primary closure of the midline defect of the nasal dorsum was designed with the additional intention to use the inferior Burow's triangle as a full-thickness skin graft for the alar defect. Although primary closure for nasal dorsum defects has not classically been considered an ideal option, this approach has been refined to yield predictable cosmetic results. In keeping with the technique advocated by Cook and Zitelli,¹ the standard 3:1 length/width ellipse design was extended to preserve the nasal profile. In our case, the inferior Burow's triangle was extended farther than the superior triangle to

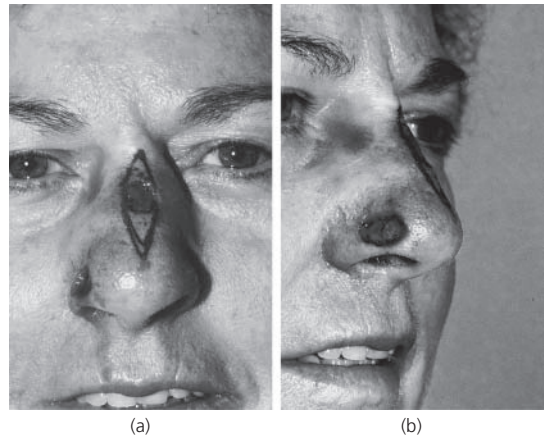


Figure 1 a) Defect on the nasal dorsum after excision. b) Defect on the nasal ala after excision.

provide sufficient graft tissue. With meticulous trimming, defatting, and contouring to fit the graft bed dimensions, the donor skin reproduced the normal external contour of the ala. This tissue was an ideal donor site for the nasal ala for color, sebaceous texture, and thickness (Figure 2).

Because the patient was a nonsmoker and in good health, she was considered an acceptable candidate for a full-thickness graft. The long-term results were cosmetically pleasing, with minimal discordance between the graft and surrounding skin (Figure 3). There was no distortion of the nasal profile.

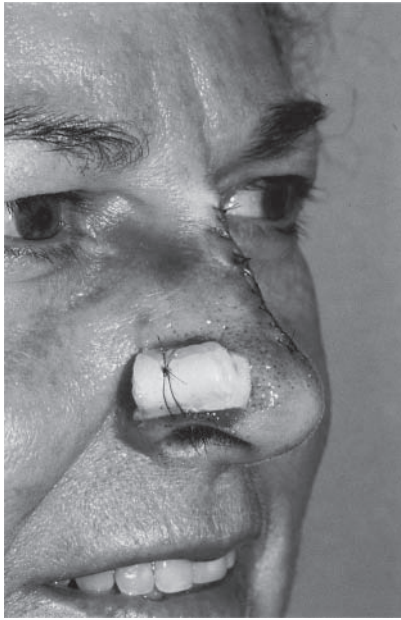

Figure 2 Immediately after reconstruction.

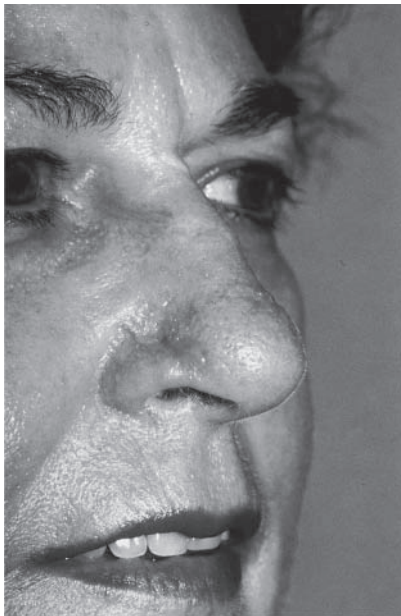


Figure 3 Two months after reconstruction.

Other options for reconstructing the nasal ala include a nasolabial transposition flap or a bilobed transposition flap; however, these often distort or ablate the alar groove.

An alternative reconstructive approach is the nasolabial interpolation flap; however, this is a staged procedure and can be cumbersome for the patient postoperatively. In addition, more cosmetic units are involved with these methods. In repairing the nasal ala, allowing the wound to heal by second intention results in a poor texture match as well as wound contraction that may distort the free margin of the alar rim. Also, the resulting scar contracture may lead to nasal valve malfunction because of elevation of the alar margin. This causes the alar and lateral cartilages to move inward, thereby rendering the nasal valve immobile. This may also be a consideration for the other flap reconstruction options.

When evaluating various reconstruction options, alteration of sensation should be considered. Although the recovery of sensory innervation occurs earlier with flaps than with grafts, sensation of the nasal ala is less critical than for other facial sites.

Conundrum keys

- If there is more than one defect on the nose, including the nasal ala and dorsum, consider primary closure of the dorsal defect using a Burow's triangle as a full-thickness donor site. There is no better match for the ala than this nearby skin.
- Tailor the size of the Burow's triangle to accommodate the recipient site.
- Keep the number of involved cosmetic units to a minimum.

Reference

- 1 Cook JL, Zitelli JA. Primary closure for midline defects of the nose: a simple approach for reconstruction. *J Am Acad Dermatol* 2000; 43:508-10.

Commentary

Drs. Moon and Lutz present a technique of reconstruction for multiple defects that is virtuous in not only the excellent results it provides but also in its efficient use of tissue and hence tissue conservation. The side-to-side closure of the defect on the mid-line nasal dorsum is a simple, reliable, and reproducible reconstructive technique recently advocated by Cook and Zitelli. The use of a Burow's triangle as a graft for reconstruction of another

defect has several important implications. First, the surgeons must be as certain as possible that the graft skin does not contain either residual tumor or additional primary skin cancers. The former is assured by microscopic margin control as accomplished by the authors with the use of the Mohs micrographic surgical technique. Careful inspection preoperatively of the prospective graft skin is the best way to ensure the absence of second primary tumors being transferred into the other defect. Studies

performed 30–40 years ago on the transplantability of basal cell carcinoma indicate that it is not transplantable. I believe, based on anecdotal experience, that BCC can be transplanted within a full-thickness skin graft provided the tumor is a small percentage of the total graft. Squamous cell carcinoma is thought to be transplantable based on experimental models.

DAVID BRODLAND, MD *Clairton, Pennsylvania*