



# **Radiology** **at a Glance**

**Rajat Chowdhury**

**Iain Wilson**

**Christopher Rofe**

**Graham Lloyd-Jones**

 **WILEY-BLACKWELL**



# Radiology at a Glance



# Radiology at a Glance

## **Rajat Chowdhury**

MA (Oxon), MSc, BM BCh, MRCS  
Specialist Registrar in Clinical Radiology  
Southampton General Hospital, UK  
Chair of the British Institute of Radiology Trainee Committee

## **Iain D. C. Wilson**

MEng (Oxon), BMedSci, BM BS, MRCS  
Specialist Registrar in Clinical Radiology  
Southampton General Hospital, UK

## **Christopher J. Rofe**

BSc, MB BCh, MRCP  
Specialist Registrar in Clinical Radiology  
Southampton General Hospital, UK

## **Graham Lloyd-Jones**

BA, MB BS, PCME, MRCP, FRCR  
Consultant Radiologist  
Salisbury District Hospital, UK

 **WILEY-BLACKWELL**

A John Wiley & Sons, Ltd., Publication

This edition first published 2010, © 2010 by Rajat Chowdhury, Iain Wilson, Christopher Rofe, Graham Lloyd-Jones

Blackwell Publishing was acquired by John Wiley & Sons in February 2007. Blackwell's publishing program has been merged with Wiley's global Scientific, Technical and Medical business to form Wiley-Blackwell.

*Registered office:* John Wiley & Sons Ltd, The Atrium, Southern Gate, Chichester, West Sussex, PO19 8SQ, UK

*Editorial offices:* 9600 Garsington Road, Oxford, OX4 2DQ, UK  
The Atrium, Southern Gate, Chichester, West Sussex, PO19 8SQ, UK  
111 River Street, Hoboken, NJ 07030-5774, USA

For details of our global editorial offices, for customer services and for information about how to apply for permission to reuse the copyright material in this book please see our website at [www.wiley.com/wiley-blackwell](http://www.wiley.com/wiley-blackwell)

The right of the authors to be identified as the authors of this work has been asserted in accordance with the Copyright, Designs and Patents Act 1988.

All rights reserved. No part of this publication may be reproduced, stored in a retrieval system, or transmitted, in any form or by any means, electronic, mechanical, photocopying, recording or otherwise, except as permitted by the UK Copyright, Designs and Patents Act 1988, without the prior permission of the publisher.

Wiley also publishes its books in a variety of electronic formats. Some content that appears in print may not be available in electronic books.

Designations used by companies to distinguish their products are often claimed as trademarks. All brand names and product names used in this book are trade names, service marks, trademarks or registered trademarks of their respective owners. The publisher is not associated with any product or vendor mentioned in this book. This publication is designed to provide accurate and authoritative information in regard to the subject matter covered. It is sold on the understanding that the publisher is not engaged in rendering professional services. If professional advice or other expert assistance is required, the services of a competent professional should be sought.

*Library of Congress Cataloging-in-Publication Data*

Radiology at a glance / Rajat Chowdhury . . . [et al.].

p. ; cm. – (At a glance series)

Includes index.

ISBN 978-1-4051-9220-0

I. Radiology, Medical—Outlines, syllabi, etc. I. Chowdhury, Rajat. II. Series: At a glance series (Oxford, England)

[DNLM: 1. Diagnostic Imaging. WN 180 R12885 2010]

R896.5.R33 2010

616.07'54—dc22

2009035145

ISBN: 9781405192200

A catalogue record for this book is available from the British Library.

Set in 9 on 11.5 pt Times by Toppan Best-set Premedia Limited

Printed in Singapore

1 2010

# Contents

- Foreword 6  
Preface and Acknowledgements 7  
Abbreviations and Terminology 8
- Part 1 Radiology physics**  
1 Plain X-ray (XR) imaging 10  
2 Fluoroscopy 12  
3 Ultrasound (US) 14  
4 Computed tomography (CT) 16  
5 Magnetic resonance imaging (MRI) 18
- Part 2 Radiology principles**  
6 Radiation protection and contrast agent precautions 20  
7 Making a radiology referral 22  
8 Which investigation: classic cases 24
- Part 3 Plain XR imaging**  
9 CXR checklist and approach 26  
10 CXR anatomy 28  
11 CXR classic cases I 30  
12 CXR classic cases II 32  
13 CXR classic cases III 34  
14 CXR classic cases IV 36  
15 AXR checklist and approach 38  
16 AXR anatomy 40  
17 AXR classic cases I 42  
18 AXR classic cases II 44  
19 Extremity XR checklist and approach 46  
20 Extremity XR anatomy I: upper limb 48  
21 Extremity XR anatomy II: pelvis and lower limb 50  
22 Upper limb XR classic cases I: shoulder and elbow 52  
23 Upper limb XR classic cases II: forearm, wrist and hand 54  
24 Hip and pelvis XR classic cases 56  
25 Lower limb XR classic cases: knee, ankle and foot 58  
26 Face XR anatomy and classic cases 60
- Part 4 Fluoroscopic imaging**  
27 Fluoroscopy checklist and approach 62  
28 Fluoroscopy classic cases 64
- Part 5 Ultrasound imaging**  
29 US checklist and approach 66  
30 US classic cases 68
- Part 6 CT imaging**  
31 CT checklist and approach 70  
32 Chest CT anatomy 72  
33 Chest CT classic cases I 74  
34 Chest CT classic cases II 76  
35 Abdominal CT anatomy 78  
36 Abdominal CT classic cases I 80  
37 Abdominal CT classic cases II 82  
38 Head CT anatomy 84  
39 Head CT classic cases 86
- Part 7 Specialised imaging and MRI**  
40 IVU and CT KUB 88  
41 CT and MR angiography 90  
42 MRI checklist and approach 92  
43 Head MR and classic cases 94  
44 Cervical spine imaging anatomy and approach 96  
45 Cervical spine imaging classic cases 98  
46 Spine MR classic cases 100
- Part 8 Interventional radiology**  
47 Principles of interventional radiology 102  
48 Interventional radiology classic cases 104
- Part 9 Nuclear medicine**  
49 Principles of nuclear medicine 106  
50 Nuclear medicine classic cases 108
- Part 10 Self assessment**  
Radiology OSCE, case studies and questions 110  
Answers 114
- Index 116

# Foreword

As a medical student in the early 1970s I rarely ventured to the X-ray department, which seemed a dark and mysterious place. However, change was in the air. CT and ultrasound were beginning to make their mark and were revolutionising the management of patients. More and more often, erudite discussions on the ward ended with 'let's see what the radiologists think'.

Imaging is rapidly replacing the physician's palpating hand and the needle is taking the place of the surgeon's scalpel. The transition is not yet complete but the trend is clear: diagnostic imaging and interventional radiology are playing an increasingly important role in diagnosis and therapy and are set to determine the flow of patients through 21<sup>st</sup> century hospitals. It is, therefore, essential that medical students and young doctors become more familiar with the opportunities that modern imaging can offer.

This excellent book by Drs Rajat Chowdhury, Iain Wilson, Christopher Rofe and Graham Lloyd-Jones manages to cover all the essential aspects of modern imaging. Its approach is particularly suited to the intended readership, as the emphasis is on the most important findings and on the impact of radiology on clinical practice rather than

on radiological minutiae. *Radiology at a Glance* is an excellent guide on how best to use a radiology department, and to request the diagnostic imaging test that is likely to provide the answer to the clinical condition being investigated. It also covers essential aspects of radiological technology, to help demystify modern imaging techniques, and provides a very necessary understanding of radiation protection. The increasingly important role of interventional radiology is also explained, as well as the opportunities it offers to replace traditional surgical techniques for many conditions.

I am sure that this book will be a very valuable companion to traditional medical textbooks and that it will help medical students and young doctors become more effective in their work by using modern radiology departments to the best advantage of their patients.

*Andy Adam*

*President of The Royal College of Radiologists  
Professor of Interventional Radiology, Guy's King's and  
St. Thomas' School of Medicine, University of London*

# Preface and Acknowledgements

The *at a Glance* series has served us well through our careers and we felt that it was time that the specialty of radiology was also given the *at a Glance* treatment. We present *Radiology at a Glance* in this classic style to help teach the basics of radiology in a simple and clear fashion. Since the GMC published 'Tomorrow's Doctors' in 1993, medical schools have restructured their curricula to include clinically integrated teaching. This has meant detailed factual learning has been replaced with a more focused and clinically orientated medical course, including radiological images from the outset of the programme. With this in mind, we have also included radiological anatomy and covered conditions that regularly appear in medical school exams. These 'classic cases' are found in separate chapters allowing easy access for doctors on the wards.

We have written this book not only with medical students and junior doctors in mind, but trust that it will be a useful aid to students of radiography, nursing and physiotherapy, as well as other health professionals. We therefore hope it will be a valuable tool in gaining an understanding of the essentials of clinical radiology.

We would like to express our gratitude to all the consultants and teachers at Southampton General Hospital and to the Wessex Radiology Training Programme for their inspiration, meticulous teaching and expert guidance. We extend warm thanks to Professor Andy Adam for giving his precious seal of approval for this venture. We would also like to thank our publishers, in particular Ben Townsend and Laura Murphy, for showing such enthusiasm for all our ideas and turning them into reality. We would like to dedicate this book to our families who have supported us through this great experience. Finally, we thank all our readers for taking the time to read this book, and in return we hope you feel it was time well spent.

*Rajat Chowdhury  
Iain D. C. Wilson  
Christopher J. Rofe  
Graham Lloyd-Jones*

# Abbreviations

#	fracture	ICH	intracerebral haemorrhage
AAA	abdominal aortic aneurysm	ICP	intracranial pressure
ACL	anterior cruciate ligament	ID	identification details
ADC	apparent diffusion coefficient	INR	international normalised ratio
ALARA	as low as reasonably achievable	IR	interventional radiology
AP	anterior to posterior	IR(ME)R 2000	Ionising Radiation (Medical Exposure) Regulations 2000
APTT	activated partial thromboplastin time	IRR99	Ionising Radiation Regulations 1999
ARDS	acute respiratory distress syndrome	IV	intravenous
ARSAC	Administration of Radioactive Substances Advisory Committee	IVC	inferior vena cava
ATLS	Advanced Trauma Life Support	IVU	intravenous urography
AVN	avascular necrosis	LBO	large bowel obstruction
AXR	abdominal X-ray	LLL	left lower lobe
Ba	barium	LOS	lower oesophageal sphincter
CIN	contrast-induced nephropathy	LRTI	lower respiratory tract infection
CBD	common bile duct	LUL	left upper lobe
COPD	chronic obstructive pulmonary disease	LV	left ventricle
CPPD	calcium pyrophosphate dehydrate	LVF	left ventricular failure
CR	computed radiography	MAG3	mercaptoacetyl triglycine
CSF	cerebrospinal fluid	MARS	Medicines (Administration of Radioactive Substances) Regulations
CT	computed tomography	MEN	multiple endocrine neoplasia
CTA	computed tomographic angiography	MCPJ	metacarpophalangeal joint
CTKUB	computed tomography of kidneys, ureters and bladder	MDP	methylene diphosphonate
CTPA	computed tomographic pulmonary angiography	MR(I)	magnetic resonance (imaging)
CXR	chest X-ray	MRA	magnetic resonance angiography
DEXA	dual energy X-ray absorptiometry	MRCP	magnetic resonance cholangiopancreatography
DIC	disseminated intravascular coagulation	MUGA	multi-gated acquisition
DIPJ	distal interphalangeal joint	NBM	nil by mouth
DMSA	dimercaptosuccinic acid	Neuro	neurological
DOB	date of birth	NGT	nasogastric tube
DP	dorsal to plantar	NM	nuclear medicine
DR	digital radiography	NSAID	non-steroidal anti-inflammatory drug
DRUJ	distal radioulnar joint	NSF	nephrogenic systemic fibrosis
DTPA	diethylene triamine pentaacetic acid	N-STEMI	non-ST elevation myocardial infarction
DVT	deep vein thrombosis	OA	osteoarthritis
DWI	diffusion-weighted (magnetic resonance) imaging	OSCE	Objective Structured Clinical Examination
Echo	echocardiography	OGD	oesophagogastroduodenoscopy
EDH	extradural haemorrhage/haematoma	OM	occipitomenal view
eGFR	estimated glomerular filtration rate	OPG	orthopantomogram
EndoUS	endoultrasound	PA	posterior to anterior
ERCP	endoscopic retrograde cholangiopancreatography	PACS	picture archiving and communications system
EVAR	endovascular aneurysm repair	PCI	percutaneous coronary intervention
FB	foreign body	PCL	posterior cruciate ligament
FDG	fluorodeoxyglucose	PCNL	percutaneous nephrolithotomy
FEV <sub>1</sub>	forced expiratory volume in 1st second	PCS	pelvicalyceal system
FLAIR	fluid attenuated inversion recovery	PD	proton density
FVC	forced vital capacity	PE	pulmonary embolus
FNAC	fine-needle aspiration cytology	PET	positron emission tomography
GI	gastrointestinal	PET-CT	combined positron emission tomography with computed tomography
GORD	gastro-oesophageal reflux disease	PICC	peripherally inserted central catheter
HIV	human immunodeficiency virus	PIPJ	proximal interphalangeal joint
HRCT	high resolution computed tomography	PT	prothrombin time
IBD	inflammatory bowel disease	PTC	percutaneous transhepatic cholangiography
ICD	implantable cardioverter defibrillator		

<b>PUD</b>	peptic ulcer disease
<b>RA</b>	right atrium
<b>RCR</b>	Royal College of Radiologists
<b>RFA</b>	radiofrequency ablation
<b>RLL</b>	right lower lobe
<b>(R)ML</b>	(right) middle lobe
<b>RUL</b>	right upper lobe
<b>RUQ</b>	right upper quadrant
<b>RV</b>	right ventricle
<b>SAH</b>	subarachnoid haemorrhage
<b>SBO</b>	small bowel obstruction
<b>SDH</b>	subdural haemorrhage/haematoma
<b>SIJ</b>	sacroiliac joint
<b>SOL</b>	space occupying lesion
<b>SPECT</b>	single photon emission computed tomography

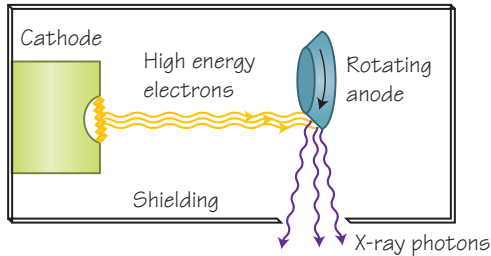
<b>STEMI</b>	ST elevation myocardial infarction
<b>STIR</b>	short tau inversion recovery
<b>SVC</b>	superior vena cava
<b>TACE</b>	transarterial chemoembolisation
<b>TB</b>	tuberculosis
<b>Tc-99m</b>	metastable technetium-99
<b>TFCC</b>	triangulofibrocartilage complex
<b>TIA</b>	transient ischaemic attack
<b>TIPS</b>	transjugular intrahepatic portosystemic shunt
<b>TNM</b>	tumour, nodes, metastases
<b>UGI</b>	upper gastrointestinal
<b>US</b>	ultrasound
<b>V/Q</b>	ventilation-perfusion
<b>XR</b>	X-ray

## Terminology

<b>Attenuation</b>	Gradual loss in intensity of beams and waves including X-rays and ultrasound waves. May also be used synonymously with 'density' to describe appearances on CT imaging (areas of high attenuation are bright whereas areas of low attenuation are dark).	<b>PACS</b>	The 'picture archiving and communication systems' are computer networks that store, retrieve, distribute and present medical images electronically. This permits images to be viewed and manipulated digitally on screen with remote and instant access by multiple users simultaneously and has therefore almost replaced the use of hard-copy films in the UK.
<b>Density</b>	Used synonymously with 'attenuation' to describe appearances on CT imaging (areas of high density are bright whereas areas of low density are dark).	<b>Reflectivity</b>	Used synonymously with 'echogenicity' to describe appearances on ultrasound imaging (hyperreflective areas are bright whereas hyporeflexive areas are dark).
<b>Echogenicity</b>	Used synonymously with 'reflectivity' to describe appearances on ultrasound imaging (hyperechoic areas are bright whereas hypoechoic areas are dark).	<b>Signal</b>	Used to describe appearances on MR imaging (areas of high signal are bright whereas areas of low signal are dark).
<b>Hotspot/Coldspot</b>	Used to describe the uptake of radiopharmaceutical agents by tissues in nuclear medicine imaging (increased uptake results in a hotspot whereas reduced uptake results in a coldspot).		

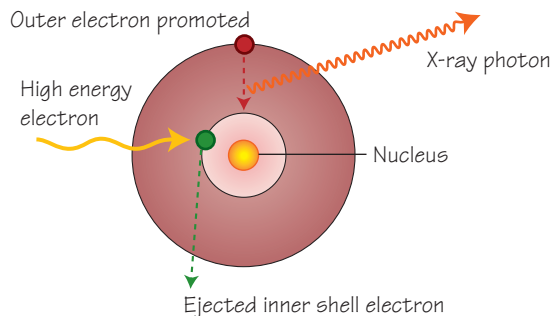
# 1 Plain X-ray (XR) imaging

## 1.1 The X-ray machine



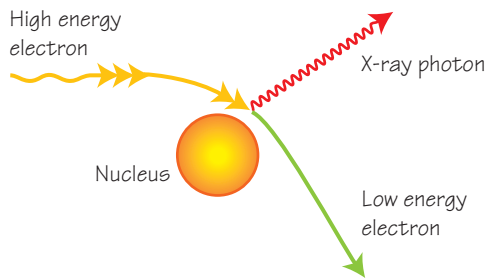
A stream of high energy electrons produced by an electron gun accelerate from a cathode filament and strike a rotating tungsten anode. X-ray photons are generated within the anode which rotates to dissipate heat. The beam of X-ray photons is shielded and coned to reduce the scatter of X-rays produced

## 1.2 Characteristic radiation generation



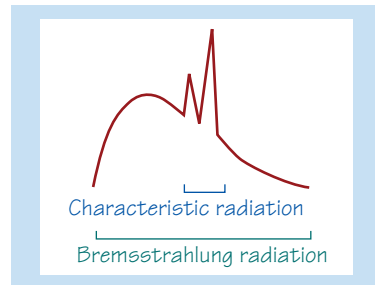
High energy electrons collide with and eject an inner shell tungsten electron (green) with subsequent promotion of an outer shell electron (red) to take its place. X-ray photons of a uniform 'characteristic' energy are generated

## 1.3 Bremsstrahlung radiation



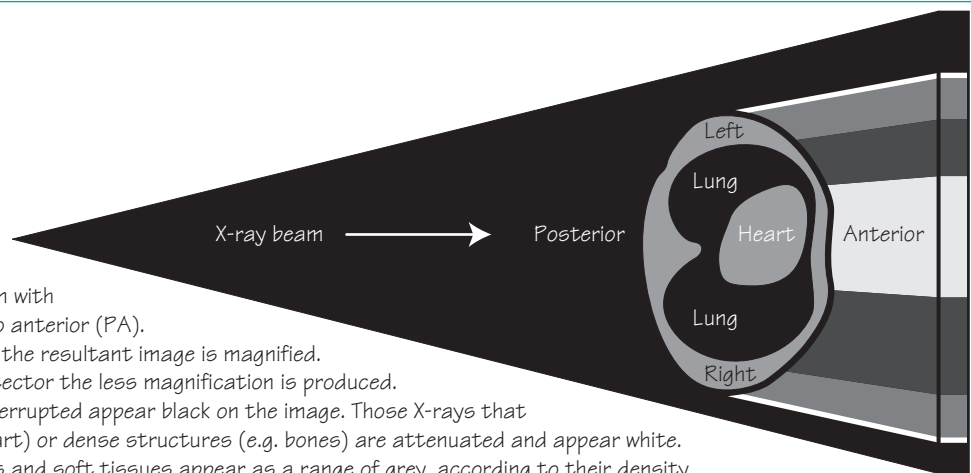
A high energy electron that passes near a tungsten nucleus is deflected and decelerated with generation of an X-ray photon. X-ray photons of variable energy are generated in this way and therefore a non-uniform energy spectrum is produced. This is known as Bremsstrahlung 'Braking' radiation

## 1.4 The X-ray spectrum



Bremsstrahlung radiation produces a wide spectrum of X-ray energies within the X-ray beam. Characteristic radiation generation however produces a relatively narrow band of X-ray energy. Imaging techniques optimise this characteristic band of X-rays in producing a radiograph

## 1.5 Image generation



A chest X-ray (CXR) is usually taken with the beam passing from posterior to anterior (PA). The X-ray beam is divergent and so the resultant image is magnified. The closer the patient is to the detector the less magnification is produced. X-rays which hit the detector uninterrupted appear black on the image. Those X-rays that pass into thick structures (e.g. heart) or dense structures (e.g. bones) are attenuated and appear white. Other structures such as the lungs and soft tissues appear as a range of grey, according to their density

## Plain XR physics

On 8 November 1895, the German physicist Wilhelm Conrad Röntgen discovered the X-ray, a form of electromagnetic radiation which travels in straight lines at approximately the speed of light. X-rays therefore share the same properties as other forms of electromagnetic radiation and demonstrate characteristics of both waves and particles. X-rays are produced by interactions between accelerated electrons and atoms. When an accelerated electron collides with an atom two outcomes are possible:

1 An accelerated electron displaces an electron from within a shell of the atom. The vacant position left in the shell is filled by an electron from a higher level shell, which results in the release of X-ray photons of uniform energy. This is known as *characteristic radiation*.

2 Accelerated electrons passing near the nucleus of the atom may be deviated from their original course by nuclear forces and thereby transfer some energy into X-ray photons of varying energies. This is known as *Bremsstrahlung radiation*.

The resultant beam of X-ray photons (X-rays) interacts with the body in a number of ways:

- *Absorption* – this prevents the X-rays reaching the X-ray detector plate. Absorption contributes to patient dose and therefore increases the risk of potential harm to the patient.
- *Scatter* – scattering of X-rays is the commonest source of radiation exposure for radiological staff and patients. It also reduces the sharpness of the image.
- *Transmitted* – transmitted X-rays penetrate completely through the body and contribute to the image obtained by causing a uniform blackening of the image.
- *Attenuation* – an X-ray image is composed of transmitted X-rays (black) and X-rays which are attenuated to varying degrees (white to grey). Attenuation can be thought of as a sum of absorption and scatter and is determined by the thickness and density of a structure. In the chest, structures such as the lungs are relatively thick but contain air, making them low in density. The lungs therefore transmit X-rays easily and appear black on the X-ray image. Conversely, bones are not thick but are very dense and therefore appear white. Attenuation can be controlled by varying the power or 'hardness' of the X-ray beam.

## The XR machine (tube)

Most modern radiographic machines use electron guns to generate a stream of high energy electrons, which is achieved by heating a filament. The high energy electrons are accelerated towards a target anode. The electrons hit the anode, thereby generating X-rays as described above. This process is very inefficient with 99% of this energy transferred into heat at 60kV. The dissipation of heat is therefore a key design feature of these machines to sustain their use and maintain their longevity. The material for the target anode is selected depending on the chosen task and the energy of the X-ray beam can be modified by filtration to produce beams of uniform energy.

Most modern radiology departments now employ digital imaging techniques and there are two principal methods in everyday use: com-

puted radiography (CR) and digital radiography (DR). CR uses an exposure plate to create a latent image which is read by a laser stimulating luminescence, before being read by a digital detector. DR systems convert the X-ray image into visible light which is then captured by a photo-voltage sensor that converts the light into electricity, and thus a digital image. The final digital images are stored in medical imaging formats and displayed on computer terminals.

## Applying physics to practice

- If the subject to be imaged is placed further from the detector, the image created will be magnified. This is based on the principle that X-ray beams travel in diverging straight lines.
- Scatter from the patient and other objects degrades the resolution. This will cause the image to be blurred.
- Beams of lower energy are absorbed more than beams of higher energy. This affects the difference in clarity between the soft tissue detail and artefact.

## Image quality

The clarity of the image can be expressed as 'unsharpness'. This can be classified into:

- *Inherent unsharpness* – this is caused by the structures involved not having sharp, well-defined edges.
- *Movement unsharpness* – this can be reduced by using short exposures, as with light photography.
- *Photographic unsharpness* – this is dependent on the quality and type of imaging equipment and the method of capturing the image. Newer digital imaging systems now allow the post-processing of data to enhance various aspects of the image.

## Contrast

The contrast of an image is dependent on the variation of beam attenuation within the subject. There are *five principal densities* that can be seen on a plain radiographic image.

### Plain XR densities

• <b>Black</b>	Air/gas
• <b>Dark grey</b>	Fat
• <b>Light grey</b>	Soft tissue/fluid
• <b>White</b>	Bone and calcified structures
• <b>Bright white</b>	Metal

The contrast may be increased by lowering the energy of the X-ray beam. However, this has negative impact on image quality and increases the dose of radiation.

Contrast agents are often used to enhance anatomical detail. A desirable contrast agent is one that has high photoelectric absorption at the energy of the X-ray beam. The contrast agents most commonly used in plain X-ray imaging are barium, gastrografin (water soluble) and iodinated compounds. Precautions in the use of iodinated contrast agents are discussed in Chapter 6.

## Advantages and disadvantages of plain XR imaging

### Advantages

- Inexpensive
- Fast
- Simple
- Readily available

### Disadvantages

- Radiation exposure
- Imaging three-dimensional structures in a two-dimensional format
- Low tissue contrast
- Overlapping anatomy
- No dynamic or functional information