

ANN FELTON
ALISON CHAPMAN AND SIMON FELTON

Basic Guide to
**ORAL HEALTH
EDUCATION AND
PROMOTION**



Blackwell
Munksgaard

Basic Guide to Oral Health Education and Promotion

Love your patients and they will do anything that you ask.

Ann Felton (1942–2007)

Ann Felton made people smile and their smiles brighter. Ann was a dental hygienist, tutor and mentor, and ran her own oral health education course for dental nurses whom she referred to as ‘the darlings of dentistry’.

Ann wrote the majority of this book in difficult circumstances, yet retained her love for the subject and sense of humour throughout. This text is dedicated to Ann’s life and work in making people smile.

BASIC GUIDE TO ORAL HEALTH EDUCATION AND PROMOTION

Ann Felton

RDH, Cert. Ed

Alison Chapman

RDH, FAETC

Edited by

Simon Felton

BSc (Hons), LSJ (Hons Dip)



WILEY-BLACKWELL

A John Wiley & Sons, Ltd., Publication

This edition first published 2009
© 2009 A. Felton, A. Chapman, & S. Felton

Blackwell Publishing was acquired by John Wiley & Sons in February 2007.
Blackwell's publishing programme has been merged with Wiley's global Scientific, Technical,
and Medical business to form Wiley-Blackwell.

Registered office
John Wiley & Sons Ltd, The Atrium, Southern Gate, Chichester, West Sussex, PO19 8SQ,
United Kingdom

Editorial offices
9600 Garsington Road, Oxford, OX4 2DQ, United Kingdom
2121 State Avenue, Ames, Iowa 50014-8300, USA

For details of our global editorial offices, for customer services and for information about how to
apply for permission to reuse the copyright material in this book please see our website at
www.wiley.com/wiley-blackwell.

The right of the author to be identified as the author of this work has been asserted in accordance
with the Copyright, Designs and Patents Act 1988.

All rights reserved. No part of this publication may be reproduced, stored in a retrieval system, or
transmitted, in any form or by any means, electronic, mechanical, photocopying, recording or
otherwise, except as permitted by the UK Copyright, Designs and Patents Act 1988, without the
prior permission of the publisher.

Wiley also publishes its books in a variety of electronic formats. Some content that appears in
print may not be available in electronic books.

Designations used by companies to distinguish their products are often claimed as trademarks.
All brand names and product names used in this book are trade names, service marks, trademarks
or registered trademarks of their respective owners. The publisher is not associated with any
product or vendor mentioned in this book. This publication is designed to provide accurate and
authoritative information in regard to the subject matter covered. It is sold on the understanding
that the publisher is not engaged in rendering professional services. If professional advice or other
expert assistance is required, the services of a competent professional should be sought.

Library of Congress Cataloging-in-Publication Data

Felton, Ann.
Basic guide to oral health education and promotion / Ann Felton, Alison Chapman;
edited by Simon Felton.
p. ; cm.

Includes bibliographical references and index.
ISBN 978-1-4051-6162-6 (pbk. : alk. paper) 1. Dental health education.
2. Health promotion. I. Chapman, Alison, II. Felton, Simon, 1970– III. Title.
[DNLM: 1. Health Education, Dental – methods. 2. Dental Assistants. 3. Health
Promotion – methods. WU 113 F326 2009]

RK60.8.F45 2009
617.6'01 – dc22

2008039842

A catalogue record for this book is available from the British Library.

Set in 10/12.5 pt Sabon by Aptara Inc., New Delhi, India
Printed and bound in Malaysia by KHL Printing Co Sdn Bhd

Contents

<i>Foreword</i>	vii
<i>Preface</i>	ix
<i>Acknowledgements</i>	x
SECTION 1: Structure and Functions of the Oral Cavity	1
1 The oral cavity in health	5
SECTION 2: Diseases and Conditions of the Oral Cavity	23
2 Plaque, calculus and staining	27
3 Chronic gingivitis	37
4 Chronic periodontitis	43
5 Other common oral diseases and conditions	50
6 Caries	73
7 Tooth surface loss and sensitivity	84
8 Xerostomia	95
SECTION 3: Oral Disease Prevention	99
9 Food, glorious food	103
10 Sugars in the diet	108
11 Fluoride	116
12 Fissure sealants	128
13 Smoking cessation	133
SECTION 4: Delivering Oral Health Messages	139
14 Communication	143
15 Principles of education	149
16 Setting up a preventive dental unit (PDU)	159
17 Planning an oral hygiene session	164
18 Anti-plaque agents	168
19 Practical oral hygiene instruction	176
SECTION 5: Oral Health Target Groups and Case Studies	189
20 Pregnant and nursing mothers	193
21 Parents of pre-11-year-olds	200
22 Adolescents and orthodontic patients	207
23 Older people	215
24 At risk and special care patients	225

25	Minority ethnic populations in the UK	232
26	Other health professionals	236
27	Planning education case studies	240
	SECTION 6: Oral Health and Society	249
28	Sociology	253
29	Epidemiology	258
30	Evidence-based prevention	266
31	UK dental services	270
32	Oral health promotion	276
	<i>Index</i>	281

Foreword

Ann Felton and Alison Chapman have between them more than 30 years of experience in the delivery and training of oral health education. Ann designed, and has run with Alison, an exceptionally successful oral health education course in Bristol for over 10 years, with a pass rate of over 95% in the UK national examination.

This has given them great experience and understanding of the subject and the needs of students. The delivery of dental care is undergoing fundamental changes and the need to develop practice teams with skill mix makes this book very timely. Practices may well need to consider how they can make best use of their staff to help deliver oral care to their patients in the future, and oral health educators could well become an important part of this process.

This book provides a most comprehensive review of the subject. Each chapter has clearly defined learning outcomes that make it easy to read and understand. It is an ideal revision aid and basis for any member of the dental team and other health professionals wishing to know about all the aspects of oral health education. It would also be a good reference book for all practices on the subject.

Alasdair Miller
BDS, FDSRCS (Ed), DGDP, DPDS
Regional Dental Postgraduate Dean (South West)
University of Bristol

Preface

Oral health is central to our general well-being. The health of the body begins with the oral cavity, since all our daily nutrients, beneficial or otherwise, pass through it.

Knowledge in the field of oral health is changing rapidly and there is a great deal to learn. Patients need trained oral health educators (OHEs) and promoters to help prevent and control dental conditions and disease. It is vital that dental and health professionals consistently promote the same messages to avoid confusion and ultimately improve oral health within the population.

This book covers the theoretical and practical aspects of oral health education and promotion, and is the course companion for UK dental nurses studying for the NEBDN Certificate in oral health education. It is also aimed at hygienists, therapists and dentists who regularly promote and practise oral health and require up-to-date, evidence-based knowledge (including professionals and trainees in developing nations where education has proven to be a cost-effective method of improving oral health). Other professionals such as health visitors, nurses, dieticians and midwives will also find the book invaluable.

Each chapter deals with various aspects of oral health and follows the NEBDN syllabus in a logical order that will also suit other professionals who may 'dip into' relevant chapters of interest. Chapters begin with *learning outcomes*, detailing what the reader should have learnt by the end of the chapter, and conclude with self-assessment exercises. Where the word 'Remember!' appears in the text, it highlights a point particularly relevant to NEBDN students.

After reading this book, the reader should be able to:

- Confidently educate patients about diseases and conditions of the oral cavity, their treatment, management and prevention.
- Set up a preventive dental unit.
- Be aware of the wider context of oral health education and promotion in society.
- Use knowledge gained to help pass the NEBDN Certificate in oral health education.

Acknowledgements

The authors thank the following oral health education tutors for their contributions to this book:

Elizabeth Hill, RDN, Cert. OHE (NEBDN)

Frances Marriott, RDH, MRIPH, Cert Ed.

Alison Grant, RDH, FAETC

Jan Postans, RDN, Cert. OHE (NEBDN), Cert OHE (Notts.), FAETC Cert. Ed.

We are also indebted to:

Alasdair Miller, BDS, FDSRCS (Ed), DGDP, DPDS, South West Regional Postgraduate Dean, for his continued support, advice and writing the foreword;

Professor Anthony Blinkhorn, OBE, BDS, MSc, PhD, FDSRCS (Ed), FIHPE, Professor of Oral Health, University of Manchester, for support and permission to refer to his work;

Janet Goodwin, BA (Hons), RDN, Chairman NEBDN, for answering numerous questions;

Amy Brown, Managing Editor at Wiley-Blackwell, for her invaluable help and advice;

Ruth McIntosh for image design, and Dr Ian Bellamy, Dr Nick Claydon, Dr Susan Hooper, M.A.O. Lewis and Dr Nicola West for granting permission to use photography;

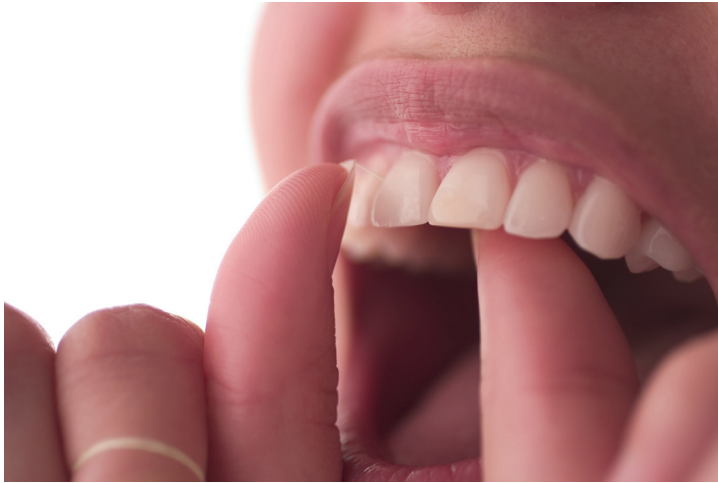Elaine Tilling, MSc, RDH, DMMS, MIPHE, for permission to use some illustrations; and

Ann Dawson for her critical eye in proof checking.

Finally, Ann Felton thanks her co-author Alison Chapman for extensive research and amendments, editor son Simon without whose encouragement and hard work this book would not have been written, Michael Beck for his scholarly advice, daughter Sarah for IT advice and husband Dave for continual patience and moral support.

SECTION 1

STRUCTURE AND FUNCTIONS OF THE ORAL CAVITY



INTRODUCTION

This section comprises a revision chapter, which looks at the oral cavity in some detail. The structure of the tooth and its supporting tissues are examined, plus the eruption dates of primary and secondary dentitions.

The tongue, its functions in maintaining oral health, common conditions associated with it, and the composition and role of saliva in keeping the mouth healthy conclude the chapter.

Chapter 1

The oral cavity in health

LEARNING OUTCOMES

By the end of this chapter you should be able to:

1. Explain, in detail, the structure and function of the tissues and fluid of the oral cavity, including teeth, supporting structures, the tongue and saliva.
2. List primary and secondary dentition eruption dates.

INTRODUCTION

Before oral health educators (OHEs) can deliver dental health messages to patients, and confidently discuss oral care and disease with them, they will need a basic understanding of oral cavity anatomy (Figures 1.1 and 1.2) and how the following structures within it function:

- Teeth (including dentition)
- Periodontium (the supporting structure of the tooth)
- Tongue
- Saliva

MAIN FUNCTIONS OF THE ORAL CAVITY

The oral cavity is uniquely designed to carry out two main functions:

1. Begin the process of digestion. The cavity's hard and soft tissues, lubricated by saliva, are designed to withstand the stresses of:
 - Biting
 - Chewing
 - Swallowing
2. Produce speech.

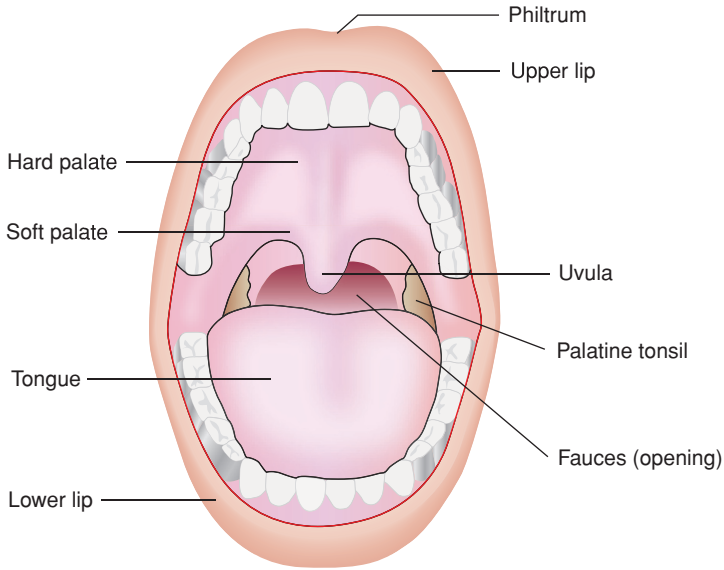


Figure 1.1 Structure of the oral cavity (© Elsevier 2002. Reproduced with permission from Reference 1)

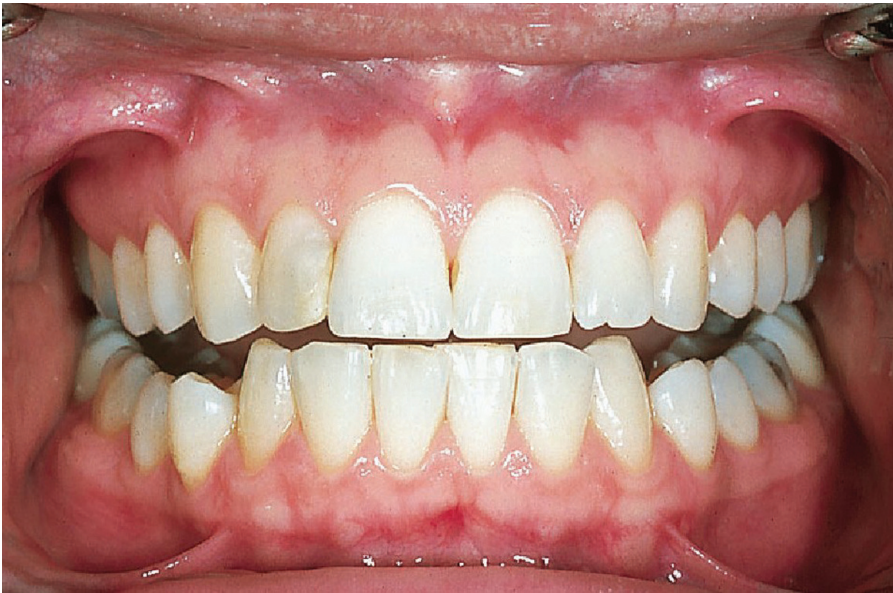

Figure 1.2 A healthy mouth (© Blackwell Publishing 2003. Reproduced with permission from Reference 2)

TEETH

Different types of teeth are designed (*shaped*) to carry out different functions. For example: canines are sharp and pointed for gripping and tearing food, while molars have flatter surfaces for chewing. Tooth form in relation to function is known as *morphology*.

Dental nurses and health care workers may remember from their elementary studies that there are two types of *dentition* (a term used to describe the *type, number* and *arrangement* of natural teeth).

1. Primary (*deciduous*) dentition – consisting of 20 baby teeth
2. Secondary (*permanent*) dentition – consisting of 32 adult teeth

Primary dentition

There are three types of deciduous teeth that make up the primary dentition (Figure 1.3): incisors, canines and molars (first and second). Table 1.1 details their *notation* (the code used by the dental profession to identify teeth), approximate eruption dates and functions.

Secondary dentition

There are four types of permanent teeth that make up the secondary dentition (Figure 1.4): incisors, canines, premolars and molars. Table 1.2 details their notation, approximate eruption dates and functions.

It is important to remember that these eruption dates are only approximate and vary considerably in children and adolescents. The OHE should be prepared to answer questions from parents who are worried that their child's teeth are not erupting at the same age as their friends' teeth. Parents often do not realise, for example, that no teeth fall out to make room for the first permanent molars (sixes), which appear behind the deciduous molars.

Structure of the tooth

Tooth structure (Figure 1.5, see page 10) is complex and comprises several different hard layers which protect a soft, inner pulp (nerves and blood vessels).

Organic and inorganic tooth matter

The words *organic* and *inorganic* are often mentioned in connection with tooth structure. OHEs must know what these terms mean and their percentages in hard tooth structures.

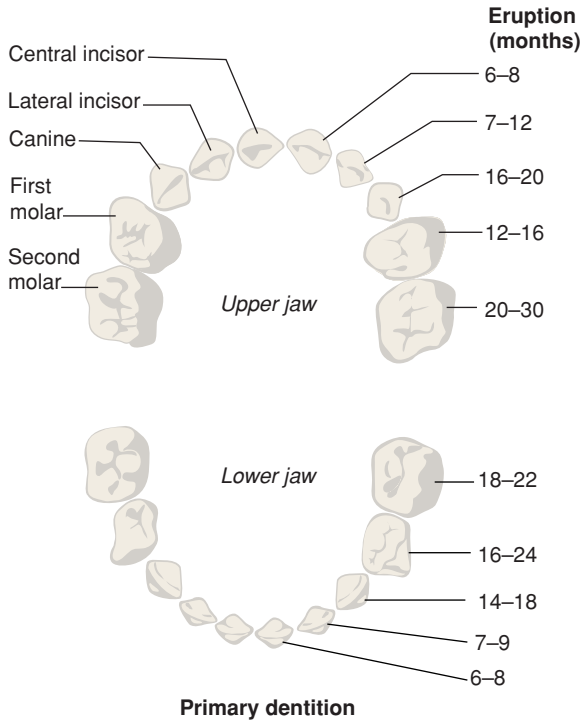


Figure 1.3 Primary dentition (© Elsevier 2002. Reproduced with permission from Reference 1)

Organic means *living* and describes the *matrix* (framework) of water, cells, fibres and proteins which make the tooth a living structure.

Inorganic means *non-living* and describes the mineral content of the tooth which gives it its strength. These minerals are complex calcium salts. (**Remember!** *calcium hydroxyapatite*.)

Table 1.3 shows the percentages of organic and inorganic matter in hard tooth structures.

Table 1.1 Primary dentition (notation, approximate eruption dates and functions)

Tooth	Notation	Approximate eruption date	Function
Incisors	(a & b)	6-12 months (usually lowers first)	Biting
First molars	(d)	12-24 months	Chewing
Canines	(c)	14-20 months	Tearing
Second molars	(e)	18-30 months	Chewing

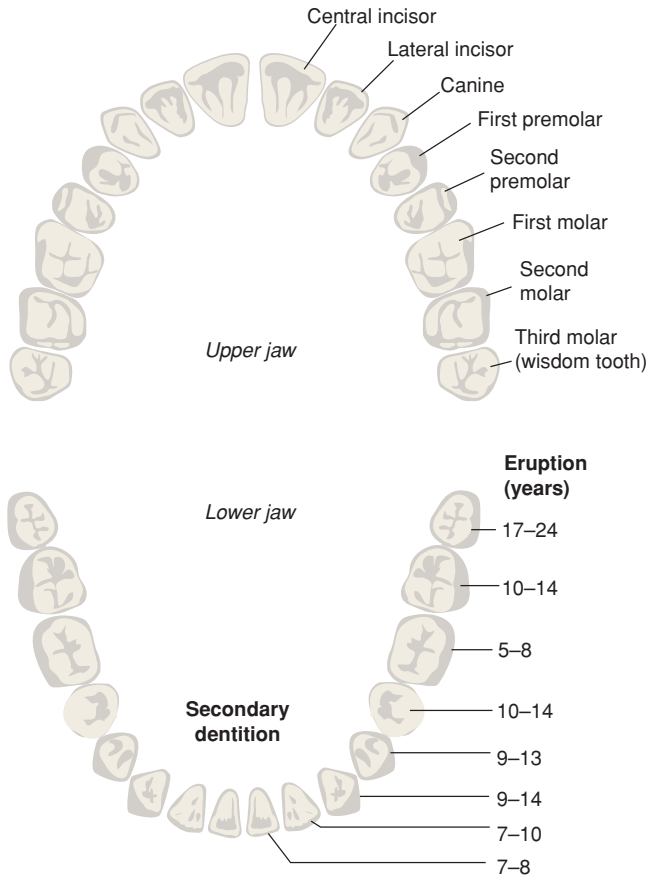


Figure 1.4 Secondary dentition (© Elsevier 2002. Reproduced with permission from Reference 1)

Table 1.2 Secondary dentition: notation, approximate eruption dates and functions

Tooth	Notation	Approximate eruption date	Function
First molars	(6)	5–8 years	Chewing
Lower central incisors	(1)	7–8 years	Biting
Upper central incisors	(1)	7–8 years	Biting
Lower lateral incisors	(2)	7–10 years	Biting
Upper lateral incisors	(2)	7–10 years	Biting
Lower canines	(3)	9–14 years	Tearing
First premolars	(4)	9–13 years	Chewing
Second premolars	(5)	10–14 years	Chewing
Upper canines	(3)	9–14 years	Tearing
Second molars	(7)	10–14 years	Chewing
Third molars	(8)	17–24 years	Chewing

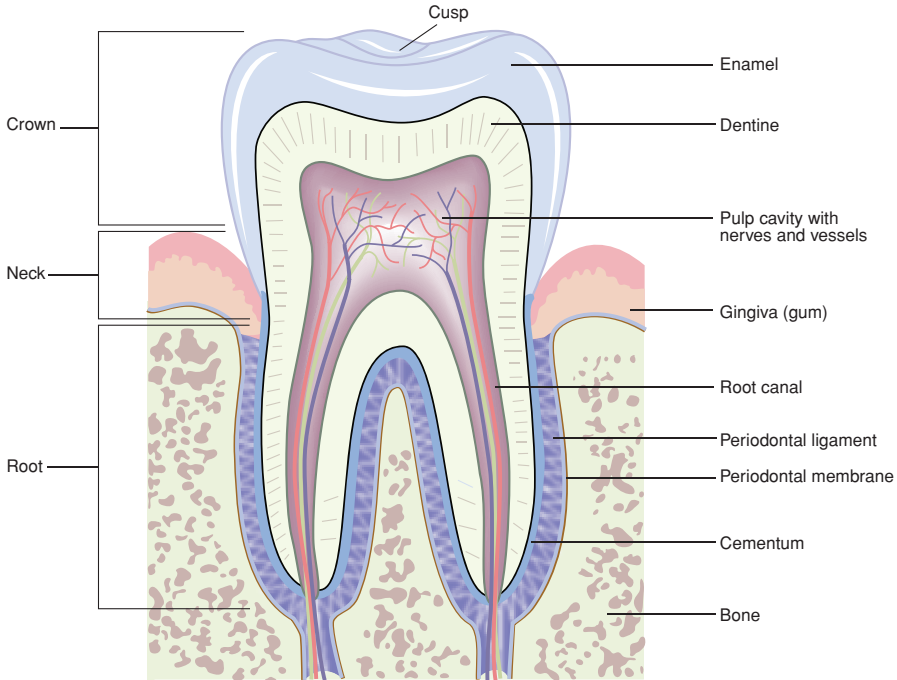


Figure 1.5 Structure of the tooth (© Elsevier 2002. Reproduced with permission from Reference 1)

It is also important that the OHE knows basic details about these three hard tooth substances, and also pulp.

Enamel

Enamel is made up of prisms (*crystals of hydroxyapatite*) arranged vertically in a wavy pattern, which give it great strength. The prisms, which resemble *fish-scales*, are supported by a matrix of organic material including keratinised (*horny*) cells and can be seen under an electronic microscope.

Table 1.3 Percentages of organic and inorganic matter in hard tooth structures

Structure	Inorganic	Organic
Enamel	96%	4%
Dentine	70%	30%
Cementum	45%	55%

Properties of enamel

Enamel is:

- The hardest substance in the human body (of similar hardness to diamond).
- Brittle – it fractures when the underlying dentine is weakened by decay (*caries*).
- Insensitive to stimuli (e.g. hot, cold and sweet substances).
- Darkens slightly with age – as secondary dentine is laid down and stains from proteins in the diet, tannin-rich food and drinks, and smoking are absorbed.

Enamel is also subject to four types of wear and tear. The OHE needs to be aware of these and be able to differentiate between them:

1. *Erosion* – usually seen on *palatal* and *lingual* (next to palate and tongue) surfaces.
2. *Abrasion* – usually seen on *cervical* (outer neck of tooth) surfaces.
3. *Attrition* – natural wear often seen on *occlusal* (biting) surfaces.
4. *Abfraction* – *notching* of the enamel close to, or beneath the *gingival margin* (gum line).

Dentine

Dentine constitutes the main bulk of the tooth and consists of millions of microscopic tubules (fine tubes), running in a curved pattern from the pulp to the enamel on the crown and the cementum on the root.

Properties of dentine

Dentine is:

- Softer than enamel, but harder than cementum and bone.
- Light yellow in colour.
- Sensitive to stimuli (e.g. hot, cold and sweet substances). Reasons for this sensitivity are not fully understood, but it usually lessens with age.
- Changes throughout life. After a tooth is fully developed, more dentine is laid down (at a slower rate than before), and is known as *secondary dentine*.

Cementum

Cementum covers the surface of the root and provides an attachment for the *periodontal ligament*. The fibres of the ligament are fixed in the cementum and in the *alveolar bone* (see supporting structures of the tooth).

Properties of cementum

Cementum is:

- Of similar hardness to bone.
- Thickens throughout life to counteract wear and tear caused by chewing and movement.

Pulp

Pulp is a soft living tissue within the pulp chamber and root canal of the tooth. It consists of blood vessels, nerves, fibres and cells. The pulp chamber shrinks with age as more secondary dentine is laid down, so that the tooth becomes less vulnerable to damage.

Supporting structures of the tooth

The *periodontium* (Figure 1.6) is the collective name for the supporting structures of the tooth. It comprises:

- Periodontal ligament
- Cementum (part of the tooth and supporting structure)
- Alveolar bone (it consists of two components: the alveolar bone proper and the alveolar process)
- Gingivae (gums)

The periodontal ligament

The periodontal ligament (*or membrane*) is a connective tissue which holds the tooth in place in the alveolar bone (assisted by cementum). The ligament is between 0.1 and 0.3 mm wide⁴ and contains blood vessels, nerves, cells and *collagen fibres*.

The collagen fibres attach the tooth to the alveolar bone and run in different directions, which provide strength and flexibility and act as a *shock absorber* for the tooth; teeth need to move slightly in their sockets in order to withstand the pressures of *mastication* (chewing). Imagine what it would feel like to bite hard with teeth rigidly cemented into bone.

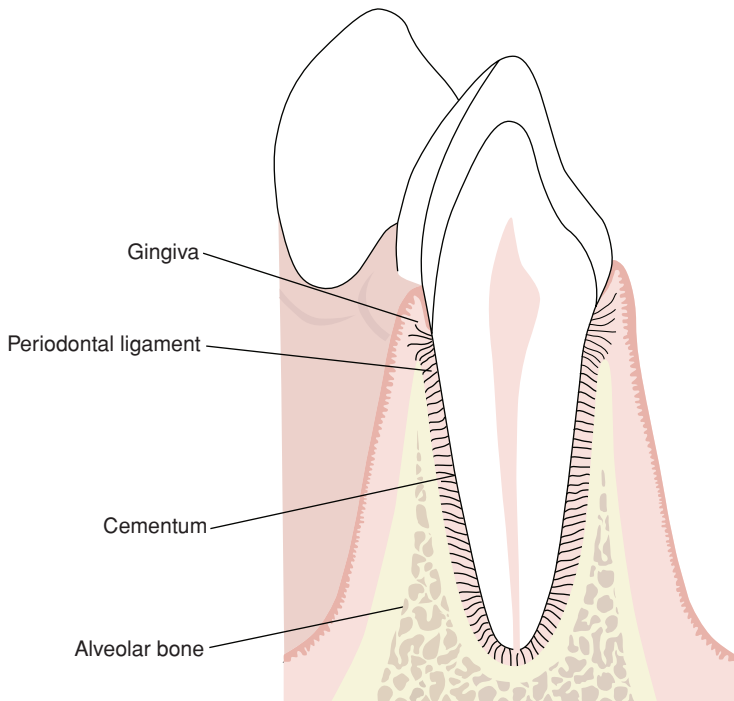


Figure 1.6 The periodontium (© Blackwell Publishing 2003. Reproduced with permission from Reference 3)

Cementum (see tooth structure, page 12)

Alveolar bone (also known as the alveolar ridge)

Alveolar bones are *horseshoe-shaped* projections of the *maxilla* (upper jaw) and *mandible* (lower jaw). They provide an attachment for the fibres of the periodontal ligament and sockets for the teeth.

Gingivae

The *gingivae* (gums) consist of pink-coloured mucous membranes and underlying fibrous tissue, covering the alveolar bone.

Gingivae are divided into four sections:

1. *Attached gingiva* (Figure 1.7) – a firm, pale pink, stippled gum tightly attached to the underlying alveolar bone. It is *keratinised* (*hard and firm like horn*) to withstand the friction of chewing. Its orange-peel appearance (known as *stippling*) comes from tightly packed bundles of collagen fibres that attach it to the bone. Loss of stippling is one of the signs of gingivitis.

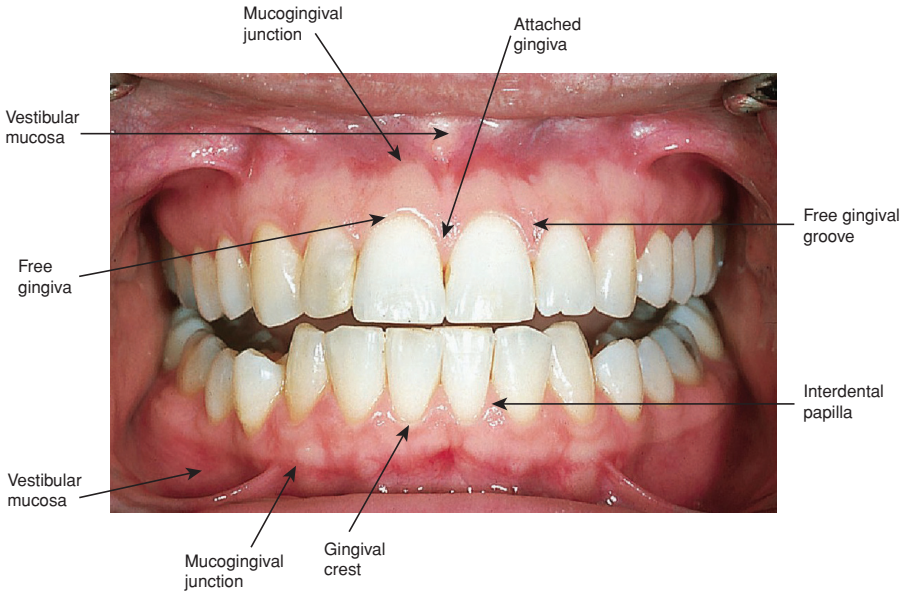


Figure 1.7 Free and attached gingiva (© Blackwell Publishing 2003. Reproduced with permission from Reference 2)

2. *Free gingiva* (Figure 1.7) – where the gum meets the tooth. It is less tightly attached and unstippled. It is also keratinised and contoured to form little points of gum between teeth – the *interdental papillae*. The indentation between attached and free gingiva is called the *free gingival groove*.
3. *Gingival crest* – the edge of the gum and interdental papillae, bordering the tooth. Behind the crest is the *gingival sulcus* (or crevice), which is not more than 2 mm in depth⁴. This base of the crevice is lined with a layer of cells called the *junctional epithelium*, which attaches the gum to the tooth. When this epithelium breaks down, in disease, periodontal ligament fibres are exposed to bacterial enzymes and toxins. As these fibres break down, a *periodontal pocket* is formed.
4. *Mucogingival junction* – the meeting point of the keratinised attached gingiva and the non-keratinised *vestibular mucosa* (soft, dark red tissue which lines the inside of lips, cheeks and the floor of the mouth).

THE TONGUE AND THE FLOOR OF THE MOUTH

The tongue is a muscular, mobile organ which lies in the floor of the mouth, and comprises four surfaces:

1. *Dorsal* (upper) surface – covered by a thick, keratinised epithelium to withstand chewing, and a large number of projections called *papillae*. These papillae contain taste buds. The dorsal surface is divided into two sections:
 - *Anterior* (front) two-thirds (against the palate)
 - *Posterior* (back) third (towards the pharynx)
2. *Ventral* (under) surface – covered by a thin mucous membrane. In the middle of the front section, the mucosa is divided into a sharp fold, which joins the tip of the tongue to the floor of the mouth (the *lingual fraenum*).
3. *Tip* – the pointed front, which can be protruded or moved around the mouth by muscular action. For a baby, the tip of the tongue is an important sensory organ, which explores and identifies objects.
4. *Root* – the deep attachment of the tongue, which forms the anterior surface of the pharynx.

Muscles of the tongue

There are two groups of tongue muscles:

1. *Intrinsic* (inside) – which can alter its shape.
2. *Extrinsic* (outside) – which move the tongue and help alter its shape.

Functions of the tongue

The main functions of the tongue are taste, mastication, *deglutition* (swallowing), speech, cleansing and protection.

Taste

The tongue (and other parts of the oral cavity) is covered with taste buds that allow us to distinguish between sweet, sour, salt and savoury tastes. An adult has approximately 9000 taste buds⁴, which are mainly situated on the upper surface of the tongue (there are also some on the palate and even on the throat).

Mastication

The tongue helps to pass a soft mass of chewed food (*bolus*) along its dorsal surface and presses it against the hard palate.

Deglutition

The tongue helps pass the bolus towards the entrance of the oesophagus.

Speech

Tongue movement plays a major part in the production of different sounds.

Natural cleansing

Tongue muscles allow for tremendous movement, and the tongue can help to remove food particles from all areas of the (mouth mainly using the *tip*).

Protection

The tongue moves saliva (which has an antibacterial property) around the oral cavity.

Conditions affecting the tongue

The following conditions affect the tongue:

- *Glossitis* (inflammation of the tongue).
- Soreness of the tongue, which may be due to a variety of reasons, including anaemia, vitamin B deficiency and hormonal imbalance.
- *Black hairy tongue* – due to overgrowth of tongue papillae, stained by *chromogenic bacteria* or medication (e.g. chlorhexidine). Looks alarming, but is not serious.
- *Geographic tongue* – smooth ‘maplike’ irregular areas on the dorsal surface, which come and go. Harmless, but sometimes sore (often runs in families)⁵.

Piercing of the tongue can also cause problems and the OHE should be able to advise patients on this matter. Tongue cleansing is also back in vogue, due to an increased awareness of halitosis⁶, and tongue cleansers (e.g. TePe[®]) can help with this condition.

The floor of the mouth

The OHE need only know that the floor of the mouth consists of a muscle called the *mylohyoid* and associated structures.

SALIVA

Incredible stuff, saliva! It is often taken for granted, and patients only realise how vital it is to the well-being of the oral cavity and the whole body, when its flow is diminished.

Saliva is secreted by three major and numerous minor salivary glands. The minor glands are found in the lining of the oral cavity; on the inside of the lips, the cheeks, the palate and even the pharynx.

Major salivary glands

The three major salivary glands (Figure 1.8):

1. *Parotid gland* – situated in front of the ear. It is the largest salivary gland and produces 25% of the total volume of saliva⁴. It produces *serous* (watery) saliva, which is transported into the oral cavity by the parotid duct which opens above the upper molars. The parotid gland swells during mumps (*parotitis*).

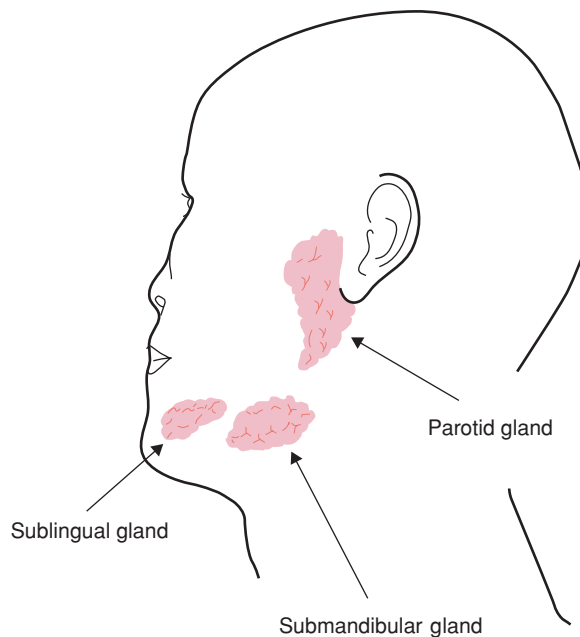


Figure 1.8 Major salivary glands (© Fejerskov & Kidd. Reproduced with permission from Reference 7)

2. *Submandibular gland* – situated beneath the *mylohyoid* muscle towards the base of the mandible. It is the middle of the three glands, in both size and position, and can be said to have a ‘middle role’, producing a mixture of serous and mucous saliva. It produces around 70% of total saliva⁴ and opens via the submandibular duct on the floor of the mouth.

When dental nurses assist the dentist, they may occasionally notice a small ‘fountain’ as the saliva appears from this duct (which can also happen when yawning).

3. *Sublingual gland* – is also situated beneath the anterior floor of the mouth under the front of the tongue. It produces 5% of total saliva⁴, mainly in the form of mucous which drains through numerous small ducts on the ridge of the *sublingual fold* (the section of fraenum beneath the anterior of tongue).

Composition of saliva

Saliva is made up of 99.5% water and 0.5% dissolved substances⁴. Dissolved substances include:

- Proteins – a number of different types, collectively known as *mucin*. They are also known as *glycoproteins* and provide the *substrate* (food) for plaque bacteria. They give saliva its viscosity (stickiness) and are the origin of the *salivary pellicle* (the sticky film which forms on teeth within minutes of cleaning).
- Enzymes – there are many but the OHE need only remember the main ones: *salivary amylase (ptyalin)* and *lysozyme*.
- *Serum proteins* – *albumin* and *globulin* (saliva is formed from *serum*, the watery basis of blood).
- Waste products – urea and uric acid.
- Gases – oxygen, nitrogen and carbon dioxide in solution. The latter vaporises when it enters the mouth and is given off as a gas.
- Inorganic ions – including sodium, sulphate, potassium, calcium, phosphate and chloride. The important ones to remember are calcium and phosphate ions which are concerned with *remineralisation* of the teeth after an acid attack and the development of calculus.